



35th ISP national conference  
Oct 27 - 30 @ Bengaluru  
[www.perio.co.in](http://www.perio.co.in)

# Journal of the Society of Periodontists and Implantologists of Kerala



# JSPIK

Volume 4 - Issue 1 - August 2010

[www.spik.in](http://www.spik.in)



## Contents

President's Message	2
Editor Speak	3
Secretary's Message	4
<b>Gingival depigmentation by lasers – a case series</b> Presanthila Janam, Neeta Parate, Suchitra A., Remya Mohan	5
<b>Osteoimmunology- a new dimension to Bone resorption in periodontal disease</b> Rosamma Joseph Vadakkekuttical, Arun R. Sameera G. Nath	8
<b>Serum folic acid level in epileptic patients with phenytoin induced gingival enlargement - a correlative study</b> Mini Jose	11
<b>Comparative evaluation of Myeloperoxidase levels among systemically healthy individuals and patients with type 2 Diabetes Mellitus, with chronic periodontitis – A biochemical study</b> Amitha Ramesh, Biju Thomas, Aparna Anand, Suchetha Kumari	15
<b>Gingival depigmentation with diode laser - A case report</b> Seba Abraham, Prakash P., Ambili R., Nisha, Mekha Grace Varghese, Azza Haneefa	18
<b>Host modulation</b> P. Jayachandran	21
<b>Probiotics in the management of periodontal diseases</b> Seema Jayakrishnan, Prakash Prabhakaran, Shamnad C.A., Smrithi Varma, Anitha S.	25
<b>Free gingival graft- a novel technique in gingival augmentation–A case report</b> Smrithi Varma, Ramakrishnan T., Prakash Prabhakaran, Seema Jayakrishnan	28
<b>Wonders of non-surgical one stage full mouth disinfection therapy &amp; gingival depigmentation by scalpel method – a case report</b> Samarjeet J Pattnaik, Mohan Valiathan, S.C. Chandrasekaran	32
<b>Correlation between Obesity, Diabetes Mellitus and Periodontal Disease in Adults- a clinical and biochemical study</b> Biju Thomas, Sunaina Shetty Y., Suchetha Kumari	35
<b>Comparative evaluation of myeloperoxidase levels in healthy individuals and subjects with chronic periodontitis-a biochemical study</b> Biju Thomas, Mranali Alva, Amitha Ramesh, Suchetha Kumari	39



Dr. Biju Thomas

## *President's message*

**SPIK** is into the 4th year of its existence and it is heartening to note that our organization is growing in strength & stature. I wish to thank all the 3 past presidents and our past dynamic secretary Dr. Santhosh Sreedhar, who have steered this organization over the last 3 years.

JSPIK offers all of us a medium to publish original Research articles, Case reports, Review articles etc which will help to showcase our knowledge and also enrich our fellow colleagues. This year we have increased the frequency of the journal from bi annually to thrice a year. I request all the members to contribute to the journal so that the scientific content can be enriched, and as expressed by the members in the last A G M, we should make efforts to get our journal indexed.

TO enable our Life & Associate members to make scientific presentations, we intend to have a Mid Term conference, sometime in December or January. I request all the members to make use of this opportunity and come forward with scientific presentations.

In the new 5 year BDS course Periodontology has been shifted to the 4th year and Community Dentistry has been upgraded to the 5th year. This is something which has disturbed all of us. I understand that this has been represented to the Dental Council of India and they have promised to look into it. Also Implantology which was an integral part of our speciality has been taken away from us. Let's hope that we are reverted back to the 5th year and the importance of our speciality is understood by the statutory bodies concerned.

I congratulate the new office bearers led by our young and energetic secretary Dr Baiju for coming forward to shoulder the responsibility of taking this organization forward. A special word of appreciation for our editor Dr. Prakash who is successfully bringing out 2 publications - a newsletter and a journal. So dear members, I request all of you to attend regularly all the programmes of SPIK and lets all get together to build a strong & vibrant SPIK.

**Dr. Biju Thomas**  
President, SPIK



**SOCIETY OF PERIODONTISTS AND  
IMPLANTOLOGISTS OF KERALA**

**OFFICE BEARERS**

*President*  
**Biju Thomas**

*Secretary*  
**Baiju R.M.**

*Immediate Past President*  
**Raju Kurian Ninan**

*President Elect*  
**Santhosh Sreedhar**

*Vice Presidents*  
**Siby T. Chennankara**  
**Padmakumar T. P**

*Joint Secretary*  
**Jayan Jacob Mathew**

*Treasurer*  
**Jose Richard**

*Editor*  
**Prakash Prabhakaran**  
*Perio Health Care Convenor*  
**Harikumar**

*Scientific Programme Convenor*  
**Jose Paul**

*Web site Convenor*  
**Arun Sadasivan**

**EXECUTIVE COMMITTEE MEMBERS**

**C. K. Ashokan**  
**Presanthila Janam**  
**Mini Jose**

**Anto Joseph**  
**Augustine Daniel**  
**Sabu Kurian**  
**Biniraj K.R.**

**Majo Ambooken**  
**Kiran Joseph**  
**Sajil John**  
**Fermi E.D**  
**Tony P. Paul**

**ADVISORS**

**Thomas Thelly**  
**B.R.R. Varma**  
**Rezy T. Cheru**  
**K.V. Sosa**  
**Meherunniza Bai**  
**Kunhamma Sebastian**  
**K.Nandakumar**

**EDITORIAL BOARD**

**B.R.R. Varma**  
**K. Nandakumar**  
**Presanthila Janam**  
**Rosamma Joseph**  
**Santosh Sreedhar**

**REVIEW PANEL**

**Anil M.**  
**Mini Jose**  
**Siby T. Chennankara**  
**Arun Sadasivan**  
**Seema Jayakrishnan**



Dr. Prakash Prabhakaran

## EDITOR SPEAK

Welcome to the August issue of JSPIK !

As I take over as editor of JSPIK my main goal is to get it indexed at the earliest. The other priorities being improving the quality of papers published and to regularize the issues ie 3 issues per year. JSPIK has always had a range of topics in Periodontology since its inception, and I believe this issue continues that tradition. We at SPIK are already planning 2 future editions viz December and March. My job as editor is to make our journal as useful and informative to you as possible. Lots of work need to be done and I will strive hard with my co-office bearers to attract and publish outstanding papers in Periodontology to bring it on par with international journals.

Lastly, please don't hesitate to contact me with your suggestions or thoughts you may have. I really do want to hear them, so I can make our journal even more attractive and useful down the road. Most importantly, if you have an article to publish I would be delighted to hear from you.

Till I hear from you,

Dr. Prakash Prabhakaran  
prakashpmds@gmail.com



Dr. Baiju R.M.

## *Secretary's Message*

Our journal is celebrating the fourth year of continuous publishing. Over these years the journal has come a long way with regard to improvements in the quality of content and lay out. This is the age of information explosion. Any data that you require is readily available by just the click of the mouse. But still the number of scientific journals being brought out is on the rise in every part of the world. In other words as the information becomes more and more accessible the significance of printed journal only advances. There is a renewed interest among dental professionals in writing and publishing scientific articles, thanks to the recent Dental council of India directive. As volumes swell one has to be critical in assessing the righteousness of the content, as well as genuinity of the research protocol the article puts forward. We at SPIK strive to showcase the best from what we receive from the authors.

*Perio is thrilling.*

**Dr. Baiju R.M.**

# Gingival depigmentation by lasers – a case series

\* Presanthila Janam, \*\* Neeta Parate, \*\* Suchitra A., \*\* Remya Mohan

## Abstract

The complaint of black gums is common particularly in patients having a very high smile line and possess esthetic problems for them. The degree of gingival pigmentation depends on melanoblastic activity. Various surgical and non-surgical procedures have been reported for gingival depigmentation including bur abrasion, scraping, partial thickness flap, cryotherapy, electrosurgery, gingivectomy, gingivectomy with free gingival autografting, chemical agents such as 90% phenol and 95% alcohol and lasers. Recently treatment with lasers has been recognized as the most effective and reliable technique having many advantages as compared to other conventional treatment modalities. It provides a bloodless and painless surgery.

Presented herewith, is a case series of a three young patients treated for gingival pigmentation with lasers.

## Introduction

Gingival health and appearance are essential components of an attractive smile. Gingival pigmentation results from melanin granules, which are produced by melanoblasts. The degree of pigmentation depends on melanoblastic activity. Although melanin pigmentation of the gingiva is completely benign and does not present a medical problem, complaints of 'black gums' are common particularly in patients having a very high smile line (gummy smile).

Oral melanin pigmentation is well documented in the literature and is considered to be multifactorial, whether physiological/pathological and can be caused by a variety of local and/or systemic factors<sup>1</sup> including genetic, tobacco use, prolonged administration of certain drugs especially antimalarial agents and tricyclic antidepressants endocrine disturbance, Albright's syndrome, malignant melanoma, Peutz-Jeghers syndrome, trauma, hemochromatosis, chronic pulmonary disease, and racial pigmentation<sup>2</sup>. This pigmentation may be seen across all the races<sup>7</sup> and at any age<sup>8</sup> and it is without gender predilection<sup>9</sup>. High levels of oral melanin pigmentation are normally observed in individuals of African, East Asian, or Hispanic ethnicity.

It is generally agreed that pigmented areas are present only when melanin granules synthesized by melanocytes are transferred to the keratinocytes. This close relationship between melanocytes and keratinocytes was labeled by Fitzpatrick and Breathnach (1963) as the epidermal-melanin unit<sup>6</sup>

Demand for cosmetic therapy of gingival melanin pigmentation is common. Gingival depigmentation has been

carried out using various non-surgical and surgical procedures. Different treatment modalities which have been reported include bur abrasion, scraping, partial thickness flap, cryotherapy, electrosurgery, gingivectomy, gingivectomy with free gingival autografting, chemical agents such as 90% phenol and 95% alcohol and lasers. Recently, laser ablation has been recognized as a most effective, pleasant and reliable technique.

This article presents a case series of gingival depigmentation carried out by a laser.

## Case Reports

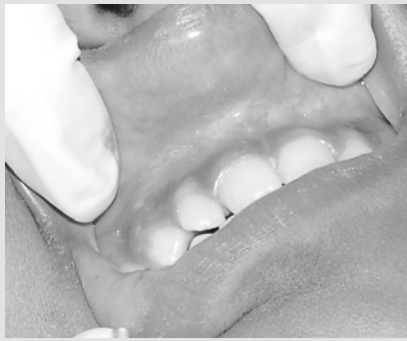### Case 1

A 13 yr old female reported to Govt. Dental College, Trivandrum, with the chief complaint of irregular positioning of teeth. She and her mother were very conscious about her appearance. They wanted her teeth to be arranged properly and were referred to the orthodontia dept. initially, from where she was referred to the dept. of periodontics for oral prophylaxis before starting with the orthodontic treatment.

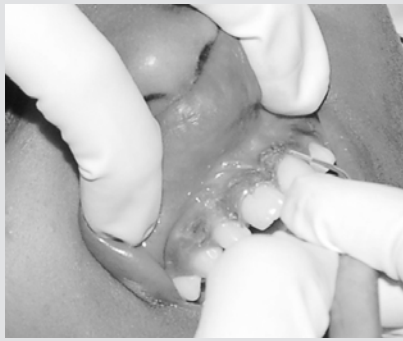On examination, mild crowding of her lower anterior teeth was seen. Also calculus deposits were present. Her gingiva appeared to be healthy with brownish black pigmentation in the marginal and interdental gingiva. Since, they were very conscious about her esthetic appearance, they told about the black pigmentation of the gingiva and requested to correct it, if possible. Accordingly, phase I therapy including thorough scaling and root planning was performed and a routine blood examination of the patient was done which revealed all values within the normal limits.

\* Professor and Head of Department, \*\* PG Students, Department of Periodontics, Government Dental College, Trivandrum

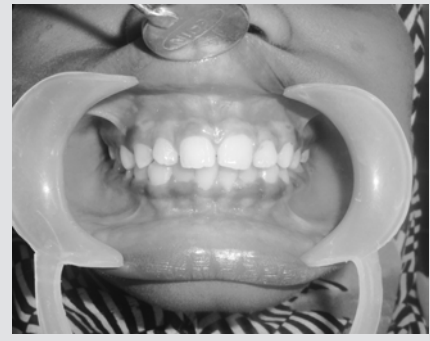



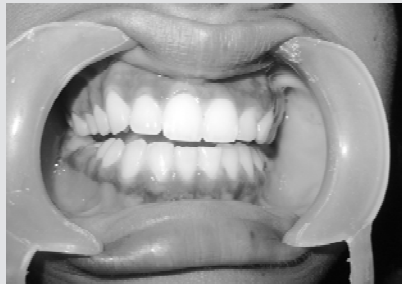Case 1 Pre-operative



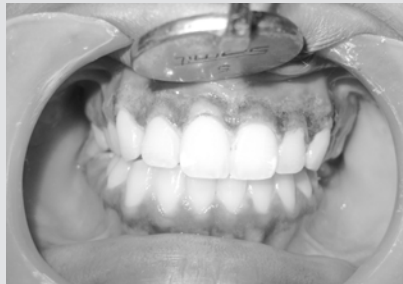Case 1 Intra-operative



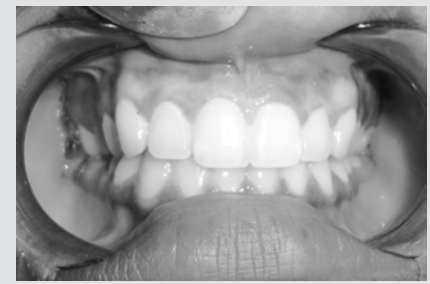Case 1 Post operative



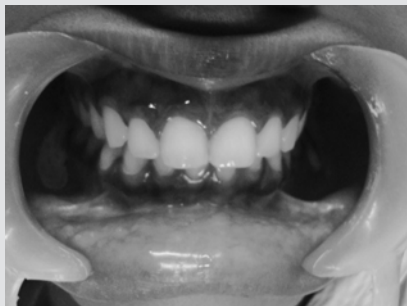Case 2 Pre-operative



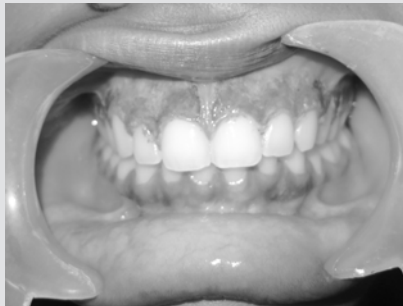Case 2 Intra-operative



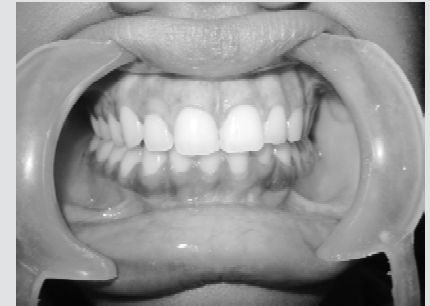Case 2 Post operative



Case 3 Pre-operative



Case 3 Intra-operative



Case 3 Post operative

After two weeks, patient was posted for gingival depigmentation with lasers. It was planned to do the procedure in the upper anterior region only, since, the lower anterior region was not visible during talking, smiling, etc.

Procedure started with the application of topical anaesthesia (Lidocaine Topical Aerosol - LOX 10 % spray). Semiconductor diode laser at 2.50W power and pulsed mode was used. Depigmentation was performed with short light paint brush strokes in a horizontal direction to remove the epithelial lining. Neither bleeding nor pain was experienced by the patient during the procedure. Following the procedure, no periodontal pack was given and no antibiotics administered.

Patient was called the 3rd day, when progressive healing of the surgical site was seen. Patient did not report of any pain or discomfort after the procedure. At 1 week review appointment, complete healing of wound was seen. Healing was uneventful.

At present i.e. after two months, the pigmentation has not recurred. Patient is still on follow-up visits.

### Cases 2 and 3

Two patients – one 21 years old and another 19 years old - reported to Government Dental College, Trivandrum with the chief complaint of black coloured gums and were further referred to the department of Periodontics. On examination, their gingiva appeared to be healthy with brownish black pigmentation.

Similar treatment as in case 1 was undertaken in these patients.

1 month post-operative views of both these patients showed no recurrence of gingival pigmentation. Patients are still on follow-up.

### Discussion

The word laser is an acronym for light amplification by stimulated emission of radiation. Maiman TH (1960) developed the first working laser. The first application of a laser to dental tissue was reported by Goldman et al (1964) and Stern RH and Sognnaes RF (1972) describing the effects

of the ruby laser on enamel and dentin.

Clinical lasers are of two types: "soft" and "hard" lasers. Soft lasers are claimed to aid healing and to reduce inflammation and pain. Its applications include frenectomies, ablation of lesions, incisional and excisional biopsies, gingivectomies, gingivoplasties, de-epithelization, soft tissue tuberosity reductions, operculum removal, coagulation of graft donor sites, and certain crown lengthening procedures. Surgical hard lasers, however, can cut both hard and soft tissues. Currently, numerous laser systems; both soft and hard lasers are available for dental use, like Neodymium-doped: Yttrium-Aluminium-Garnet (Nd:YAG)<sup>3</sup> carbon dioxide (CO<sub>2</sub>)<sup>5</sup>, semiconductor diode lasers<sup>4</sup>, Erbium doped: Yttrium-Aluminium-Garnet (Er: YAG) laser.

There are many advantages of lasers over surgical procedures. According to Wigdor et al (1995), these include-

1. Dry and bloodless surgery
2. Instant sterilization of the surgical site
3. Reduced bacteremia
4. Reduced mechanical trauma
5. Minimal postoperative swelling and scarring
6. Minimal postoperative pain

All these above mentioned advantages are evidently experienced in the above case. During procedure, there was no bleeding, which is almost always present when surgical approaches like bur abrasion, scraping, partial thickness flap or gingivectomy are used. Also, postoperatively, no pain was experienced by the patient and no swelling or any other signs of infection were noticed, whereas other alternative procedures have to be accompanied by administration of antibiotics and analgesics to minimize postoperative infection and pain. Especially, children and adolescents are among the best candidates for laser use because they are particularly bothered by pain, bleeding, and extra postoperative office visits.

Lasers can be used for patients to reduce anxiety or fear of drill. It provides a 'needle-free' approach or 'no anaesthesia' dentistry. Also, laser dentistry requires less chair-side time compared with more traditional treatments and hence results in more patient co-operation and more efficient dental practice. There is increased coagulation and a necrotic slough is formed over the surface of soft tissue after treating with lasers. There is no need of sutures and a faster and more comfortable healing is seen. Thus, it provides faster and better treatment of gum disease.

Therapeutic lasers have been used for more than 30 years. There are no reports of patients being harmed by therapeutic lasers. The risk of eye injury is minimal but must be considered, especially for high-output lasers in the invisible range. Diode laser light is generally divergent; however, if

the light is collimated, the risk of eye injury increases significantly. Protective goggles, specific for the wavelength, must be used for the patient and the therapist.

## Conclusion

For many intraoral soft tissue surgical procedures, the laser is a viable alternative to the scalpel. In the modern dental practice using laser technology, procedures can be accomplished with less invasive methods, a more relaxed appointment, and less postoperative discomfort. These benefits can be accomplished routinely and predictably with laser technology (Hall RR, 1971).

Laser dental care is possible in all of the disciplines of dentistry. The public has an expectation that their dentist should be up to date and wants the most modern, advanced care possible. The future of lasers in dentistry is promising, and new applications and procedures are being developed. Dentists and their staffs can successfully integrate the use of lasers into the everyday practice of dentistry.

The public's positive view on lasers and the dental profession's use of lasers create value for laser dentistry that drives modern laser practice management.

## References

1. Dummett CO. A classification of oral pigmentation. *Mil Med* 1962; 127:839- 840.
2. Leston JM, Santos AA, Varela-Centelles PI, Garcia JV, Romero MA, Villamor LP. Oral mucosa: Variations from normalcy, Part II. *Cutis* 2002; 69(3):215-217.
3. Atsawasuwan P, Greethong K, Nimmanon V. Treatment of gingival hyperpigmentation for esthetic purposes by Nd:YAG laser: Report of 4 cases. *J Periodontol* 2000; 71(2):315-321.
4. Yousuf A, Hossain M, Nakamura Y, Yamada Y, Kinoshita J, Matsumoto K. Removal of gingival melanin pigmentation with the semiconductor diode laser: A case report. *J Clin Laser Med Surg* 2000; 18(5):263-266.
5. Nakamura Y, Hossain M, Hirayama K, Matsumoto K. A clinical study on the removal of gingival melanin pigmentation with the CO<sub>2</sub> laser. *Lasers Surg Med* 1999; 25(2):140-147.
6. Kon S, Bergamaschi O, Dome AI, Ruben MP. Melanin Repigmentation after Gingivectomy: A 5-Year Clinical and Transmission Electron Microscopic Study in Humans. *Int J. Periodont RestDent*, 13: 85-92, 1993.
7. Dummett CO oral pigmentation. In: Dummett CO, editor. *First symposium on oral pigmentation*. *JPeriodonto*1, 31: 356-60, 1960.
8. Page LR, Coro RE, Crawford BE, Giansanti JS, Weathers DR. The oral melanotic macule. *Oral Surg Oral Med Oral Pathol*, 44:219-26, 1977.
9. Trelles MA, Verkrusysse W, Segui JM, Udaeta A. Treatment of melanotic spots in the gingiva by argon laser. *J Oral Maxillofac Surg*, 51:759-61, 1993.

*For Membership in SPIK*

log on to [www.spik.in](http://www.spik.in)



# Osteoimmunology- a new dimension to Bone resorption in periodontal disease

\* Rosamma Joseph Vadakkekuttikal, \*\* Arun R. \*\*\* Sameera G. Nath

## ABSTRACT

**Objectives:** to estimate the levels of salivary myeloperoxidase in systemically healthy individuals and those with type 2 diabetes mellitus having chronic periodontitis.

**Study design:** Single centre case –control study

**Setting:** Unstimulated saliva sample obtained

**Sample:** Sample size consisted of forty patients between the ages thirty five to sixty five years. Categorization was based on random blood glucose levels whereby Group one consisted of 20 patients with random blood glucose levels below 126mg/dl and Group two consisted of 20 patients with random blood glucose levels above 126mg/dl and both groups with chronic periodontitis.

**Method:** Estimation of myeloperoxidase levels using 4-aminoantipyrene as the hydrogen donor method and subjected to spectrophotometric analysis.

**Results:** The mean myeloperoxidase levels in group one and group two was found to be 0.08 and 0.11 respectively. The myeloperoxidase levels are lower in group one as compared to group two which is statistically significant with  $P < 0.05$

### Conclusions

1) Myeloperoxidase level is increased in the saliva of patients with type 2 DM as compared with systemically healthy individuals of both the groups showing chronic periodontitis.

2) Myeloperoxidase may be considered for use as a potential biomarker of periodontal disease activity.

### Key words:

Myeloperoxidase, Type 2 Diabetes Mellitus, Saliva, chronic periodontitis

## Introduction

Periodontitis is a chronic inflammatory disease which serves as a reservoir of gram negative, anaerobic organisms, lipopolysaccharides and inflammatory mediators. These host-bacterial interactions produce destruction of the supporting structures. Several mechanisms may participate in this immuno inflammatory reaction including those induced by oral organisms, and those associated with host response factors.<sup>1</sup>

Microorganisms evade the host defense mechanism; deregulate the inflammatory interactions which consist of neutrophils, monocytes/macrophages, dendritic cells, T cells and immunoglobulins. The presence of innate phagocytes such as neutrophils, monocytes/macrophages, which are capable of fighting and killing the invading pathogens in the periodontium, is often short lived.<sup>2</sup> This render an incomplete removal of biofilm and the infected tissues are overwhelmed

by the persistent periopathogen and the persistent chronic inflammation. Amplification of this initially localized response results in the release of an array of cytokines and other mediators and propagation of inflammation through the gingival tissues. The failure to encapsulate this "inflammatory front"<sup>3</sup> within gingival tissue results in expansion of the response adjacent to alveolar bone leading to significant tissue destruction involves alveolar bone resorption and loss of collagen and extracellular matrix that is the cardinal sign of Periodontal Disease(PD).<sup>3</sup>

The recognition that periodontitis involves an immuno inflammatory component as well as altered bone metabolism has provided a new perspective on the etiology of the disease. Investigations into the pathogenesis of PD are now considered to fall under the umbrella of "osteoimmunology."<sup>3,4</sup> This interdisciplinary field of study, which emerged almost a decade ago, integrates the

\* Professor & Head, \*\* Post Graduate Student, \*\*\* Senior Resident, Department of Periodontics, Govt. Dental College, Calicut, Kerala

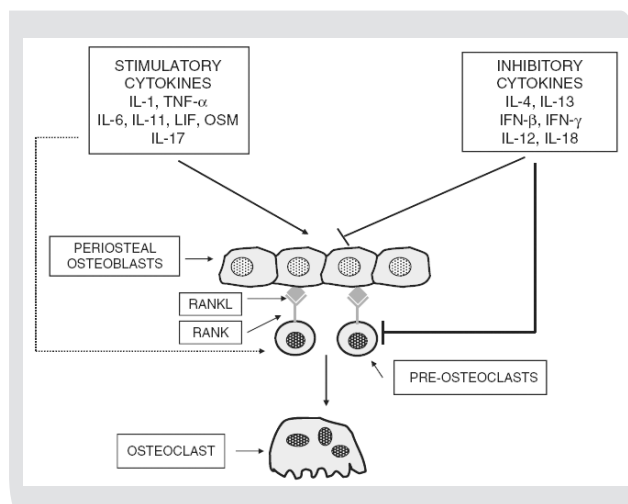


Fig. 1 Recruitment of osteoclasts via RANK/RANKL/OPG interaction

disciplines of immunology and bone biology and has served as a useful framework for improving our understanding of pathogenesis of PD. The framework has catalyzed continued advances in our knowledge of specific cytokines and other mediators involved in the propagation of the inflammatory response and bone resorption in periodontitis.

### The “inflammatory front” in periodontal bone resorption

Bone loss in response to an inflammatory reaction is now known to depend on two critical factors. First, the concentration of inflammatory mediators present in gingival tissue must be sufficient to activate pathways leading to bone resorption. Second, the inflammatory mediators must penetrate gingival tissue to reach within a critical distance to alveolar bone. Achieving critical concentrations of inflammatory mediators that lead to bone resorption depends on the expression of proinflammatory cytokines, such as interleukin (IL)-1, -6, -11, and -17, tumor necrosis factor- $\alpha$  (TNF- $\alpha$ ). Anti-inflammatory cytokines like IL-4, -10, -12, -13, and -18, as well as interferon-beta (IFN- $\beta$ ) and gamma (IFN- $\gamma$ ), serves to inhibit bone resorption.

Osteoclasts are multinuclear giant cells differentiated from mononuclear hematopoietic stem cells. The cells differentiating to osteoclasts are very closely related to the progenitors for monocytes/ macrophages and dendritic cells in the immune system. These progenitors express a large variety of membrane and intracellular receptors for systemic hormones and cytokines. Two of these receptors RANK & receptor for macrophage colony-stimulating factor (denoted c-fms) is important for osteoclast progenitor cell proliferation and survival. RANKL stimulates its cognate receptor RANK, the expression of which is enhanced by macrophage colony-stimulating factor.

### Critical role of rank-l for regulating bone metabolism

Koy and colleagues in 1999<sup>1</sup> discovered receptor activator of nuclear factor  $\kappa$ B ligand (RANK L), a member of TNF-super family. RANK L is expressed by osteoblasts in a membrane-bound protein or cleaved into a soluble form. In addition to osteoblasts, RANKL is expressed by a number of

other cell types, including fibroblasts and T and B lymphocytes. Activated T lymphocytes seem to be a particularly abundant source of RANKL in gingival tissues isolated from individuals with periodontitis. RANKL is expressed at low levels in fibroblasts; however, its expression is induced in response to cytolethal distending toxin from *Aggregatibacter actinomycetemcomitans*.<sup>3</sup> The interaction between RANKL and RANK can be inhibited by osteoprotegerin (OPG), which, like RANK, is a member of the tumor necrosis factor receptor super family and which also can bind to RANKL. Osteoprotegerin (OPG) is ubiquitously expressed also in cells not related to bone.<sup>4</sup>

Bone resorption and formation are regulated by the relative concentrations of RANKL expressed by various cells, as well as RANK on osteoclast precursor cells and the soluble decoy receptor osteoprotegerin (OPG). When RANKL expression is enhanced relative to OPG, RANKL is available to bind RANK. Binding of RANKL to RANK on osteoclast precursors induces differentiation of the preosteoclast into a mature osteoclast. When OPG concentrations are high relative to RANKL expression, OPG binds RANKL, inhibiting it from binding to RANK leading to reduced formation of osteoclasts and apoptosis of preexisting osteoclasts. During an inflammatory response, proinflammatory cytokines, such as IL-1 $\beta$ , -6, -11, and -17 and TNF- $\alpha$ , can induce osteoclastogenesis by increasing the expression of RANKL while decreasing OPG production in osteoblasts/stromal cells. In contrast, excessive formation of bone may be attributed to an abundance of OPG or reduced expression of RANKL, resulting in a net increase in OPG; decrease in the RANKL/OPG ratio. Conversely, a relative decrease in concentrations of OPG or increase in RANKL expression may result in a net increase in RANKL and pathologic bone resorption; increase in the RANKL/OPG ratio. Thus the RANKL–RANK–OPG AXIS is involved in the regulation of bone metabolism in periodontitis. These molecules now form the molecular bridge between the immune system and bone metabolism.

### Rank I & the immune system

RANK L was cloned as an activator of dendritic cells expressed by activated T cells, suggesting its importance in immune system.<sup>5,6</sup> Activated T cells can affect bone physiology by producing cytokines such as TNF- $\alpha$ , IL - I, IL - 17 that leads to RANK L expression on osteoclasts (T cell mediated indirect stimulation of bone resorption). Activated macrophages activate T cells that express and produce RANK L which directly induces osteoclast formation and activation. Recently B cells also have been known to directly express RANK L. OPG blocks all these pathways. (Indirect, Direct T cell or B cell mediated osteoclastogenesis)<sup>7</sup>. However T cells also produce inhibitors of RANK L such as IFN -  $\gamma$  and IL- 4. Thus the balance of cytokines produced by T cells determines the favorable / destructive response.

### CROSS-TALK BETWEEN IMMUNITY AND BONE HOMEOSTASIS:

#### RANKL / RANK / OPG AXIS AND OSTEOIMMUNE INTERACTIONS

Bone remodeling is a dynamic process that is tightly regulated at both local and systemic levels by a number of osteotropic and osteogenic cytokines, growth factors and hormones that exert their effects on osteoblasts and osteoclasts. Before the groundbreaking discovery of RANKL, RANK and its antagonist, OPG, it had long been thought that the development and formation of osteoclasts is

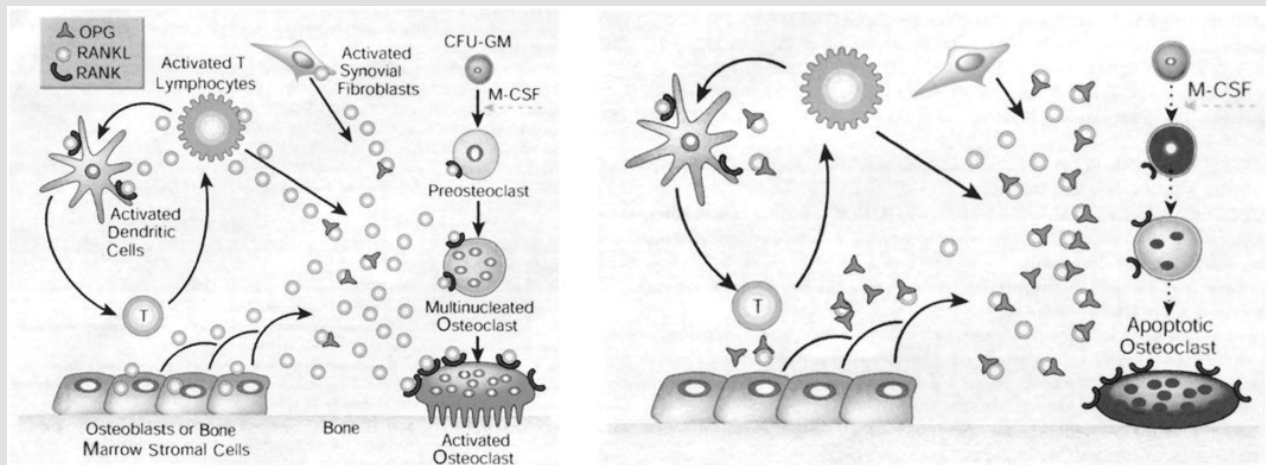


Fig. 2 Mechanism of action of RANKL expression by various cell types in the induction of osteoclastogenesis following binding to RANK on osteoclast precursors (left). An abundance of OPG relative to RANKL (right) inhibits binding of RANKL to RANK, resulting in reduced osteoclastogenesis and the promotion of apoptosis of existing osteoclasts.

M-CSF = macrophage colony-stimulating factor; CFU-GM = colony forming unit for granulocytes and macrophages.

controlled by factors produced by osteoblasts and / or bone marrow stromal cells, but not by the members of the tumor necrosis factor super family, whose physiological functions regulate beyond normal bone-remodeling processes. It is now clear that RANKL / RANK / OPG are the key regulators of bone remodeling, directly involved in the differentiation, activation and survival of osteoclasts and osteoclast precursors.

Blocking RANKL activity via its natural antagonist, OPG significantly inhibits bone loss in rheumatoid arthritis, osteoporosis, cancer-related bone metastasis and diabetes associated alveolar bone destruction.<sup>8</sup> Collectively, the RANKL / RANK / OPG axis is essential for controlling osteoclast development and functions in bone remodeling. These findings have provided an unequivocally strong framework for the new paradigm that links osteoimmunology with various inflammatory bone disorders, including periodontal disease.

### Summary and conclusion

Alveolar bone loss complicating periodontal inflammation (e.g. periodontitis) is the most common form of clinically significant osteopenia occurring in humans. It is now clear that RANKL / RANK / OPG are the key regulators of bone remodeling, directly involved in the differentiation, activation and survival of osteoclasts and osteoclast precursors. Interference with the RANKL / RANK / OPG axis had a protective effect on osteoclastogenesis and Periodontal bone

loss. Such interference may form the basis of therapy in PD in future.

Further study of the genetic factors, initiation, triggering events, interactions between the effectors and memory effects of T-cells and B-cells at the single-cell and molecular levels will help us to dissect these complex regulatory cascades involved in disease pathogenesis and will, in turn, facilitate the generation of useful diagnostics and therapeutics.

### References

1. Clinical Periodontology and Implant Dentistry. 5th edition. Jan Lindhe.
2. Carranza's Clinical Periodontology. 8th, 10th edition. Newman, Takei, Carranza, Klokkevold.
3. Inflammation and Bone Loss in Periodontal Disease. David L. Cochran. J Periodontol 2008;79:1569-1576.
4. Cytokine responses against periodontal infection: protective and destructive roles. Periodontology 2000, Vol. 52, 2010, 163-206
5. Aspects of adaptive host response in periodontitis. Berglundh T and Donati M. JCP 2005.
6. The role of acquired immunity and periodontal disease progression. Yen-Tung A. Teng. Critical Reviews in Oral Biol Med 2003.
7. Immunoregulatory control of Th1/Th2 cytokine profiles in periodontal disease – Gemmel E and Seymour GJ. Perio 2000. Vol.35, 2004, 24-41.
8. Antigen specificity and T-cell clonality in periodontal disease. Yamazaki K, Nakajumi T. Perio 2000. Vol 35, 2004 75-100.

# Serum folic acid level in epileptic patients with phenytoin induced gingival enlargement - a correlative study

\* Mini Jose

## ABSTRACT

**Context:** Folic acid deficiency has been suggested as one of the etiologic factors for phenytoin-induced gingival enlargement

**Aims:** To estimate the serum folic acid level in epileptic patients and in normal healthy controls and to find out the correlation between serum folic acid status and the degree of gingival enlargement in epileptic patients on phenytoin therapy

**Settings and Design:** Epileptic patients in the age group of 16-30 years (N-60) were the main study population. The control group included healthy individuals (N-15).

**Methods and Material:** Epileptic participants were classified into four groups based on the extent of gingival enlargement. The estimation of serum folic acid was done by the microbiological assay using *Lactobacillus casei*.

**Statistical analysis used:** The results were statistically analyzed using students 't' test

**Results:** The mean folic acid levels in healthy controls were 10.75 +/- 2.95 ug/L. In epileptic patients with out gingival enlargement, the mean folic acid levels were 8.44 +/- 2.29 ug/L and it was not found to be significant different as compared with the controls (10.75 +/- 2.95 ug/L). In the epileptic patients with grade 1,2, and 3 enlargement, the mean folic acid levels in serum were 4.47 +/- 1.72, 3.0 +/- 0.80 and 0.93 +/- 0.25 ug/L respectively, and these values were significantly lower when compared to epileptic patients without gingival enlargement and the control subjects ( $p < 0.001$ ).

**Conclusions:** The observations of this study suggest folic acid deficiency as a possible etiologic factor in the development of phenytoin induced gingival enlargement.

**Key-words:** phenytoin, folic acid, gingival enlargement.

**Key Messages:** Folic acid levels must be evaluated before and during phenytoin therapy in epileptic patients and folic acid supplementation must be considered in patients showing gingival enlargement either systemically or as topical application.

## Introduction

Periodontal disease is a complex process involving a wide range of interaction between the commensal population of the mouth and the host tissues. Periodontium and periodontal disease activity can be affected by various local as well as systemic factors. Many drugs can have an adverse effect on the periodontium, for e.g.; gingival enlargement, which is an increase in size of the gingival tissues, due to increase in the number of the number of cells. The drugs which have been reported to produce gingival enlargement can be categorized as follows: anti-epileptics, calcium channel blockers and immuno suppressants. Of these Diphenyl hydantoin or phenytoin, the most widely used drugs in the treatment of epilepsy have been reported to induce gingival proliferation in majority of patients. In patients taking phenytoin, gingival fibroblasts proliferate, causing tissue overgrowth and gingival enlargement.<sup>1</sup> Phenytoin-induced deficiency of salivary IgA can result in increased susceptibility to gingival inflammation, this is considered one of the predisposing factors for subsequent development of gingival

enlargement.<sup>2</sup> Though many medications and combinations of medications are available for the controlling epilepsy, but phenytoin continues to be the most effective treatment for most of the patients. Diphenyl hydantoin (phenytoin) is the widely used antiepileptic drug in the treatment of epilepsy. It has got several side effects like skeletal, endocrine, immunological and connective tissue disturbances. Of these, gingival overgrowth is characterized by an increased amount of non collagenous extracellular matrix, associated with gingival inflammation. The most common side effect of this drug is the development of moderate to severe gingival enlargement in tooth-bearing areas, which can contribute to problems of function, oral hygiene, appearance, and, eventually, loss of teeth.<sup>3</sup> Some studies have shown that the severity of the enlargement increased with increasing dose, also with decreasing age and weight of the patients. The association between serum folic acid levels and degree of enlargement is not conclusive. Poor oral hygiene is said to predispose patients to enlargement.<sup>4</sup> The gingival changes may result from a metabolic by-product rather than the anti-

\* Professor and Head, Mar Baselios Dental College, Kothamangalam



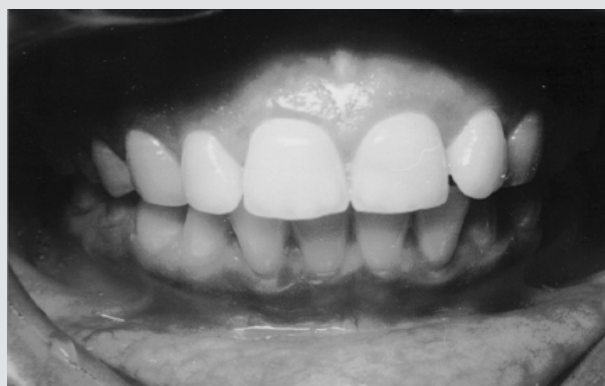

Fig: 1 Normal Gingiva

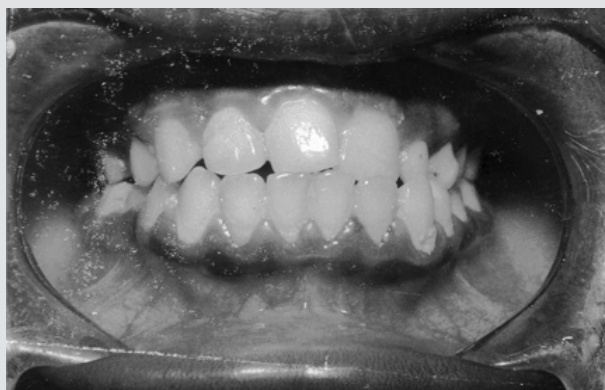

Fig: 2 Grade I Gingival Enlargement

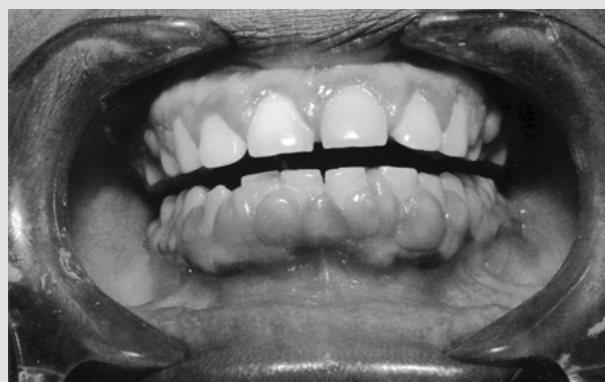


Fig: 3 Grade II Gingival Enlargement

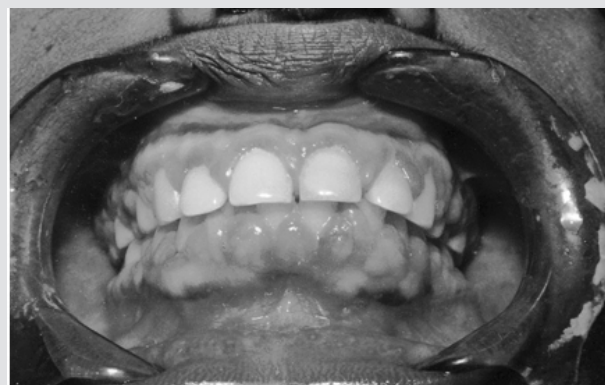

Fig: 4 Grade III Gingival Enlargement

epileptic drugs themselves.<sup>5</sup> By intensive dental care, correct mouth hygiene and by changing the drug to carbamazepine, it is possible to prevent gingival enlargement from phenytoin treatment.<sup>6</sup>

One of the earliest reports of gingival enlargement to be a side effect of anti epileptic therapy with phenytoin was described by Kimball in 1939.<sup>7</sup> Numerous studies have been done in this field in the following years trying to explain the mechanism involved. Baylis studied the influence of folic acid on blood phenytoin levels and found that plasma phenytoin levels fell significantly during folic acid therapy.<sup>8</sup> Similarly Drew et al studied the effect of folate on phenytoin enlargement and found that topical folate significantly inhibited gingival enlargement to a greater extent than either systemic folate or placebo group.<sup>9</sup> More recently, Botez, studied the effects of anticonvulsant treatment and levels of folate and thiamine on amine metabolites in cerebrospinal fluid in epileptic patients. He concluded that the treatment group had significantly higher red blood cell folic acid levels. Poppell et al studied the effect of folic acid on phenytoin induced gingival overgrowth following gingivectomy. He concluded that the treatment group had significantly higher red blood cell folic acid levels.<sup>10</sup> Brown et al studied the effect of administration of folic acid to institutionalized epileptic adults with phenytoin induced gingival enlargement. But, he found that there was no significant difference between the treatment groups and concluded that a single daily dose of three mg capsule of folic acid did not show efficacy as the sole therapeutic agent in the reduction of phenytoin induced gingival enlargement.<sup>11</sup> The uncertainties regarding the relation between serum folic acid and phenytoin therapy prompted us plan a methodologically robust study to understand the correlation in epileptic patients.

**Aims and objectives**

1. To estimate the serum folic acid level in epileptic patients on phenytoin therapy with varying grades of gingival enlargement.
2. To estimate the serum folic acid level in normal healthy controls.
3. To find out the correlation between serum folic acid status and the degree of gingival enlargement in epileptic patients on phenytoin therapy.

**Subjects and Methods**

The study group comprised of sixty epileptic patients selected from the out patient department of Epileptic clinic. These patients were on phenytoin therapy for a period of 2-5 years. The daily drug dosage of these patients varied from 200-300 mg. Both males and females in the range of 16-30 years were considered. These sixty patients were classified into four groups according to the grade of gingival enlargement defined by Angelo Paulos et al.<sup>12</sup> The epileptic patient selection was based on extent of gingival enlargement.

Group 1 – Epileptic patients with out any gingival enlargement (normal gingiva – grade)

Group 2 – Epileptic patients with hyperplastic gingiva covering the cervical 3rd or less, of the anatomic crowns of anterior teeth (grade 1)

Group 3 – Epileptic patients with hyperplastic gingival extended anywhere in the middle 3rd of the anatomic crowns of anterior teeth (grade 2)

Group 4 – Epileptic patients with hyper plastic gingival covering more than 2/3 of the anatomic crowns of anterior



teeth (grade 3)

A control group of fifteen healthy individuals were also selected. All the participants were screened clinically, biochemically and biophysically to exclude any other systemic diseases. A proforma was prepared to record all details of patients and controls. Examination of oral cavity was performed with a mouth mirror and William's graduated periodontal probe, under artificial light. The plaque index<sup>13</sup>, calculus component of simplified oral hygiene index 14 and the degree of gingival enlargement were assessed.<sup>12</sup> For folic acid level estimation five ml of blood sample was obtained by venipuncture from each subject and allowed to clot undisturbed in a centrifuge tube for 1 hour at 37°C. The supernatant serum was then collected using Pasteur pipette. These sera were stored in aliquot at -20°C till the investigations were carried out. From the stored sera 0.5 ml was pipetted out into an assay tube and mixed with ml of ascorbic acid- phosphate buffer. All the assay tubes were autoclaved at 121°C for 1 min and then cooled in a tap water bath. The tubes were shaken and centrifuged at about 2200 rpm for 15 minutes. Then 0.5 ml of the clear supernate was transferred in duplicate to 15 x 125 mm tubes containing 1.5 ml double distilled water. Rest of the supernate was decanted and frozen, so as to enable repetition of the sample if required. One of the duplicate tubes was set aside as serum blank for each specimen and two tubes with 2.0 ml water to serve as media blank. A standard curve was then prepared in duplicate with the working standard. About 3.0 ml of Lactobacillus casei broth was then added to all the tubes. All the serum blank tubes and the media Blank tubes were placed into separate racks. All the tubes were covered with aluminum foil and autoclaved at 121°C for 2.5 minutes. After cooling 0.025 ml of L.casei inoculum was added to all the tubes except the blanks with a sterile capillary pipette. These tubes were then incubated at 37°C for 20 hours. The tube s were removed from the incubator and then placed in an ice bath until the readings were taken. The optical density was then taken with a photometer using 540 nm filter.

The results were statistically analyzed using students 't' test

## Results

The study was conducted to estimate the serum folic acid levels in epileptic patients on phenytoin therapy. Sixty epileptic patients with various grade of gingival enlargement (grade 0-3) were included in the study. For comparison of the results, 15 age and sex matched controls were included. The serum folic acid level was evaluated by microbiological assay using Lactobacillus casei. The age distribution of the subjects selected for the study is depicted in table 1. The mean folic acid levels in epileptic patients with various grades of gingival enlargement are depicted in table 2. The folic acid levels in healthy controls were 10.75 +/- 2.95 ug/L. In epileptic patients with out gingival enlargement, the folic acid levels were 8.44 +/- 2.29 ug/L and it was not found to be significant when compared with the controls (10.75 +/- 2.95 ug/L). In the epileptic patients with grade 1,2, and 3 enlargement, the folic acid levels in serum were 4.47 +/- 1.72, 3.0 +/- 0.80 and 0.93 +/- 0.25 ug/L respectively, and these values were significantly lower when compared to epileptic patients without gingival enlargement and the control subjects (p<0.001)

## Discussion

Diphenyl hydantoin (phenytoin) is the widely used antiepileptic drug in the treatment of epilepsy. It is said to

Table 1: Age distribution of subjects selected for the study

Epileptic patients with different grades of gingival enlargement					
	Normal controls	Grade 0	Grade 1	Grade 2	Grade 3
Number of subjects	15	15	15	15	15
Age range in years	16-30	16-28	16-25	16-29	16-30

Table 2: Serum folic acid levels of epileptic patients with various grade of gingival enlargement and normal control subjects

Subjects	Serum folic acid (ug/L) Mean +/- SD
Normal controls(N=15)	10.75 +/- 2.95
Epileptic patients with grade 0 gingival enlargement(N=15)	8.44 +/- 2.29
Epileptic patients with grade 1 gingival enlargement (N=15)	4.47 +/- 1.72
Epileptic patients with grade 2 gingival enlargement(N=15)	3.00 +/- 0.80
Epileptic patients with grade 3 gingival enlargement (N=15)	0.93 +/- 0.25

have several side effects like skeletal, endocrine, immunological and connective tissue disturbances.<sup>15,16</sup> Of these, gingival overgrowth is characterized by an increased amount of non collagenous extracellular matrix, associated with gingival inflammation.<sup>17,18</sup> A number of investigators have examined the direct effect of phenytoin and its metabolites on gingival connective tissue but the mechanism by which the drug brings about gingival enlargement remains obscure.<sup>19,20,21</sup> Although no significant relationship has been established between the gingival enlargement and the amount of local irritants, some investigators suggested that good oral hygiene an the prevention of gingival inflammation are important factors in controlling the drug induced gingival proliferation.<sup>22</sup>

Many theories have been suggested to explain the pathogenesis of phenytoin induced gingival overgrowth. In the gingival connective tissue different subpopulations of fibroblasts, some of which are capable of high protein and collagen synthesis (high activity fibroblasts), and others capable of low protein synthesis (low activity fibroblasts). The proportions of high to low activity fibroblasts are genetically determined. High activity fibroblasts in presence of certain predisposing factors become sensitive to phenytoin and there is a subsequent increase in collagen production. Another theory is based on the correlation of gingival enlargement to salivary and gingival tissue level of phenytoin.<sup>20</sup> Phenytoin can accumulate selectively in dental plaque resulting in high concentration of the drug near the disrupted epithelium. An immunologic basis for phenytoin induced gingival overgrowth has been proposed, since a significantly lower concentration of salivary IgA has been found in patients taking phenytoin.<sup>2</sup> It has been suggested that phenytoin induces degranulation of mast cells and liberation of substances that capable of increased cell

reproduction and collagen formation. The occurrence of phenytoin induced gingival overgrowth can be related to the effect of phenytoin on the metabolism of steroid hormones, increases in their level may be correlated to these hyperplastic changes.<sup>23</sup>

Folic acid deficiency has been associated with increased gingival inflammation.<sup>24,25,26,27,28</sup> The results of several clinical studies have indicated that supplementation with folic acid either systemically or by topical application resulted in a decrease in the plaque induced inflammatory response.<sup>29</sup> Some studies have hypothesized that the phenytoin induced changes in folate metabolism could render the gingival more susceptible to inflammation from local etiological factors and there by contribute to the drug induced gingival enlargement.<sup>30</sup>

The proposed mechanisms of phenytoin induced folic acid depletion include inhibition of the enzyme folate conjugase, phenytoin induced impairment of folic acid transport into the tissues, malabsorption of the vitamin from the intestinal lumen due to the alkaline pH produced by the drug, depletion of folic acid via enhanced metabolic process resulting from phenytoin induced liver enzyme activity or by displacement of the vitamin from its carrier protein. These interactions may result from the similarity in chemical configuration of the both phenytoin and folic acid.<sup>31,32,33,34</sup>

The role of folic acid (5mg/day) in combination with oral hygiene measures (group II) vis-a-vis oral hygiene measures alone (group I) in prevention of phenytoin-induced gingival overgrowth was investigated by Prasad et al in a one-year follow-up study on sixty, 8-13-year-old epileptic children receiving phenytoin.<sup>35</sup> The allocation of the children to the two groups was done alternately. In these children, at baseline, plaque (Silness & Loe), gingivitis (Loe & Silness) and probing depths of gingival sulcus were recorded. These parameters were reevaluated at 3-monthly intervals when gingival overgrowth was also recorded (Modified Harris & Ewalt Index). It was seen that, after a period of one year, gingival overgrowth occurred in 60 and 50

percent children of groups I & II respectively and its development, too, was delayed in group II. More cases (93 percent) in group II exhibited minimal overgrowth as against 78 percent in group I. The study concluded that systemic folic acid prescribed along with phenytoin delays the onset and reduces the incidence and severity of gingival overgrowth induced by phenytoin

The observations of the present study strongly suggest a definite correlation between the serum folic acid status and the degree of gingival enlargement. Further studies in this field may help to enlighten the exact role of phenytoin in the development of gingival enlargement. The results indicated a significant reduction in folic acid level in patients with grade 1, 2, and 3 gingival enlargement, when compared to epileptic patients without gingival enlargement and controls. The observations of this study suggest folic acid deficiency as a possible etiologic factor in the development of phenytoin induced gingival enlargement.

**References**

1. Stinnett, E., B. Rodu, and W.E. Grizzle, New developments in understanding phenytoin-induced gingival enlargement. *J Am Dent Assoc* 1987;114:814-816.
2. Aarli, J.A., Phenytoin-induced depression of salivary IgA and gingival enlargement. *Epilepsia* 1976;17:283-291.
3. Walker, C.R., Jr., C.E. Tomich, and C.E. Hutton, Treatment of phenytoin-induced gingival enlargement by electrosurgery. *J Oral Surg* 1980;38:306-311.
4. Addy, V., et al., Risk factors in phenytoin-induced gingival enlargement. *J Periodontol* 1983;54:373-377.

5. Butler, R.T., K.L. Kalkwarf, and W.B. Kaldahl, Drug-induced gingival enlargement: phenytoin, cyclosporine, and nifedipine. *J Am Dent Assoc* 1987;114:56-60.
6. Tigarán, S., A 15-year follow-up of phenytoin-induced unilateral gingival enlargement: a case report. *Acta Neurol Scand* 1994;90:367-370.
7. Kimball, O.P., The treatment of epilepsy with sodium diphenyl hydantoinate. *J Am Med Assoc* 1939;112:1244-1939.
8. Baylis, E.M., J. Crowley, and P. Jm., INfluence of folic acid on blood phenytoin levels. *Lancet* 1971;1: 62-64
9. Drew HJ, Vogel RI, Molofsky W, Baker H, Frank O. Effect of folate on phenytoin enlargement. *J Clin Periodontol* 1987;14: 350-356
10. Poppell, T.D. and S.D. Keeling, Effect of folic acid on recurrence of phenytoin induced gingival overgrowth following gingivectomy. *J Clin Periodontol* 1991;18: 134-139
11. Brown, R.S., P.T. Stanislaw, and W.T. Beaver, Administration of folic acid to institutionalized epileptic adults with phenytoin induced gingival enlargement: a double blind, randomised, placebo controlled parallel study. *Oral Surg Oral Med Oral Pathol* 1991;71:565.
12. Angelopoulos AP and G. PW, Incidence of diphenylhydantoin gingival enlargement. *Oral Surg Oral Med Oral Pathol* 1972;34:898-906.
13. Silness, J. and H. Loe. Periodontal disease in pregnancy. II. Correlation between oral hygiene and periodontal condition. *Acta Odontol Scand* 1964;22:121-135.
14. Greene, J.C. and J.R. Vermillion, The simplified oral hygiene index. *J Am Dent Assoc* 1964;68:7-13
15. Yaari Y, Selzer ME, Pincus JH. Phenytoin: Mechanisms of the anticonvulsants action *Ann Neurol* 1986; 20:171
16. Reynolds EH. Chronic antiepileptic toxicity; a review. *Epilepsia* 1975; 16:319
17. Nuki K, Cooper SH. The role of inflammation in the pathogenesis of gingival enlargement during the administration of diphenyl hydantoin to cats. *J Periodontal Res* 1972; 7:102
18. Modeer T, Dahllof G, Reinholt FB, Wikstrom B, Hjerpe A. proteoglycans and phenytoin induced gingival overgrowth. *J Periodontal Res* 1986; 21:13
19. Aas E. Enlargement gingivae diphenyl hydantoinae. A clinical histochemical and biochemical study. *Acta Odontol Scand suppl* 1963; 21:34
20. Shafer WG. Effect of dilantin sodium on growth of human fibroblast like cell cultures. *Proc Soc Exp Mol Med* 1960; 104:198
21. Hiramatsu M, hatakijama k, Abe I, Minami N. The effect of diphenyl hydantoin sodium on acid mucopolysaccharide and collagen contents of cotton pellet granulomas in rats. *J Periodontal Res* 1979; 14:173
22. King D, Hawes R, Bibby B. The effect of oral physiotherapy on dilantin enlargement. *J Oral Pathol* 1976; 5:1
23. Vittek J et al. Phenytoin effect on the proliferation of rat oral epithelium is mediated by a hormonal mechanism. *Cell Differ* 1983; 12:335
24. Klipstein FA. Subnormal serum folate and macrocytosis associated with anticonvulsant drug therapy. *Blood* 1964; 23:68
25. Flexner JM, Heartman RC. Megaloblastic anemia associated with anticonvulsant drug. *Am J Med* 1969; 28:386
26. Hassell TM. Epilepsy and Oral Manifestations of Phenytoin Therapy. Basel, New York, Karger 1981.
27. Malpas JS, Spray GN, Sitts LJ. Serum folic acid and vitamin B levels in anticonvulsant therapy. *Br Med J* 1966;00:00-000,
28. Reynolds EH, Milner G, Mathews D, Chanarin T. Anticonvulsant therapy, megaloblastic haematopoiesis and folic acid metabolism. *Quar J Med* 1966; 35:521
29. Pack A. Thomson M. Effects of topical and systemic folic acid supplementation on gingivitis in pregnancy. *J Clin Periodontol* 1980; 11:619
30. Vogel RI. Gingival enlargement and folic acid deficiency from anticonvulsant drug therapy. *A Theor Biol* 1977; 67:269
31. Girwood RH. Folic acid, its analogues and antagonists. *Adv Clin Chemistry*. 1960; 3:235
32. Herbert V, Zalusky R. interrelation of vitamin b and folic acid metabolism; Folic acid clearance studies *J Clin Invest* 1962;41:1263
33. Hawkins CF, Maynell MJ. Macrocytosis from anticonvulsant drugs. *Quar J Med* 1958; 27:46
34. Vogel RI. Relationship of folic acid to phenytoin induced gingival overgrowth. In *Phenytoin Induced Teratology and Gingival Pathology*. Pp 163 Raven press, New York 1980.
35. Prasad V N, Chawla H S, Goyal A, Gauba K, Singhi P. Folic acid and phenytoin induced gingival overgrowth - is there a preventive effect. *J Indian Soc Pedo Prev Dent* 2004; 22:82-91.

# Comparative evaluation of Myeloperoxidase levels among systemically healthy individuals and patients with type 2 Diabetes Mellitus, with chronic periodontitis – A biochemical study

\* Amitha Ramesh, \*\* Biju thomas, \*\*\* Aparna anand, \*\*\*\* Suchetha kumari

## ABSTRACT

**Objectives:** To estimate the levels of salivary myeloperoxidase in systemically healthy individuals and those with type 2 diabetes mellitus having chronic periodontitis.

**Study design :** Single centre case –control study

**Setting:** Unstimulated saliva sample obtained

**Sample:** Sample size consisted of forty patients between the ages thirty five to sixty five years. Categorization was based on random blood glucose levels whereby Group one consisted of 20 patients with random blood glucose levels below 126mg/dl and Group two consisted of 20 patients with random blood glucose levels above 126mg/dl and both groups with chronic periodontitis.

**Method:** Estimation of myeloperoxidase levels using 4-aminoantipyrene as the hydrogen donor method and subjected to spectrophotometric analysis.

**Results:** The mean myeloperoxidase levels in group one and group two was found to be 0.08 and 0.11 respectively. The myeloperoxidase levels are lower in group one as compared to group two which is statistically significant with  $P < 0.05$

### Conclusions

1) Myeloperoxidase level is increased in the saliva of patients with type 2 DM as compared with systemically healthy individuals of both the groups showing chronic periodontitis.

2) Myeloperoxidase may be considered for use as a potential biomarker of periodontal disease activity.

**Key words:** Myeloperoxidase, Type 2 Diabetes Mellitus, Saliva, chronic periodontitis

## Introduction

Diabetes mellitus (DM) is a chronic metabolic disorder that affects more than 100 million people worldwide. Oral health complications associated with diabetes that may be encountered by dental practitioners include xerostomia, tooth loss, gingivitis, periodontitis, odontogenic abscess and oral soft tissue lesion of tongue and oral mucosa. Periodontal disease may be more frequent and severe in diabetic individuals with more advanced systemic complications. An association between DM and periodontitis has now been reasonably well documented for both Type1 and Type 2 DM. Metabolic disturbances in periodontal tissues may lower the resistance of diabetics to infections and thus influence the initiation, development and progression of inflammatory periodontal disease. However local and systemic infections may predispose to resistance to insulin usage, as well as control of periodontal disease, which is beneficial to diabetic control. It may also reduce insulin requirements<sup>1</sup>.

Saliva plays a major part in the maintenance of oral mucosal and dental health and changes in the amount and the quantity of saliva may alter the oral health status<sup>2</sup>.

Diabetes is known to cause micro vascular disease and autonomic neuropathy both of which affect salivary secretion<sup>3</sup>.

Saliva is a fluid that can be easily collected, contains locally and systemically derived markers of periodontal disease. Specifically periodontogenic bacteria stimulate local host response that enhances the production of prostaglandins and inflammatory cytokines and the recruitment of lytic enzymes such as elastase and myeloperoxidase causing subsequent damage to periodontal tissues<sup>4</sup>. The use of saliva for periodontal diagnosis has been the subject for considerable research activity and proposed marker of disease include protein of host origin like enzymes, immunoglobulins, phenotypic markers, host cells, hormones, bacteria and their products, volatile compounds and ions.

Salivary peroxidase system is one of the most important non-immunological defense systems in saliva. It consists of salivary peroxidase derived from parotid gland, leukocyte derived myeloperoxidase originating from the GCF and saliva. The relative contribution of myeloperoxidase to total salivary peroxidase actively depends on the presence of periodontal

<sup>1</sup> Professor, <sup>2</sup> Professor & Head, <sup>3</sup> Post graduate Student, Department of Periodontics, A.B. Shetty Memorial Institute of Dental Sciences, <sup>4</sup> Professor (MSc, PhD Biochemistry), Department of Biochemistry, K.S. Hegde Medical Academy



T-Test

Table No.1 Comparison of mean myeloperoxidase levels between systemically healthy individuals and patients with diabetes mellitus, both groups with chronic periodontitis.

Group values	N	Mean	Std. Deviation	Mean Difference	t	p
Group1	20	.08025	.006273	.035150	19.677	.0005
Group2	20	.11540	.004946			

The 'P' value in the above analysis is <0.05 and the results are statistically significant.

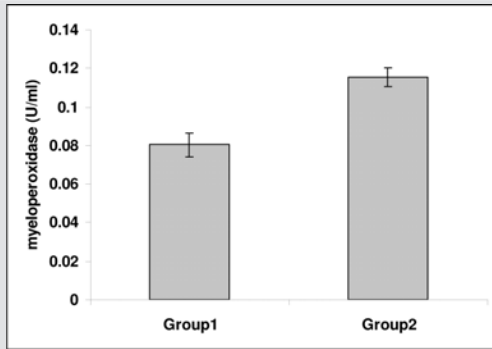


Fig 1 Comparison of mean myeloperoxidase levels between systemically healthy individuals (Group one) and patients with diabetes mellitus (Group two); both groups with chronic periodontitis

or oral inflammation<sup>5</sup>.

Myeloperoxidase is an enzyme present in the primary granules of the neutrophils. This polymorphonuclear specific enzyme generates large amount of hypochlorite ions in the presence of hydrogen peroxide and chloride. Products of the myeloperoxidase-hydrogen peroxide-halide system have wide biological reactivities and can mediate a number of physiological effects including microbial killing, tumour cell lysis and inactivation of toxins and inflammatory regulators. Myeloperoxidase enzyme is released due to the interaction of polymorphonuclear neutrophils with micro-organisms during phagocytosis. Myeloperoxidase could participate in the initiation and progression of periodontal disease because myeloperoxidase derived oxidants contribute to tissue damage and initiation and propagation of acute and chronic vascular inflammatory disease. Assays of saliva, serum and GCF have a positive correlation between myeloperoxidase levels, inflammation and pocket depth.

The aims and objectives of this study are

- To estimate the level of myeloperoxidase in systemically healthy subjects with chronic periodontitis.
- To estimate the level of myeloperoxidase in subjects with Type 2 Diabetes Mellitus and chronic periodontitis.
- To compare the levels of myeloperoxidase in systemically healthy subjects with chronic periodontitis and subjects with Type 2 Diabetes mellitus and chronic periodontitis.

**Materials and Method**

The subjects for the study were selected from the out patients visiting the Department of Periodontics, A.B. Shetty Memorial Institute of Dental Sciences, Derlakatte, Mangalore. The sample size included forty patients from both sexes with an age range of 35-65years. They were divided into two groups:

GROUP ONE - Twenty patients with chronic periodontitis showing loss of attachment ≥3 mm (systemically

healthy)

GROUP TWO- Twenty patients with type 2 diabetes mellitus and chronic periodontitis showing loss of attachment ≥3mm. A screening examination comprising of the medical history, dental history and clinical attachment levels was carried out for patient selection. Criteria for selection included subjects in the age group of thirty five to sixty five years, subjects with a minimum of twenty teeth, subjects with a loss of clinical attachment ≥ 3mm, diabetic subjects identified by modified WHO criteria with fasting blood glucose ≥126mg/dl<sup>6</sup>. Pregnant women, lactating women and women in their menstrual phase, individuals with habit such as smoking and subjects who have received any periodontal therapy/antimicrobial therapy/anti-inflammatory/steroid therapy in the past 6 months were excluded from the study.

Periodontal disease activity was recorded at BASELINE for all groups using mouth mirror and Williams graduated periodontal probe. Informed consent of the patient was taken. Saliva samples were taken for estimation of myeloperoxidase. Patient was instructed not to consume any type of food for one hour before saliva collection. Saliva collection was performed in the morning. Approximately two ml of unstimulated whole saliva was collected and stored in a collection vial. Samples were sent for estimation immediately.

Saliva samples of healthy and diabetic chronic periodontitis groups were analysed in lab for myeloperoxidase activity by comparing test and control reactions spectrophotometrically.

- 0.1ml saliva sample (100 micro litres)
- 0.5ml buffer (sodium phosphate ph=6.1)
- 0.5ml hydrogen peroxide (prepared by diluting 0.1ml Hydrogen peroxide to 10ml of distilled water and then diluting 0.1ml of this first dilution again to 10ml of distilled water-second dilution)

0.5ml 4- aminoantipyrene  
Immediately after addition of 4-aminoantipyrene readings were recorded on Model 6A Coleman spectrophotometer (Systronyx, Bangalore, India) at one minute intervals for 5 minutes. Delta absorbance (δ) is the average of these 5 readings recorded at 510nm. One unit of myeloperoxidase is defined as the change in absorbance of 1.0 optical density units per minute at 510nm.

$$\begin{aligned} \text{Enzyme activity} &= \delta \times \text{Reaction value} \\ &= \delta \times 1.6 \\ &= \text{MPO units/ml} \end{aligned}$$

The results obtained were tabulated and subjected to statistical analysis using "Unpaired student t test".

Statistical analysis was done in P.C. statistical package (SPSS) 6.0 Version. The mean and standard deviation of myeloperoxidase levels in systemically healthy and diabetic individuals were calculated.

Students unpaired 't' test was done as significance for myeloperoxidase levels.

STUDENTS UNPAIRED 't' TEST;  
 $t = \frac{X1 - X2}{S.E}$   
X1-mean of group 1  
X2-mean of group 2  
S.E.-standard error

## Results

A total of forty subjects were selected for the study. The aim of the study was to estimate the salivary myeloperoxidase levels in systemically healthy individuals and those with Type 2 Diabetes mellitus; both groups with chronic periodontitis. The study group consisted of twenty patients who were systemically healthy with chronic periodontitis and twenty patients with Type 2 diabetes mellitus with chronic periodontitis. Quantitative evaluation of myeloperoxidase levels in saliva were done in both the groups; results were tabulated. Mean values and standard deviations were calculated.

The mean values of myeloperoxidase levels were correlated in both groups and the results were statistically analysed. (Table No.1; Figure No.1)

## Discussion

Currently saliva has been used extensively for determining disease activity and destructive changes in the periodontium.

Periodontal disease is considered to be of episodic pattern with phases of activity and inactivity rather than a continuously progressive lesion. Disease activity involves a complex interaction between the periodontopathogens, defense mechanism of the host and their products. This interaction between the periopathogens and the host defense may be reflected by certain constituents in the saliva which are identified as markers of disease progression.

Several factors act to modify the host response to aggressive agents and hence alter the periodontitis expression and progression.

The greater severity and prevalence of periodontal disease in diabetes subjects may be related to GCF alterations, vascularisation of periodontal tissues, host immunoinflammatory response, collagen metabolism and genetic patterns.

One such marker for which this study is based on is myeloperoxidase. It is an enzyme released by the azurophil granules of the polymorphonuclear leucocytes during phagocytosis. In the present study myeloperoxidase level in saliva of systemically healthy individuals with chronic periodontitis and patients with type 2 DM and chronic periodontitis were compared.

Results clearly showed that myeloperoxidase level is an indicator of pdl disease activity.

Group one consisted of twenty patients with  $CAL \geq 3mm$ . The mean myeloperoxidase level was found to be 0.08. These values were used as a control and compared with MPO levels in the other group (diabetic with chronic periodontitis). The MPO level in group one are in accordance with the studies conducted by Wolff et al who compared the myeloperoxidase levels in diseased and healthy sites. The study showed that the mean MPO level in diseased group is  $0.032 \pm 0.015$ . This may be attributed to increase polymorphonuclear leucocytes activity in periodontitis sites. Smith et al have shown that MPO level in pretreatment groups was higher than post treatment groups.<sup>7</sup>

Group two consisted of twenty patients with  $CAL \geq 3mm$  and random blood glucose  $\geq 126mg/dl$ . The mean MPO level was found to be 0.11. These values are comparatively higher

than values obtained in group 1. Studies evaluating the saliva of patients with type 1 and 2 diabetes mellitus have reported greater SPO activities. This has been demonstrated in studies by Tenuovo et al, Guven et al and Dodds et al. Dodds et al also showed that there was a significant increase in salivary myeloperoxidase activity<sup>8</sup>.

Diabetic individuals present a deficiency in the defense mechanisms against infectious agents. Studies investigating immunological defence mechanisms have demonstrated an increase in the production of individual cytokines and pro-inflammatory mediators. However, there are few studies addressing the non-immunological defence mechanisms in individuals with inadequate metabolic control of diabetes mellitus<sup>9</sup>.

On comparison between both groups, increase myeloperoxidase was found in group two. This may be attributed to the periodontal tissue destruction which is mediated by the interaction between host and bacterial agents including a number of enzymes.

However studies by Aren et al and Tenuovo et al have not shown any significant differences in SPO or MPO activity in this group of patients<sup>10</sup>.

Nevertheless, there are some methodological differences between the present study and the above mentioned investigations. In the present study the enzyme activity was evaluated rather than its concentration, as did some of those authors, and the diabetic group was formed exclusively by DM 2 patients<sup>5</sup>.

## Conclusion

The following conclusions were arrived at;

1) Myeloperoxidase level is increased in the saliva of patients with type 2 DM as compared with systemically healthy individuals of both the groups showing chronic periodontitis.

2) Myeloperoxidase may be considered for use as a potential biomarker of periodontal disease activity.

## References

1. Gamze A, Elif S, Didem O, Erhan F: Periodontal health, salivary status and metabolic control in children with type 1 diabetes mellitus. *J Periodontology* 2003;74:1789-1795.
2. Page RC, Soms TJ, Delima AJ, Bimstein E, Needleman HL, Van Dyke TE. The relationship between periodontitis and systemic disease and conditions in children, adolescents, and young adults. In: Bimstein E, Needleman H, Karimbux N, Van Dyke TE, eds. *Periodontal Diseases in Children*. London: Martin-Dunitz; 2001:108-109
3. Meurman JH, Collin HL, Niskanen L, et al. Saliva in non insulin dependent diabetic patients and control subjects. The role of the autonomic nervous system. *Oral Med Oral Pathol Oral Radiol Endod* 1998;86:69-76.
4. Kaufman E, Lamster I: Analysis of saliva for periodontal diagnosis – A review. *J Clin Periodontol* 2000;27:453-46
5. Gonsalves D, Cornea F, Khalil NM, De faria Oliveira: The effect of non surgical periodontal therapy on p eroxidase activity in diabetic patients: a case control pilot study. *J clin periodontol* 2008;35:799-806.
6. American Diabetes Association. Report of the Expert Committee on the Diagnosis and Classification of Diabetes Mellitus. *Diabetes Care* 1997;20:1183-97.
7. Smith, A.J., Smith, G., Basu, M. K. & Walsh, T.F. Changes in salivary peroxidase activity observed during experimentally-induced gingivitis. *Journal of Periodontology* 1984: 11, 373-378.
8. Dodds MWJ, Yeh CK, Johanson DA: Salivary alterations in type 2 diabetes mellitus and hypertension; *Community Dent Oral Epidemiol* 2000;28:373-81
9. Guven Y, Satman I, Dinccag N, Alptekin S: Salivary peroxidase activity in whole saliva of patients with insulin dependent (Type-1) diabetes mellitus. *J Clin periodontol* 1996;23:879-881.
10. Saxen L, Tenovuo J: Salivary defense mechanisms in juvenile periodontitis *Acta Odontologica Scandinavica* 1990;48:399-407.



# Gingival depigmentation with diode laser - A case report

\* Seba Abraham, \*\* Prakash P, \*\* Ambili R., \*\*\* Nisha,  
\*\*\*\* Mekha Grace Varghese, \*\*\*\* Azza Haneefa

## ABSTRACT

Gingival pigmentation is a common esthetic complaint among South Indian population. Various treatment options are in practice for depigmentation which include scalpel gingivectomy, free gingival graft surgery, use of chemicals, bur abrasion, cryo-surgery & lasers. Among the various techniques Lasers offer a promising therapeutic option since it is simple, painless & predictable. Here, we report laser gingival depigmentation done for a 24 year old female patient. We have carried out 2 yr follow up & the results are remaining satisfactory.

## Introduction

Colour of gingiva depends on number & size of blood vessels, epithelial thickness, quantity of keratinization & pigments within epithelium like melanin, carotene, reduced hemoglobin & oxy-hemoglobin. Melanin is the most common natural pigment contributing to color of gums. Although ethnic & physiologic melanin pigmentation is not a medical pathosis, appearance of pigmented gingival is considered unaesthetic.<sup>1,5</sup>

Various depigmentation techniques include:-

1. scalpel gingivectomy
2. free gingival graft surgery
3. chemical agents like phenol & alcohol
4. bur abrasion techniques
5. cryosurgical technique
6. LASERS

Among these techniques, laser therapy is a compatible, simple & painless procedure which is quite predictable too.

The treatment of gingival depigmentation seems to have taken a paradigm shift from surgical/invasive to non-invasive, painless & more effective procedures using lasers.

Lasers selectively ablate cells producing & containing melanin by using a laser beam of a wavelength that is specifically absorbed in melanin & effectively destroys pigmented cells without damaging other non-pigmented cells. Here, the radiation energy is converted into ablation energy. Hence cellular rupture & vaporization occurs with minimal heating of surrounding tissues.

## Procedure

A 24 year old female patient reported to the Dept of Periodontics of PMS Dental college of dental science & research with a gummy smile & hyper pigmented gingival (fig 1). She had undergone orthodontic treatment for

correcting the proclination of upper & lower anterior teeth 5 years back. After orthodontic correction she became more conscious about pigmented gingiva which was more visible with the aggravated gummy smile.

Initially topical anesthetic spray was given on the upper & lower labial gingival. Injected LA was not at all used. Procedure was performed using the Bio-Lase Ezlase 914nm diode Laser (fig 2) at 2.0 W power & in a pulsed mode (pulse length 0.50 ms & pulse interval 0.50 ms). After the selected power setting are entered, laser is activated by a foot pedal. The tip is held in light contact with the tissues & the procedure is performed with light sweeping brush strokes (fig 3 ). High-volume suction is used near the tissue. The whole procedure of depigmenting upper & lower gingival took about 15-20 minutes.

Patient reported a needle pricking sensation during the procedure. Patient was advised to take Paracetamol 650mg immediately after the procedure (fig 4). Patient was asked to continue her normal diet in contrast to the cold liquid diet usually suggested after a conventional scalpel depigmentation. Immediately after the procedure the gums were fiery red which lasted for about 48 hours (fig 5). Gums turned more and more pink in the next couple of days. The patient was followed up for 2 yr period & the results are well maintained (fig 6).

## Discussion

LASER is an acronym for Light Amplification by Stimulated Emission of Radiation, based on theories & principles first put forth by Einstein in the early 1900s. The first actual laser system was introduced by Maiman in 1960.<sup>2</sup>

Laser light is a manmade single-photon wavelength. The process of lasing occurs when an excited atom is stimulated to remit a photon before it occurs spontaneously.

\* Head of the Department, \*\* Reader, \*\*\* Senior Lecturer, \*\*\*\* Junior Resident, Department of Periodontology, PMS Dental College, Trivandrum

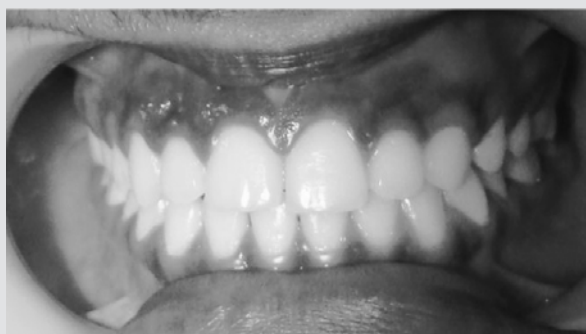

Figure 1: Pre-operative view



Figure 2: Laser equipment

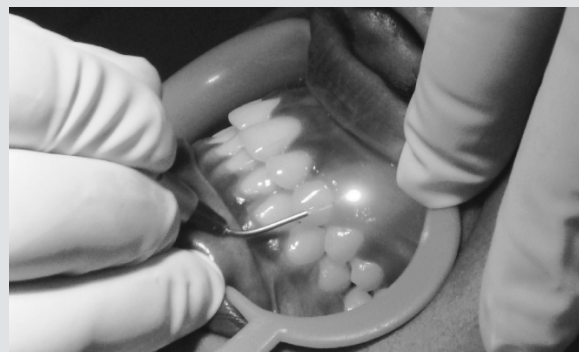

Figure 3: Operative view

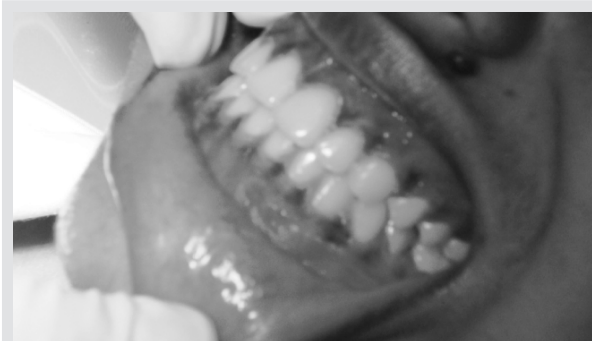

Figure 4: Immediate post-op view

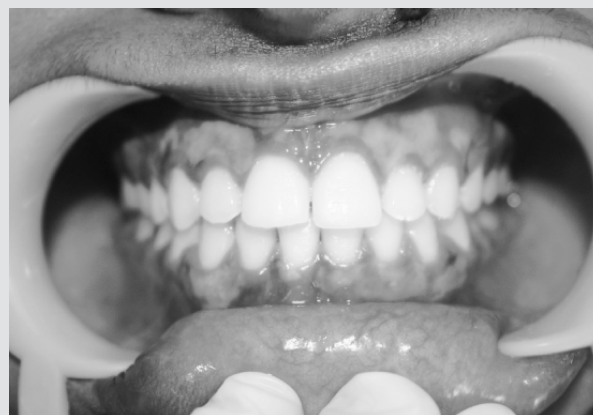

Figure 5: 48 hrs post-op view

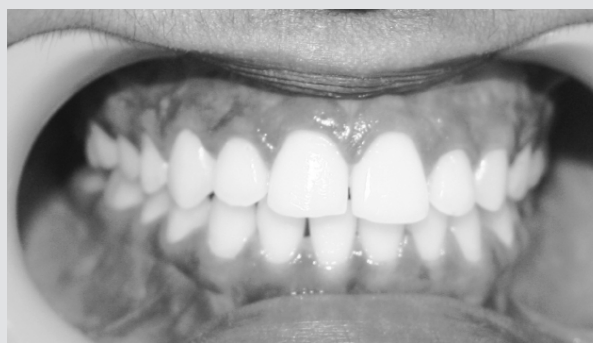

Figure 6: 2 yr follow up

Stimulated emission of photons generates a very coherent, collimated, monochromatic ray of light.<sup>3</sup>

Because laser light is so concentrated and focused, it can have a decided effect on target tissue at a much lower energy level than natural light. The effect of laser light on target tissue is dependent on its wavelength, which is determined by the lasing medium inside the laser device.

When laser light comes into contact with the tissue, it can reflect, scatter, be absorbed, or be transmitted to the surrounding tissues. The most desirable interaction is the absorption of laser energy by water, haemoglobin, oxy-haemoglobin & melanin causing

1. Photothermal effect- ablation of tissues by vaporization
2. Photochemical effect - bio stimulation
3. Photoconductive – breaking apart of tissues<sup>1</sup>

In biological tissue, absorption occurs because of the presence of free water molecules, proteins, pigments, and

other organic matter. In the thermal interactions caused by laser devices, water molecules and their absorption coefficient play a strong role.<sup>4</sup>

Thus it can peel off epithelial layer from the underlying connective tissue & can aid in gingival depigmentation. Various lasers used in dentistry for soft tissue procedures are carbon dioxide laser, Nd:Yag lasers & diode lasers.

### Diode laser

It is a solid state semiconductor laser that typically uses some combination of gallium, arsenide & other elements such as aluminium & indium to change electrical energy to laser energy. It delivers continuous & gated pulsed mode laser energy fibre-optically. Diode lasers utilize invisible wavelength in near infra-red region of electromagnetic spectrum & is therefore equipped with a quartz fiber incorporating a 630nm as an aiming beam.<sup>1,9</sup>

### Advantages

1. Faster & efficient
2. Minimally invasive
3. Pain-free post-operative period
4. Little or no anesthesia required
5. Precise bloodless tissue removal
6. Immediate esthetic result

### Disadvantages

1. Expensive
2. Technique-sensitive
3. Need for eye protection for doctor, patient & assistant
4. Hyper pigmentation can reappear in 6 months to 1 year time
5. Tissue penetration from laser may cause thermal damage to underlying hard tissues <sup>7,8</sup>

### Healing after Laser depigmentation

Histologically, laser wound initiates healing by proliferation of epithelial cells from the borders of the wound & the ingrowth of fibrous tissue within the fibrin coagulum covering the wound site. There is moderate inflammatory reaction with minimal edema. Wound epithelialises within 7-21 days depending on the area. The healed laser wound epithelial layer is very thin with few identifying rete pegs. Within 60 days there is restoration of characteristic rete pegs also there is development of thick sub mucosal fibrous tissue which causes 50% reduction in elasticity compared with normal scalpel gingivectomy.

### Conclusion

Lasers are a very promising treatment option for gingival depigmentation.

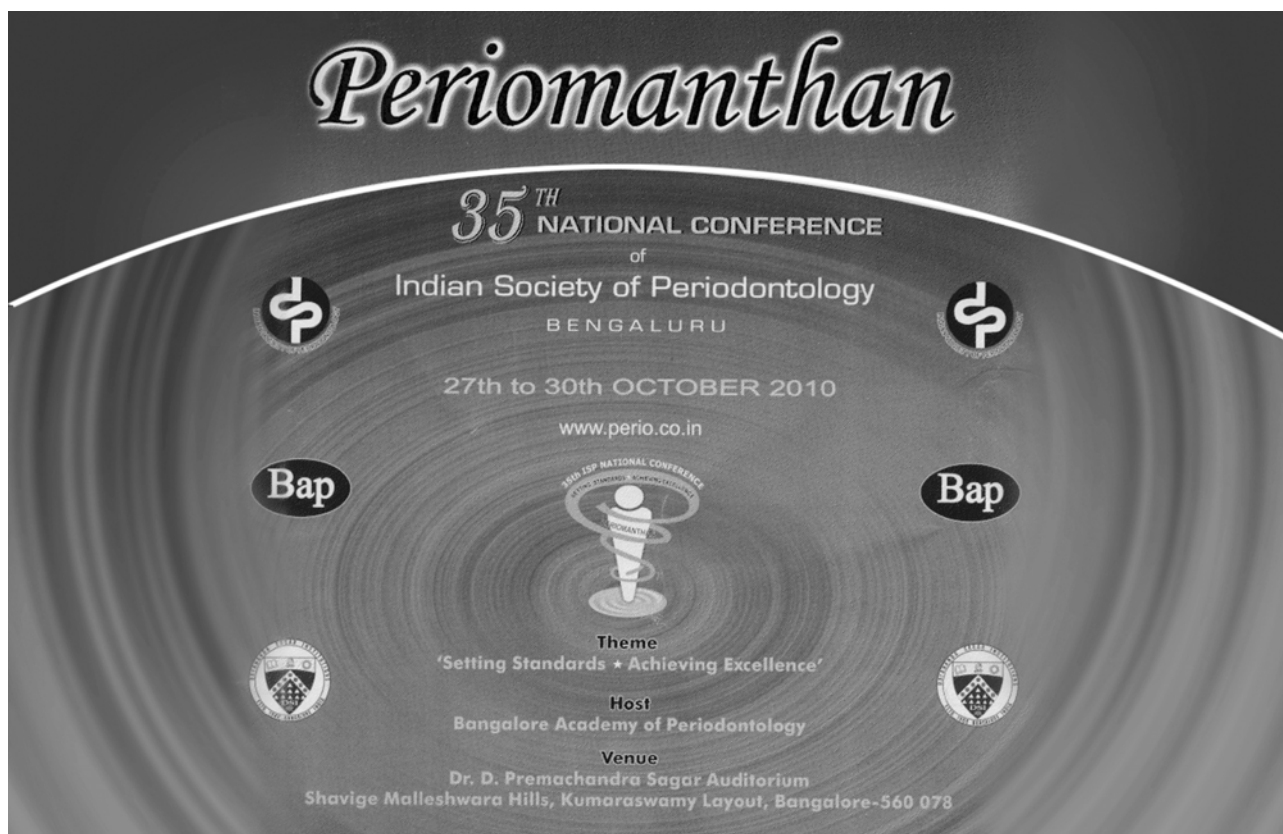
Diode laser (940nm) provides an alternative technique with marked clinical improvement & high degree of patient acceptance. The small portable size of the unit is of beneficial effect for the general dentist.

Because of good coagulation, patient's surgical period is reduced & patients are saved from high risk infections. It provides sterile blood-free operating field for controlled tissue sculpting. Exceptionally precise tissue ablation at low power settings & also enables char-free ablation & haemostasis.

Thus the diode laser has proved to be an effective, safe, bloodless, painless and easily applicable therapy for gingival depigmentation.<sup>6</sup>

### References

1. Management of gingival hyper pigmentation by surgical abrasion- Report of three cases; Sameer A Mokeem, Saudi Dental Journal ISSN 1013-9052 :ESSIN-1658-3558
2. Maiman TH. Stimulated optical radiation in ruby. Nature 1960: 187: 493-494.
3. Clayman L, Kuo P. Lasers in Maxillofacial Surgery and Dentistry. New York: Thieme, 1997: 1-9.
4. Niemz MH. Laser-tissue Interaction. Fundamentals and Applications. Berlin: Springer-Verlag, 1996: 64-65.
5. The normal and pathological pigmentation of oral mucous membrane-A review -Cicek Y The journal of contemporary dental practice- vol 4, No 3, August 15, 2003
6. Depigmentation was never so easy-A Case Report by Dr.Natasha F Merchant, Journal-Australasian Dental Practice-May/June 2008
7. SOLAZE-journal of laser dentistry - vol.1 issue 1 Jan 2007
8. SOLAZE-journal of laser dentistry - vol.2 issue 1 Jan 2008
9. Light work-Using a diode soft tissue laser in orthodontic treatment-Stephan Tracey Orthodontic products,business management for orthodontists. Issue April 2005





# Host modulation

\* P. Jayachandran

## ABSTRACT

The concept of host modulation is fairly new to field of dentistry but is universally understood by most physicians who routinely apply the principles of host modulation in management of no: of chronic progressive disorders. In dentistry the term was introduced by William and Golub and later on expanded on by others in dental profession. This articles gives an overview of host modulation agents.

## Introduction

Plaque biofilm and associated host responses are involved in the pathogenesis of periodontitis. Current data suggest that a small group of predominantly Gram negative, anaerobic bacteria with in the biofilm are often associated with disease initiation and progression. The microbial challenge consisting of antigens, LPS and other virulence factor stimulate host responses, which result in disease, limited to the gingiva or initiation of periodontitis. Protective aspect of the host response includes recruitment of neutrophils, production of protective antibodies and possibly the release of anti-inflammatory cytokines.

The determination that periodontal tissue destruction is primarily due to the host response has created area of research directed at altering an individual's reaction to bacterial challenge. Various host modulating therapeutics have been developed or proposed to block pathway responsible for periodontal tissue breakdown.

## Modulation of host cytokines

Cytokines, literally "cell proteins" in etymology, transmit information from one cell to another via autocrine or paracrine mechanism. Following specific binding to their complementary receptor pro-inflammatory cytokines like IL-1 and TNF trigger intercellular signaling events and catabolic cell behaviors.

To counterbalance catabolism and maintain homeostasis both IL – 1 and TNF have endogenous inhibitors. IL –1 receptor antagonist is structurally related to IL – 1. It binds to receptor without trigger signal transduction. The type 2 IL – 1 receptor and the extracellular domain of TNF receptor (1 & 2) can occur in soluble forms as competitive antagonist<sup>8</sup>.

IL-1 receptor and TNF receptor antagonist have been reported to inhibit allergen-induced inflammation, ocular inflammation, LPS induced acute pulmonary inflammation and toxic endotoxin. Both IL – 4 and IL – 10 can target macrophage the release of IL-1, TNF, reactive oxygen intermediates and nitric oxide and IL-10 plays a major role in suppressing immune and inflammatory response Produced by T cell, B, Cell, monocytes and macrophage

Other cytokines, which are involved in the suppression of the destructive inflammatory response, include IL – 11.

In a ligature induced canine model, recombinant human IL – 11 shown to reduce disease progression by it inhibitory action of production of TNF- $\alpha$ , IL –1 and nitric oxide.<sup>9</sup>

## Nitric Oxide

Nitric oxide (NO) is a free radical with important physiological functions including CVS, nervous system and immune homeostasis. Nitric oxide activates MMP in cultured chondrocytes. Functions as a 2nd messenger mediating the effects of the pro-inflammatory cytokine IL-1b in articular chondrocytes. High local cover of nitric oxide and peroxynitrite (product of NO + superoxide) are cytotoxic to bacteria, fungi protozoa and tumor cells may also cause deleterious host effects such as DNA damage, lipid peroxidation, and protein damage and stimulate of inflammatory cytokines. The inhibition of inducible nitric oxide has been associated with decrease carragernan-induced inflammation depressed hemorrhagic shock in animal models

## Nitric oxides inhibitors

- 1) L-N<sup>G</sup>- monomethyl arginine: inhibits both inducible and constitutive nitric oxide forms.
- 2) L-arginine methyl ester: - inhibits both inducible and constitutive nitric oxide forms.
- 3) Mercaptoethylguanidine:- selective inhibitor of inducible nitric oxide forms. Mercaptoethylguanidine blocks inducible NOS scavenge peroxynitrite and inhibit cyclooxygenase pathways.
- 4) N-iminoethyl-L-lysine: - selective inhibitor of inducible nitric oxide forms.
- 5) Reduces MMP activity in cartilage, decrease production of IL-1 $\beta$  by synvium.<sup>10</sup>

## Other host inflammatory mediators

### Nuclear factor kappa B

It's an important transcription factor complex that appears to play a fundamental role in regulating inflammation. Occurs inactively in the cytoplasm of most inflammatory cells but is activated and released in response to pro-inflammatory stimuli. Free nuclear factor kappa B diffuses across the nuclear membrane, binds to DNA and stimulates cytokine gene expression and release.<sup>9</sup>

\* Professor & HOD, Amrita School of Dentistry, Kochi - 682 041

### Antagonist for endothelial cell adhesion molecules

E selection an ICAM-1 expressed on endothelial cell membranes that are responsible for the rolling and tethering of leukocytes during extravagation events. Agents such as tepoxatin, Sodium cromoglycate, BMS-190394 and Kappa-opoid PD 117302 show promise in inflammation models.

### Modulation of arachidonic acid metabolism

The arachidonic acid (AA) metabolites include a variety of fatty acid derived components that are enzymatically produced and released in response to local tissue injury.

These metabolites have been collectively implicated in a wide range of events that are associated with disease, such as platelet aggregation vasodilatation and vasoconstriction, neutrophil chemotaxis and increase vascular permeability.

Also implicated as principal catabolic mediation is periodontal disease since they are potent stimulate of bone resorption are present in gingival tissue C are elevated in disease individuals. Its concentration increases in diseased periodontal sites in range of 10 to 20 times.

One proposed approach to modulate the host response is inhibition of enzymes responsible for the release of these destructive products. NSAIDs may be of therapeutic value in treating periodontal disease because of their abilities to interfere with AA metabolism and thereby the inflammatory process. Periodontal therapy in periodontitis patients' subjects who received adjunctive antibiotic therapy exhibited equipment gains in CAL when compared with subjects receiving either ibuprofen or placebo. Adverse effect of prolonged administration of non-selective Cox - 1 and Cox - 2 NSAIDs includes gastric upset and hemorrhage, renal and hepatic impairment Recently selective NSAIDS called Cox - 2 inhibitors have been developed that selectively block isoenzyme associated with inflammation rather than that associated with homeostasis.

### Lipoxins

Lipoxins are series of archidonic acids derivatives formed by interaction between individual lipoxygenases and appear to function as endogenous anti-inflammatory agent. Lipoxins are potent counter regulatory signals in-vitro and in-vivo endogenous pro-inflammatory mediators, including lipids (leukotrienes, PAF) and cytokines (TNF- $\alpha$ , 1L-6) resulting an of leukocyte dependent inflammation. It has compensatory or protective role to limit PMN activity and PMN mediated damage.

LxB4 stimulates proliferation & differentiation of granulocyte-monocyte colonies from human mononuclear cell<sup>4</sup>

### Triclosan

Phenol derivative (2, 4, 4 tricoloro 2-hydroxyl diphenyl ether) is a non-ionic antimicrobial agent. Used as mouthwashes and in tooth pastes. It has both an antibacterial and anti inflammatory agent

Actions: -

1. Acts on microbial cytoplasmic membrane inducing leakage of cellular constituents and there by causing bacteriolysis.

2. Also inhibits cycloxygenase and lipoxygenase and thus may interfere with the production of AA metabolites. Use of dentifrice containing sodium fluoride (0.243%) and triclosan (0.3%) with 2.0% PVM/M copolymer (polyvinyl methyl ether malaecic acid copolymer) reduced the frequency of deep periodontal pockets and the number of sites

exhibiting attachment and bone loss in patients deemed highly susceptible to periodontitis (Rollin B et al - 1

### Matrix metallo proteinase inhibition

MMPs are a family of Zn<sup>+</sup> and Ca<sup>+</sup> dependent endopeptidases secreted or released by variety of inflammatory cells.

Belong to a family proteolytic enzyme that degrades extracellular matrix molecules such as collagen, gelatin, and elastin. These are secreted by various cell types. One mechanism of MMP activation involves the proteolytic cleavage of a portion of the latent enzyme. Example, chymotrypsin like protease produced by T. denticola, Neutrophil Cathepsin-G. The role of inhibitors is particularly important because its an imbalance between the activated MMPs and their inhibitors that leads to pathological breakdown of the extracellular matrix to disease such as periodontitis and arthritis. Compensating for the deficit in the naturally accruing inhibitors or TIMPs to block or retard the proteolytic destruction of connective tissue is of therapeutic significance. Tetracycline, which may modulate many of these matrix protective mechanisms, have been found to be effective of MMPs mediated connective tissue destruction in variety of pathological processes.<sup>2</sup>

### Tetracycline

Mechanisms by which tetracycline inhibits connective tissue breakdown.

#### A. Mediated by extracellular mechanisms

1. Direct inhibition of active MMPs dependent on Ca<sup>2+</sup> and Zn<sup>2+</sup> binding properties of tetracycline.

2. Inhibition of oxidative activation of pro-MMP - independent of cation binding properties of tetracycline.

3. Tetracycline disrupt activation by promoting excessive proteolysis of into enzymatically inactive fragments, dependent on cation binding of tetracycline.

#### B. Mediated by cellular regulation

1. Tetracycline decreases cytokines, inducible nitric oxide synthase, phospholipase A2 and prostaglandin synthesis

2. Effect on protein kinase C, calmodulin.

#### C. Mediated by Pro anabolic effects

1. Increased collagen production.

1. Osteoblastic activity and bone formation<sup>3</sup>.

### Chemically modified tetracycline

The antimicrobial and anticollagenase properties of tetracycline reside in different parts of the drug molecules. The carboxyl and hydroxyl groups at C-11 and C-12 respectively might be essential for the anticollgenase property.

CMT, have devoid of antimicrobial activity but retains their anticollagenase activity pathologically elevated collagenase activity both in-vivo and in-vitro.

Bone resorption in-vitro / in-vivo at conc. 5-10 mg/ml. This inhibition was reversible, removal of tetracycline after 48 hrs resulted in resumption of bone resorption.

#### Mechanism of action:

1. Prevent the oxidative activation of latent pro-MMPs.

2. Decreased levels of pro-inflammatory cytokines.

3. Prevent the formation of multinucleated osteoclast like cells from tartrate resistant and phosphatase-stained cells of the osteoclast lineage

4. Bind to the osteoclast sensor (i.e. calcium sensor or ryanodine receptor on its plasma membrane) & diminishes cells functions i.e. matrix adhesion, cell spreading,



podosomes expressions, enzyme secretion & bone resorption.

5. CMTs may also bind to the ryanodine receptor on the nuclear membrane, alter the nucleoplasmic calcium influx and consequently affect osteoclast gene expression and apoptosis.<sup>1</sup>

2. Increased level of IL-10, an anti-inflammatory cytokine, resulting in reduced osteoclastogenesis and bone resorption.

### Subantimicrobial dose doxycycline (sdd)

Doxycycline Hyclate (Periostat):- Available as 20-mg capsule, prescribed twice daily for use. Approved by U.S Food and Drug Administrator for the adjunctive treatment of periodontitis. It acts by suppression of the activity of collagenase, particularly that produced by PMNs. It does not exhibit antimicrobial effects but can effectively lower MMP level.

Evidence indicates that LDD regimens can

1) Inhibit the pathologically elevated collagenase actively in the gingival tissues and in the GCF of patient with adult periodontitis.

2) Reduce the typical side effect produced by commercial available dose regimens of tetracyclines presumably because the peaks or maximum serum levels is reduced by about 90% compared to regular dose doxycycline regimens.

3) Prevent the progression of periodontitis assessed by measuring attachment loss

#### Bisphosphonates

These are analogs of pyrophosphate in which the carbon atom replaces the linking oxygen atom in the pyrophosphate molecule. There are completely resistant to enzymatic hydrolysis (alkaline phosphatase, pyrophosphatase) and are extremely stable. Bind to the hydroxyapatite crystals of bone and prevent both their growth and dissolution. Substitution of different side chains for hydrogen at locations R<sub>1</sub> and R<sub>2</sub> changes the potency and side effect profile of the compound.

#### Mechanism of action

##### A) Tissue level

- Decrease bone turnover due to decrease bone eruption.

- Decrease number of new bone multicellular units.
- Net positive whole body bone balance.

##### B) Cellular level

- decrease osteoclast recruitment
- increase osteoclast apoptosis
- decrease osteoclast adhesion
- decrease depth of resorption site
- decrease release of cytokines by macrophages
- Increase osteoblasts differentiation and number.

##### C) Molecular level

- Inhibits mevalonate pathway (can result in perturbed cell and induction of apoptosis.

- Decrease post-translational prenylation of GTP-binding proteins.

contra indications for use:

1 Sensitivity to phosphate.

2 GI upset

Drawbacks:

1 Chronic administration over long periods to be effective.

2 High cost and accessibility.

3 A full body irradiation that would occur since these agents have to be administered IV.<sup>5</sup>

### Estrogen and Selective Estrogen Receptor Modulators (SERMs)

Estrogen deficiency is associated with large increase in bone resorption, with osteoclast formation and activity and reduced osteoclast apoptosis. Treatment with estrogens clearly inhibit bone loss as well as bone turnover and increase bone mineral density. The estrogens inhibit both osteoclast activity and differentiation by regulating production of stimulating and inhibitory by cytokines by osteoblasts and monocytes.

The effect of steroid hormones as metabolic mediators of the expression of cytokines may be plausible explanation for the protective effect of estrogen supplementation against periodontal disease.

The discovery of the agents able to exert full or partial estrogen effects on various tissues led to the development of a new class of drug known as SERMs. The mechanism by which SERMs inhibit bone resorption is likely to be the same as estrogens mechanism, by blocking production of cytokines that promote osteoclast differentiation and by promoting osteoclast apoptosis. SERMs appear to offer many of the benefits of estrogen with fewer adverse effects. SERMs have been noted to improve blood cholesterol level. Raloxifen is the first drug in this class approved for the treatment of osteoporosis. Taxonifen is another drug of this class used in follow up treatment of some women with breast cancer

#### Anti-integrins

A Key early event in the bone resorptive process is the attachment of the osteoclast to the bone matrix. This matrix attachment is mediated by integrin primarily  $\alpha\text{-v}\beta\text{3}$ , and result in the intimate contact of the osteoclast with the matrix to be resorbed and formation of the sealing zone that enables the osteoclast to isolate a micro-environment beneath it to facilitate resorption. Blocking the adhesion of osteoclasts to their target matrix through the use of agents that disrupt integrins has been reported to inhibit bone resorption and may provide viable option after clinical investigation.<sup>7</sup>

### Periodontal vaccines

Vaccination is a process that induces specific immune resistance to bacterial or viral infectious diseases. The key features of a successful vaccine are safety, effectiveness, stability, a long shelf life and relatively low cost.

Vaccination can be accomplished two methods.

1. Active immunization: Individuals immune system is stimulated by administering killed or live attenuated bacteria or virus components or attenuated products derived from micro-organism.

2. Passive immunization – Antibodies formed in one individual are transferred to another.

The complexity of periodontopathic bacteria might be a problem in determining of antigen for vaccine against periodontal disease. Among >500 species, 5-7 species have been implicated in the etiology of periodontitis. But one or two species *P.gingivalis* and *B. forsythus* might play an important role as primary pathogen. The development of vaccine against periodontitis might be possible and the utilization it could be an effective method for control and prevention of periodontal disease

#### DNA Vaccines

These are developed based on viral and bacterial peptides and plasmid vectors. They might induce immunity to numerous agents including periodontopathic bacteria, following confirmation of their safety.

#### Advantages:

1. Manufactured more easily than vaccines consisting

of an alternated pathogen, an outer or internal proteins or recombinant proteins.

2. Since DNA is stable by nature and resistant to extremes of temperature storage, transport and distribution it might be highly practical.

3. The simplicity of changing the sequence encoding antigenic proteins by means of mutagenesis and of adding heterologous epitopes by basic molecular genetic framework

### Conclusion

The periodontal therapist has a challenge treating bone loss due to periodontal disease. When considering different therapeutics, one needs to keep the goal in view of the presenting periodontal status. Inhibition of resorption is most effective when administered prior to the time when a patient would be susceptible to bone loss i.e. as a preventive measure. There are situation in which conventional therapy does not always achieve the desired clinical outcome. In these instances and for specific groups of periodontal disease susceptible individuals the use of HMT in conjunction with anti-biofilm treatments may prove to be advantageous. As methods that modulate the host response become available, they may be useful as adjunctive therapies for a variety of clinical situations.

### References

1. Clinical periodontology. 9th edition by Carranza
2. Maria emmanuel, Ryan Lorne E, Modulation of matrix metalloproteinase activity in periodontitis as a treatment strategy Perio 2000; 1997, Vol 14; 79-11, 144-157
3. Laurie K McCauley, Rahime M, Nochutchu, Mediators of periodontal osseous destruction and remodeling: Principles and implications JP 2002; 73: 1377-1391
4. Jan Potempa, Jim Travis Role of bacterial proteinase in matrix destruction and modulation of host response Perio – 2000; 2000; Vol 24: 226-252
5. Howard C Tenebaum, AviShelemay, Bruno Gerard, Ron Zohar, Peter C Fritz Biphosponates and periodontics JP – 2002; 73; 813-822
6. Braz J Medical Biol Res – 2001 (May) Vol-34 (5); 555-506
7. Informational paer: Modulation of host response in periodontal therapy JP 2002; 73: 460-470
8. Nungavaram S Ramamurthy, Barry R Rifkin, Robert A Greenfield et al Inhibition of metalloproteinase mediated periodontal bone loss in rats: A comparison of 6 chemically modified tetracycline JP 2002; 73: 726-734
9. Graham Embery, Racheal J Waddingston Connective tissue elements as diagnostic aids in Periodontology JADA – 1994; Vol 125 (Feb); 163-169
10. Dennis E Lopatin, Charles E Shelburne, Neal Van Poperin Humoral immunity to stress protein and periodontal disease JP- 1993-64; 819-827

## INFORMATION FOR AUTHORS

**Membership:** One of the authors should be either a life member/associate member/affiliate member of SPIK

**Manuscripts:** Articles should be type written on one side of A4 size (21x28cm) White paper in double spacing with a sufficient margin. One Original and two high quality xerox copies should be submitted. The author's name is to be written only on the original copy and not on the two xerox copies. In addition to the printed version, a CD containing the article file also should be submitted compulsorily. Use a clear and concise reporting style. SPIK reserves the right to edit, manuscript, to accommodate space and style requirements. Authors are advised to retain a copy for the reference.

**Title Page:** Title page should include the title of the article and the name, degrees, positions, professional affiliations of each author. The corresponding authors, telephone, e-mail address, fax and complete mailing address must be given.

**Abstract:** An abstract of the article not exceeding 200 words should be included with abbreviated title for the page head use. Abstract should state the purpose of the study, investigations, basic procedures and the main findings.

**Tables:** Tables should be self explanatory, numbered in roman numbers, according to the order in the text and type on separate sheets of paper like legends for illustrations.

**Illustrations:** Illustrations should be clearly numbered and legends should be typed on a separate sheet of paper, while each figure should be referred to the text. Good black and white glossy photographs or drawings drawn in black Indian ink on drawing paper should be provided. Photographs of X-rays should be sent and not the original X-rays. Prints should be clear and glossy. On the back of each print in the upper right corner, write lightly the figure number and author's name; indicate top of the photograph with an arrow of word 'Top'. Slides and X-ray photographs should be identified similarly.

**Photographs:** Author's photograph - Stamp size, Black and White, glossy photographs should be sent along with the article.

**Reference:** Reference should be selective and keyed in numerical order to the text in Vancouver Style (not alphabetical). Type them double spaced on a separate sheet of paper. Journal references must include author's names, article title, journal name, volume number, page number and year. Book reference must include author's or editor's names, chapter title, book title, edition number, publisher, year and page numbers.

**Copy right:** Submission of manuscripts implied that the work described has and not been published before (except in the form of an abstract or as part of published lectures, review or thesis) and it is not under consideration for publication elsewhere, and if accepted, it will not be published elsewhere in the same form, in either the same or another language without the comment of copyright holders. The copyright covers the exclusive rights of reproduction and distribution, photographic reprints, video cassettes and such other similar things. The views/opinions expressed by the authors are their own. The journal bears no responsibility what so ever.

The editors and publishers can accept no legal responsibility for any errors, omissions or opinions expressed by authors. The publisher makes no warranty, for expression implied with respect to the material contained therein. The journal is edited and published under the directions of the editorial board/review panel who reserve the right to reject any material without giving explanations. All communications should be addressed to the Editor. No responsibility will be taken for undelivered issues due to circumstances beyond the control of the publishers.

**Books for review:** Books and monographs will be reviewed based on their relevance to SPIK readers. Books should be sent to the Editor and will become property of SPIK.

**Return of articles:** Unaccepted articles will be returned to the authors only if sufficient postage is enclosed with the manuscripts.

**Subscription Rates:** Free distribution for all the members of the SPIK.

**Inland Subscription:** Rs. 500 per issue, Rs. 1500 for 1 Year, Rs. 2500 for 2 years, Rs. 3500 for 3 years.

Articles may be submitted to: Dr. Prakash Prabhakaran, Editor-SPIK, Thoppil House, Pallimukku, Pettah P.O., Keralakaumudi Jn., Trivandrum - 695 024; e-mail: prakashpmds@gmail.com; Mobile: 098950 66112

# Probiotics in the management of periodontal diseases

\* Seema Jayakrishnan \*\* Prakash Prabhakaran \*\*\* Shamnad CA  
\*\*\* Smrithi Varma \*\*\*\* Anitha S

## ABSTRACT

Probiotics have been found to be beneficial to host health. In medicine, probiotics are used mainly in support therapy for gastro-intestinal diseases. In recent years, probiotics have been used as a treatment to promote oral health. Studies have found that bacteria causing periodontal disease could be regulated by applying a probiotic which inhibited their growth. Although brushing and flossing will undoubtedly remain the intrinsic part of effective oral hygiene regimes, research into the potential efficacy of probiotics has increased over the past decade. But scientific understanding of probiotics and their potential for preventing and treating periodontal disease is still at its infancy. Extensive research to create a probiotic product intended to maintain dental and periodontal health is needed.

## Introduction

In the early 1900's, Dr. Metnikoff of Russia found that certain Bulgarians lived longer, pain free and disease free lives. He attributed their healthy longevity to their diet. The diet consisted of yogurt, sour dough, bread and buttermilk. Dr. Metnikoff discovered that these fermented foods contained friendly beneficial bacteria that were able to take rotten putrescence food and digest them to release by products that were full of nutrients and destroyed the foul odor. These friendly bacteria kept the potential pathogens from causing disease. These friendly bacteria were termed "Probiotics".

Probiotics were defined by FAO/WHO (The Food Agricultural Organization / World Health Organization) as live microorganisms which when administered in adequate amounts (in food or as a dietary supplement) confer a health benefit on the host (improving microbiological balance in intestinal tract)<sup>1</sup>. The term 'probiotic' means 'for life'. 'Probiotic' as opposed to 'antibiotic', was initially proposed by Lilley and Stillwell in 1965. First probiotic species to be introduced in research was *Lactobacillus acidophilus* by Hull et al in 1984<sup>2</sup>; followed by *Bifidobacterium bifidum* by Holcomb et al in 1991<sup>3</sup>.

Several clinical studies have already demonstrated the effectiveness of certain probiotics in the treatment of systemic and infectious diseases such as acute diarrhea and Crohn disease<sup>4</sup>. Other studies have suggested potential applications in the treatment of cardiovascular disease, urogenital infections and cancers. Probiotics may also prove useful in treating problems arising from the excessive use of antibiotics, specifically the appearance of bacterial resistance.

The oral cavity has only recently been suggested as a relevant target for probiotic applications. So far, 'oral probiotics' have been evaluated primarily in the management of dental caries. However, there are very few studies on probiotics from the periodontal health perspective. The following review explores the role of probiotics in periodontal diseases.

## How probiotics work

Several mechanisms have been proposed to explain how probiotics work (fig.1). For example, these bacteria secrete various antimicrobial substances such as organic acids, hydrogen peroxide and bacteriocins<sup>5</sup>. In addition, they compete with pathogenic agents for adhesion sites on the mucosa. A process called competitive exclusion<sup>6</sup>. Probiotics can also modify the surrounding environment by modulating the pH and/or the oxidation-reduction potential, which may compromise the ability of pathogens to become established. Finally, probiotics may provide beneficial effects by stimulating non-specific immunity and modulating the humoral and cellular immune response<sup>7</sup>.

## Probable mechanisms of action of probiotics with respect to periodontal disease

Due to the widespread emergence of bacterial resistance to antibiotics, the concept of probiotic therapy has been considered for the application in oral health. Dental caries, periodontal disease and halitosis are among the oral disorders that have been targeted.

For a probiotic bacterium to exert oral health effects it should be able to adhere to and successfully establish itself in the oral biofilm. *Lactobacilli* constitute about 1% of the

\*Reader \*\*Professor and Head \*\*\*Senior Lecturer \*\*\*\*Junior Lecturer  
Department of Periodontics, Sri Sankara Dental College, Akathumuri, Trivandrum

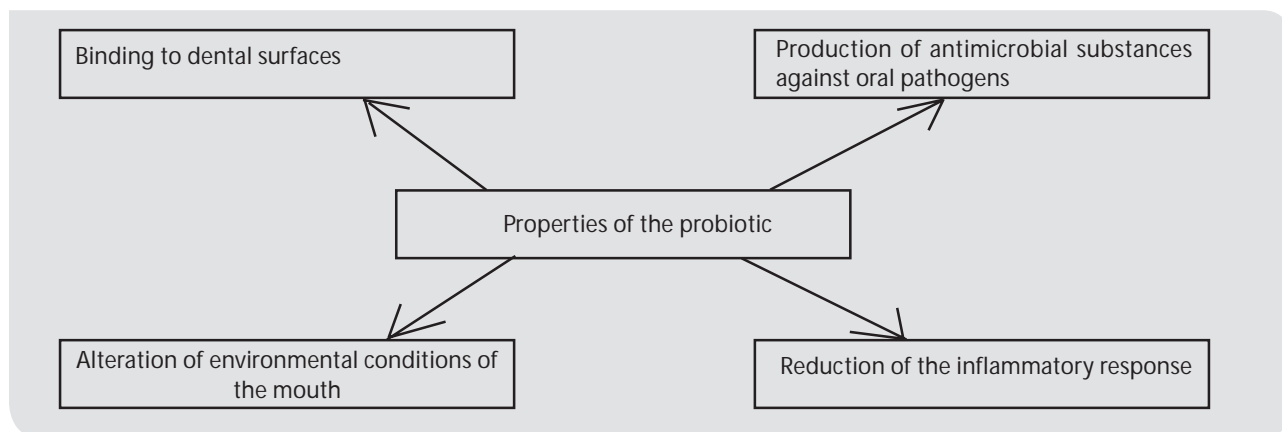


Fig. 1 Mechanism of action of probiotics

cultivable oral microflora in humans. It has been reported that *L.rhamnosus* and *L.paracasei*<sup>8</sup> strains possess strong binding activity. It is recognized that high values of cell surface hydrophobicity correlate with superior adhesive properties<sup>9</sup>. Sookkhee and colleagues<sup>10</sup> found that isolates of *L.paracasei* and *L.rhamnosus* had a high capacity to antagonize important oral pathogens, including *Streptococcus mutans* and *Porphyromonas gingivalis*.

*Weissella cibaria*, a gram positive facultative anaerobic lactic acid bacterium, secretes a significant quantity of hydrogen peroxide<sup>11</sup> and bacteriocin that act against Gram-positive bacteria<sup>12</sup>. This bacterial species has the capacity to coaggregate with *Fusobacterium nucleatum* and to adhere to epithelial cells. The properties could enable *W.cibaria* to effectively colonize the oral cavity and limit the proliferation of pathogenic bacteria.

Recently, Marcotte et al<sup>13</sup> have shown that lactobacilli could be effectively used in delivering antibodies against *P.gingivalis*. This type of approach, together with the 'innate' immunomodulatory effects of probiotics, might offer interesting prospects in the future.

### Probiotics and periodontal disease

Periodontal disease are a group of diseases that affect the tissues that support and anchor the teeth. Treatment of periodontal diseases in recent years has moved towards an antibiotic/antimicrobial model of disease management. Probiotics might be a promising area of research in the treatment of periodontitis.

Narva and associates<sup>14</sup> have shown that during the fermentation process in milk, *L. helveticus* produces short peptides that act on osteoblasts and increases their activity in bone formation. These bioactive peptides could thereby contribute to reducing the bone resorption associated with periodontitis.

A study done by Klais et al<sup>15</sup> showed that the prevalence of Lactobacilli, particularly *Lactobacillus gasseri* and *L. fermentum*, in the oral cavity was greater among healthy participants than among patients with chronic periodontitis. Various studies have reported the capacity of lactobacilli to inhibit the growth of periodontopathogens, including *P.gingivalis*, *Prevotella intermedia* and *A. actinomycetemcomitans*. These observations suggest that lactobacilli residing in the oral cavity could play a role in the oral ecological balance.

Krasse and colleagues<sup>16</sup> assessed the beneficial effect of *L. reuteri* against gingivitis. After 14 days of ingesting the probiotic incorporated into chewing gum, the oral cavity of patients with a moderate to severe form of gingivitis had been colonized by *L. reuteri* and the plaque index had been reduced.

Riccia and colleagues<sup>17</sup> recently studied the anti-inflammatory effects of *L. brevis* in a group of patients with chronic periodontitis. This study showed a significant reduction in salivary levels of PGE2 and MMPs. The authors suggested that the beneficial anti-inflammatory effects of *L.brevis* could be attributed to its capacity to prevent the production of nitric oxide and consequently, the release of PGE2 and the activation of MMPs induced by nitric oxide. However, *L. brevis* may also be antagonistic, leading to a reduction in the quantity of plaque and therefore an improvement in the gingival index.

Teughels et al<sup>18</sup> reported that the subgingival application of a mixture including *S. sanguis*, *S. salivarius* and *S. mitis* after scaling and root planing significantly suppressed the re-colonization of *P.gingivalis* and *P. intermedia* in beagle dog model. This guided pocket recolonization approach may provide a valuable addition or alternative to the armamentarium of treatment options for periodontitis.

Sunstar (Etoy, Switzerland)<sup>19</sup> recently began marketing the first probiotic specifically formulated to fight periodontal disease. Gum PerioBalance contains a patented combination of two strains of *L. reuteri* specially selected for their synergistic properties in fighting cariogenic bacteria and periodontopathogens. Each dose of lozenge contains at least 2x10<sup>8</sup> living cells of reuteri. Users are advised to use a lozenge everyday, either after a meal or in the evening after brushing their teeth, to allow the probiotics to spread throughout the oral cavity and attach to the various dental surfaces. Additional studies are required to evaluate the long term effects of using these products.

Yakult's *L. casei* strain Shirota is one of the most studied probiotic strains. Fifty volunteers students were recruited to participate in the study. One group was required to drink 65 ml of Yakult daily, giving a daily probiotic dose of 100 billion bacteria per 100 ml. The other group was given no product to consume at all. After eight weeks of drinking the probiotic milk, the researcher showed that the probiotic was



associated with reduction in elastase activity and matrix metalloproteinases-3 (MMP-3)<sup>20</sup>.

## Conclusion

The oral cavity with a well maintained balance of species and species interactions may be a potential source for health-promoting probiotic bacteria. There is limited evidence supporting some uses of probiotics. Much more scientific knowledge is needed about probiotics, including about their safety and appropriate use. Effects found from one species or strain of probiotics do not necessarily hold true for others, or even for different preparations of the same species or strain. The full potential of probiotic can be realized when their benefits can be established scientifically.

## Bibliography

1. Food and Health Agricultural Organization of the U.N. and W.H.O. Guidelines for the evaluation of Probiotics in Food. 2002.
2. Hull RR, Roberts AV, Mayes JJ. Survival of Lactobacillus acidophilus in yogurt. Aust. J. Dairy Technol. 1984;39:164-6
3. Holcomb JE et al. Viability of Lactobacillus acidophilus and Bifidobacterium bifidum in soft serve frozen yogurt. Cult. Dairy Prod. J. 1991;26:4-5.
4. Parvez S, Malik KA, Kim HY. Probiotics and their fermented food products are beneficial for health. J Appl Microbiol. 2006; 100(6):1171-85
5. Reid G, Jass J, Sebelsky MT, McCormick JK. Potential uses of probiotics in clinical practice. Clin Microbiol Rev. 2003;16(4):658-72.
6. Meuman JH. Probiotics: do they have a role in oral medicine and dentistry? Eur J Oral Sci. 2005;113(3): 188-96.
7. Erickson KL, Hubbard NE. Probiotic immunomodulation in health and disease. J Nutr. 2000;130(2S suppl): 403S-409S.
8. Haukioja A, Ouwenhand AC, Meurman JH, Tenova J. Oral adhesion and survival of probiotic and other lactobacilli and bifidobacterium in vitro. Oral Microbiol Immunol 2006;21:326-332.
9. Collado MC, Surono I, Meriluoto J, Salminen S. Indeginous lactic acid bacteria: cell-surface properties and interactions with pathogens. J Food Sci 2007;72:M89-M93.
10. Sookkhee S, Chulasini M, Prachybreud W. Lactic acid bacteria from healthy oral cavity of Thai volunteers: Inhibition of oral pathogens. J Appl Microbiol. 2001;90(2):172-9.
11. Kang MS, Kim BG, Chung J, Lee HC, Oh JS. Inhibitory effect of Weissella cibaria isolates on the production of volatile sulphur compounds. J Clin Periodontol. 2006;33(3):226-32.
12. Srinonnu S. et al. Weissellicin 110, a newly discovered bacteriocin from Weissella cibaria 110, isolated from plaasom, a fermented fish product from Thailand. Appl Environ Microbiol. 2007;73(7):2247-50
13. Marcotte H, Koll-Klais, Hultberg A, Zhao Y. Expression of single-chain antibody against RgpA protease of Porphyromonas gingivalis in Lactobacillus. J Appl Microbiol 2005;100:256-263.
14. Narva H, Hallen J, Vaanamen K, Korpela R. Effects of Lactobacillus helveticus fermented milk on bone cells in vitro. Life Sci. 2004;75(14):1727-34.
15. Koll-Klais P, Mandar R, Leibur E, Marcotte H. Oral lactobacilli in chronic periodontitis and periodontal health: species composition and antimicrobial activity. Oral Microbiol Immunol. 2005;20(6):354-61.
16. Krasse P, Carlsson B, Dahl C, Paulsson A. Decreased gum bleeding and reduced gingivitis by the probiotic Lactobacillus reuteri. Swed Dent J. 2006;30(2):55-60.
17. Riccia DN, Bizzi F, Perilli MG, Polimeni A, Trinchieri V, Amicosante G. Anti-inflammatory effects of Lactobacillus brevis on periodontal disease. Oral Dis. 2007;13(4):376-85.
18. Teughels W et al. Guiding Periodontal Pocket Recolonization: a proof of concept. J of Dent Res. 2007;86(11):1078-82.
19. Gum PerioBalance™ tablets and chewing gum oral health. The European Food Safety Authority Journal 2009;1-8.
20. Staab B, Eick S, Knofler G, Jentsch H. The influence of a probiotic milk drink on the development of gingivitis: a pilot study. Journal of Clinical Periodontology 2009;36(10):850-56.

# "FEEL THE GOLDEN TOUCH....."



43<sup>rd</sup>  
kerala state dental conference  
November 26,27,28 MANJERI  
V P INTERNATIONAL CONVENTION CENTRE

**Mida's Touch Office: 33/182, Arukizhaya Bypass,  
Manjeri- 676 121, Malappuram, Kerala, India**

**Tel: Off - 092 4945 2010**

**Chairman: Mob - 092 4948 2010**

**Org. Secretary : Mob - 092 4966 2010**

**www.midastouch2010.com**

**E-mail: info@midastouch2010.com**

WITH REGARDS FROM CONFERENCE ORGANIZING  
COMMITTEE, THE MIDA'S TOUCH 2010  
43RD KERALA STATE DENTAL CONFERENCE

## WELCOME TO MANJERI

# Free gingival graft- a novel technique in gingival augmentation – A case report

\* Smrithi Varma, \*\* Ramakrishnan T, \*\*\*Prakash Prabhakaran, \*\*\*\* Seema Jayakrishnan

## ABSTRACT

**Aim:** Gingival augmentation procedures are indicated primarily to increase an insufficient amount of gingiva and sometimes to halt the progression of gingival recession. The aim of this case report is to evaluate the changes in the amount of keratinized tissue and the success and predictability of root coverage and aesthetics obtained with free gingival graft in the treatment of gingival recessions for a period of 6 months.

**Methods:** Free gingival graft was obtained from the palate and secured to the labial surface of the lower central incisors and sutured with anchoring sutures as well as horizontal matrix suture. Clinical parameters such as probing depth, recession height, recession width and clinical attachment level as well as the amount of keratinized tissue were recorded at baseline, one and six months.

**Results:** A clinically significant amount of keratinized tissue that covered the recession was obtained along with a decrease in probing depth, recession height, recession width and an increase in clinical attachment level was seen.

**Conclusion:** Gingival augmentation procedure performed in sites with an absence of attached gingiva associated with recession provided an increase in amount of Keratinized tissue associated with recession reduction over a period of 6 months.

### KEY WORDS

Gingival recession, free gingival graft, root coverage, gingiva.

## Introduction

Gingival recession is a common multifactorial condition associated with anatomical, physiological or pathological factors. This phenomenon is characterized by the apical migration of the gingival margin beyond the cemento-enamel junction thereby exposing the root surface. The exposed root surface may further lead to hypersensitivity and increase the predilection for developing root caries. Therapeutic modalities are aimed at correction of both the esthetic and functional components of gingival recession.<sup>1</sup> A variety of techniques such as pedicle grafts,<sup>2</sup> free gingival autografts<sup>3</sup>, connective tissue grafts<sup>4</sup>, Guided tissue regeneration,<sup>5</sup> etc. have been used for the treatment of gingival recession.

For many years, the presence of an "adequate" amount of gingiva was considered the key stone for the maintenance of periodontal health.<sup>6-9</sup> In an observational study by, Lang and Loe<sup>10</sup> reported that despite the fact that the tooth surfaces were free from plaque, "all surfaces with less than 2.0mm of keratinized gingiva exhibited clinical inflammation and varying amounts of gingival exudates". Other investigators<sup>11-13</sup> failed to find a similar association and

reported that it is possible to maintain healthy marginal tissues, even in areas with a reduced or missing keratinized gingiva.

However the presence of site related conditions, e.g., gingival recession, thin periodontium and root prominence, combined with a reduced or missing amount of attached gingiva, may indicate a gingival augmentation procedure.<sup>14,15</sup> In particular, Serino et al<sup>14</sup> showed that sites with gingival recession should be considered susceptible to additional apical displacement of the soft tissue margin. Based on the existing evidence, the American Academy of periodontology suggested several indications for gingival augmentation procedures: to prevent soft tissue damage in the presence of alveolar bone dehiscence during natural or orthodontic tooth eruption; to halt progressive marginal gingival recession; to improve plaque control and patient comfort around the teeth and implants; and to increase the insufficient dimension of gingiva in conjunction with fixed or removable prosthetic dentistry.<sup>15</sup>

Although Miller et al<sup>16</sup> proposed that FGG is a predictable method of root coverage, the obvious disadvantage of poor color match and donor site morbidity

\*Sr Lecturer, \*\*\* Asso: Prof, \*\*\*\* Reader, Sri Sankara Dental College, Trivandrum.

\*\*Professor, Meenakshi Ammal Dental College, Chennai.



Figure 1. Customised Palatal stent

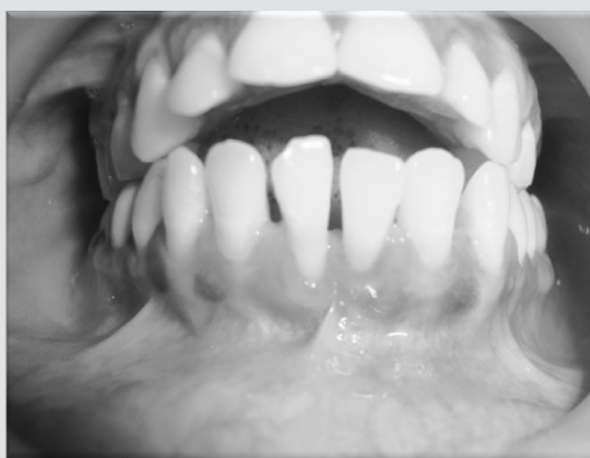

Figure 2. Preoperative view of tooth#41 & 31

render it unsuitable for use as root coverage procedures. However even the advent of SCTG and allogeneous grafts like Alloderm, FGG continues to be the most predictable method to increase the apico-coronal dimension of keratinized mucosa.<sup>17</sup> Some studies reported short or medium term data dealing with the stability of the gingival margin after free gingival graft procedures. Dorfman et al<sup>18</sup> in a split mouth study, treated 22 subjects with a free gingival graft procedures. The four year comparison between control untreated sites and test sites revealed a significant differences in the amount of keratinized tissue, attached gingiva and recession; no other differences were observed. The same results were reported by Kennedy et al<sup>19</sup> in a subgroup analysis of 14 subjects after 6 years and in another study by Hangorsky and Bissada.<sup>20</sup>

### Case report

A 36 year old female patient was referred to the department of periodontology for evaluation of gingival recession associated with lower central incisors. She was in good physical health and with no history of systemic disease. The patient had Millers class II gingival recession with inadequate width of keratinized gingiva of the offending tooth.

The patient was placed on phase I therapy, including a fastidious oral hygiene program, scaling and root planing and oral hygiene instructions till the patient achieved a full mouth plaque score of less than 25 %. Prior to the surgery the selected site presented a healthy periodontium with the gingiva exhibiting no evidence of bleeding on probing. The following measurements were taken at the mid-buccal aspect of the tooth at baseline, 1 month and 6 months post surgery.

Probing pocket depth (PD) was measured with a standard periodontal probe to the nearest millimeter from the gingival margin to the bottom of the gingival sulcus.

Clinical attachment level (CAL) was measured from the CEJ to the bottom of the gingival sulcus.

Recession depth (RD) was measured from the CEJ to the gingival margin.

Recession width (RW) was measured across the buccal surface at the CEJ level.

Clinical evaluation revealed:

	41	31
Recession height	5mm	3mm
Recession width	3mm	3mm
Probing depth	2mm	1mm
Clinical attachment level	7mm	4mm

### Surgical procedure

The recipient site was prepared by the horizontal papillary incisions made at right angles to the papilla at the level of the CEJ.

Two vertical incisions were made from the cut gingival margin to the alveolar mucosa. A split thickness flap was separated without disturbing the periosteum at the recipient site. An aluminium foil template of the recipient was made and placed over the donor site in the palate. The graft was harvested from the palate with a thickness of approximately of 1.5mm. The harvested FGG was then placed at the recipient site and sutured at the lateral borders and to the periosteum. Coe pack was placed at the donor site and over the graft. A palatal stent was prepared and placed.

### Post operative care

The patient was advised not to brush the treated site for 4 weeks. 12% of chlorhexidine rinse was prescribed for twice a day for 4 weeks. Analgesics were administered as needed. The patient was examined weekly for the first month and then once a month for the next 3 months. They were seen at 3 months intervals for oral hygiene instructions and supragingival scaling until the end of the study period.

### Discussion

First described by Bjorn (1963)<sup>21</sup> free gingival grafts have been widely used in the treatment of certain mucogingival problems like lack of attached gingiva and gingival recession. By using this technique, attached gingiva can be increased in a very predictable way. Furthermore, the results obtained using this procedure have been reported to be stable.<sup>22</sup> Although gingival grafting is a procedure with few clinical complications, excessive haemorrhage of the donor area, failure in the graft union, delay in healing and esthetic



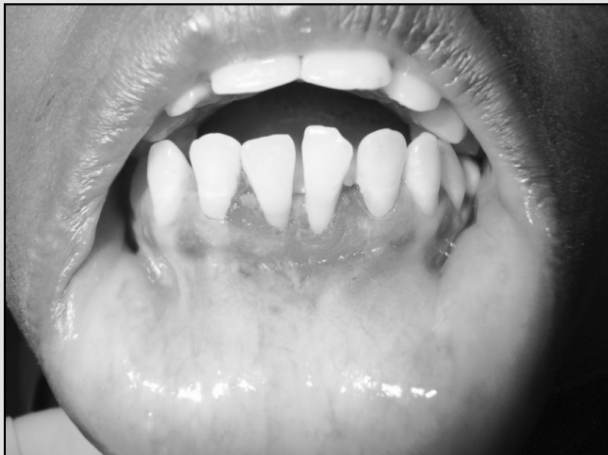

Figure 3. The recipient site is de-epithelialized

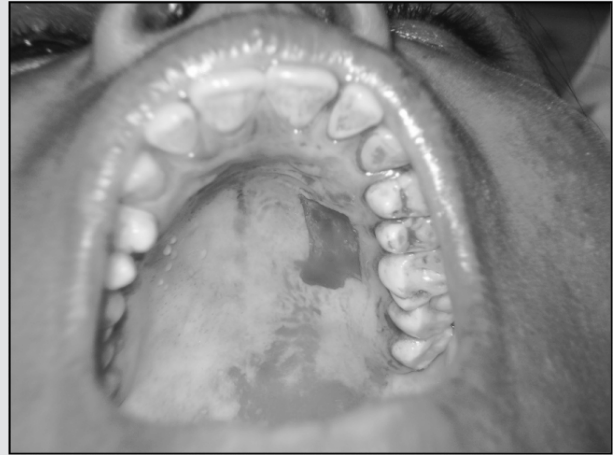

Figure 4. The site from where the graft is harvested

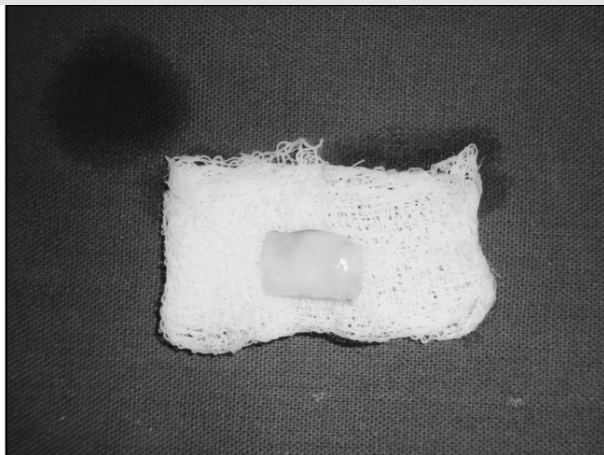


Figure 5. The free gingival Graft harvested

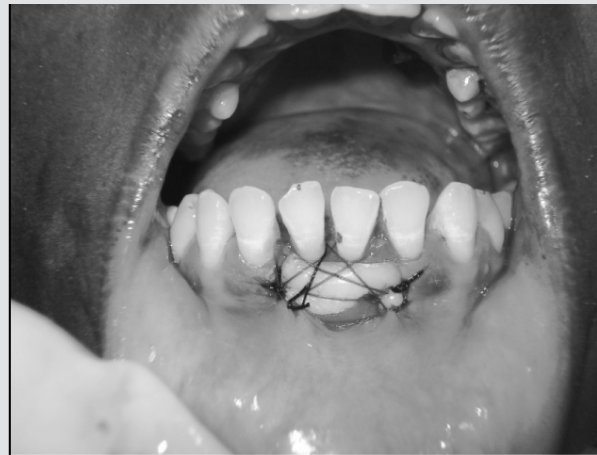


Figure 6. The Graft is sutured at the recipient site

alterations due to disparity in the colour of the palatal gingiva with respect to the grafted area, have been described<sup>23</sup>. In addition, a few reports of exostoses developing after the placement of a free gingival graft have also been published.<sup>24,25,26</sup>

In spite of these disadvantages, it has certain advantages such as it can be used to treat multiple teeth at the same time, simplicity, predictability and can be performed when the keratinized gingiva adjacent to the involved area is insufficient.

Gingival augmentation procedures were performed by placing free gingival grafts at the marginal or sub marginal gingival level. Root coverage was not the immediate and primary goal of these procedures.

This case report presented here shows that gingival margin has shifted coronally 6 months after surgery. This modality of healing probably is attributed to the so called "Creeping attachment" that sometimes occurs after positioning of free gingival grafts. This phenomenon is a "post operative migration of the gingival margin tissue in a coronal direction over portions of a previously denuded root"<sup>27</sup>. Some studies<sup>28</sup> have reported that creeping

attachment took place between 1 month and 1 year after surgery.

The goal of the therapy is functional to a large extent than cosmetic. Free gingival autograft was used in this study in preference to connective tissue grafts for the following reasons.

1. It is more successful in increasing the apico-coronal width of keratinized mucosa.
2. The establishment of a band of keratinized mucosa even if narrow may expected even with narrow partial coverage, may prolong the longevity of the tooth.
3. A shallow palatal vault such as that observed in thin phenotype population may not be ideal for procuring a connective tissue graft.

In a study done by Giancarlo Agudio et al (2008) has shown that FGG done in sites with absence of attached gingiva associated with recessions provide an increased amount of KT and recession reduction over a long period of time.

Remya V et al (2009) have showed that only 50 % of root coverage was possible in class III recession but it contributed to an overall improvement in periodontal health.



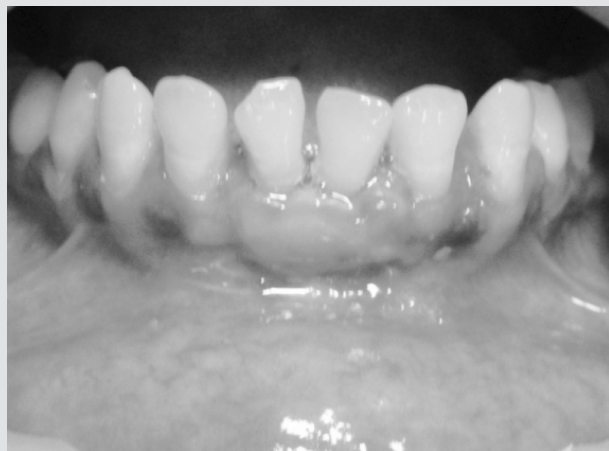

Figure 7. 1 week Post operative

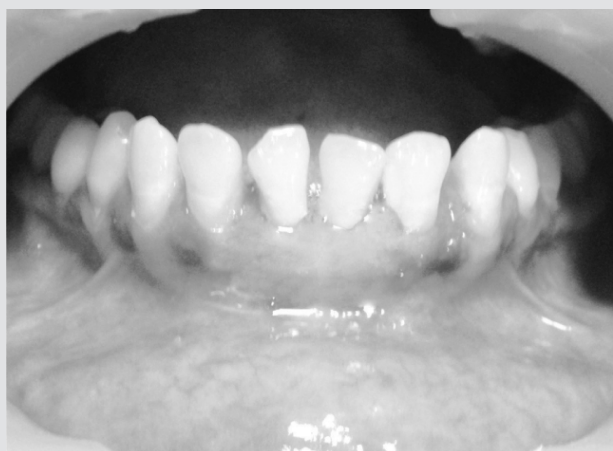

Figure 8. 3month Post operative

## Conclusion

At present, even though the autogenous free gingival grafts are considered inferior to the already proven gold standard the subepithelial connective tissue grafts as far as root coverage is concerned, but their effectiveness in increasing the apico-coronal dimension of gingiva cannot be underestimated as well as the other advantages such as less invasive and easy tissue handling. In conclusion, if performed using certain innovative designs and suitable suturing techniques and good adaptability, it would ensure predictable root coverage and an increase in apico-coronal dimension of gingiva.

## References

- Allen EP. Use of mucogingival surgical procedures to enhance esthetics. *Dent Clin North Am*, 1988; 32:307-30.
- Grube J, Warren R. Repair of a gingival defect by a sliding flap operation. *J Periodontol* 1956; 27:290-5.
- Muller HP, Eger T, Schorb A. Gingival dimensions after root coverage with free connective tissue grafts. *J Clin Periodontol* 1998; 25:424-30.
- Langer B, Langer L. Subepithelial connective tissue graft technique for root coverage. *J Periodontol* 1985; 56:715-20.
- Pini Prato GP, Tinti C, Vincenzi G, Magnani C, Cortellini P, Clauser C. Guided tissue regeneration versus mucogingival surgery in the treatment of human buccal gingival recession. *J Periodontol* 1992; 63:919-28.
- Nabers C.L. Repositioning the attached gingiva. *J Periodontol* 1954; 25:38-39.
- Ochsenbein C. Newer concept of mucogingival surgery. *J Periodontol* 1960; 31:175-185.
- Freidman L, Levine HL. Mucogingival surgery: Current status. *J Periodontol* 1964; 35:5-21.
- Carranza FA, Carraro JJ. Mucogingival techniques in periodontal surgery. *J Periodontol* 1970; 41:294-299.
- Lang NP, Loe H. The relationship between the width of keratinized gingiva and gingival health. *J Periodontol* 1992; 43:623-7.
- Miyasato M, Crigger M, Egelberg J. Gingival condition in areas of minimal and appreciable width of keratinized gingiva. *J Clin Periodontol* 1977; 4:200-9.
- Wennstrom JL, Lindhe J. The role of attached gingiva for maintenance of periodontal health. Healing following excisional and grafting procedures in dog. *J Clin Periodontol* 1983; 10:206-221.
- Wennstrom JL, Lindhe J. Plaque-induced gingival inflammation in the absence of attached gingiva in dogs. *J Clin Periodontol* 1983; 10:266-276.
- Serino G, Wennstrom JL, Lindhe J, Eneroth L. The prevalence and distribution of gingival recession in subjects with a high standard of oral hygiene. *J Clin Periodontol* 1994; 1: 702-706.
- Consensus report. Mucogingival therapy. *Ann Periodontol* 1996; 1: 702-706.
- Miller PD Jr. Root coverage using free soft tissue autograft following citric acid application, III: A successful and predictable procedure in areas of deep-wide recession. *Int J Periodontics Restorative Dent* 1985; 5:14-37.
- Harris RJ. Gingival augmentation with an acellular dermal matrix: Human histologic evaluation of a case placement of the graft on periosteum. *Int J Periodontics Restorative Dent* 2004; 24:378-85.
- Dorfman HS, Kennedy JE, Bird WC. Longitudinal evaluation of free autogenous gingival grafts. A four year report. *L Periodontol* 1982; 53: 349-352.
- Kennedy JE, Bird WC, Palcanis KG, Dorfman HS. A longitudinal evaluation of varying width of attached gingiva. *J Clin Periodontol* 1985; 12: 667-675.
- Hangorsky U, Bissada NF. Clinical assessment of free gingival graft effectiveness on the maintenance of periodontal health. *J Periodontol* 1980; 51: 274-278.
- Bi. om: Free transplantation of gingival propria. *Sveriges Tandlarkar Forbunds Tidning* 1963; 22: 684.
- Matter J. Creeping attachment of free gingival grafts. A 5-year follow up study. *J Periodontol* 1980; 51: 681-685.
- Brasher J, Rees T, Boyce W. Complications of grafts of masticatory mucosa. *J Periodontol* 1975; 46: 133-138.
- Pack A, Gaudie W, Jennings A. Bony exostoses as a sequela to free gingival grafting: Two case reports. *J Periodontol* 1991; 62: 269-271.
- Efeoglu A, Demirel K. A further report of bony exostoses occurring as a sequela to free gingival grafts. *Periodontol Clinical Investigations* 1994 16: 20-22.
- Czuzak CA, Tolson GE, Kudryk VI, Hanson BS, Billman MA. Development of exostoses following a free gingival graft: Case report. *J Periodontol* 1996; 67: 250-253.
- Matter J. Creeping attachment of the free gingival grafts. A five year follow-up study. *J Periodontol* 1980; 51:681-685.
- Borghetti A, Gardella JP. A thick gingival autograft for the coverage of gingival recession. A clinical evaluation. *Int J Periodontics Restorative dent*. 1990; 10:216-229.

# Wonders of non-surgical one stage full mouth disinfection therapy & gingival depigmentation by scalpel method – a case report

\* Samarjeet J Pattnaik \*\* Mohan Valiathan \*\*\* S.C. Chandrasekaran

## ABSTRACT

Chronic inflammatory enlargement due to local factors have been treated by conventional SRP procedures since ages. Here, we have tried to compare the effectiveness of one stage fullmouth disinfection therapy combined with gingival depigmentation by scalpel method in enhancing the gross esthetic look of the patient with regular SRP procedures. The results achieved are encouraging to use this combination technique and incorporate it in our daily clinical practice.

## Introduction

Ø Oral melanin pigmentation is well documented in the literature and is considered to have multifaceted etiologies including genetic factors, tobacco use, systemic disorders and prolonged administration of certain drugs, especially anti-malarial agents and tricyclic anti-depressant.

Ø Melanin pigmentation often occurs in the gingiva as a result of an abnormal deposition of melanin.

Ø This type of pigmentation is symmetric and persistent and it does not alter normal architecture.

Ø This pigmentation may be seen across all races and at any age and it is without gender predilection.

Ø Melanosis of the gingiva is frequently encountered among dark skinned ethnic groups, as well as in medical conditions such as Addison's syndrome, Peutz-jegher's syndrome and von Recklinghausen's disease (neurofibromatosis).

Ø In dark skinned and black individuals, increased melanin production in the skin and oral mucosa has long been known to be result of genetically determined hyperactivity of their skin and mucosal melanocytes.

Ø Earlier studies have shown that no significant difference exists in the density of distribution of melanocytes between light- skinned, dark- skinned and black individuals.

Ø However, melanocytes of dark-skinned and black individual's are uniformly highly reactive, in light-skinned individuals, melanocytes are highly variable in reactivity.

## A case report

A 35 year old female reported to the department of periodontics and implantology, Sree Balaji Dental College,

Chennai, with the chief complaint of swollen gums with profuse bleeding on tooth brushing. On examination, pockets measuring 5 mm of average periodontal pocket depth (PPD) was found. Grade 3 bleeding on probing (BOP) according to papillary bleeding index (PBI), was found on examination. OPG was taken for the patient to detect any underlying osseous defect.

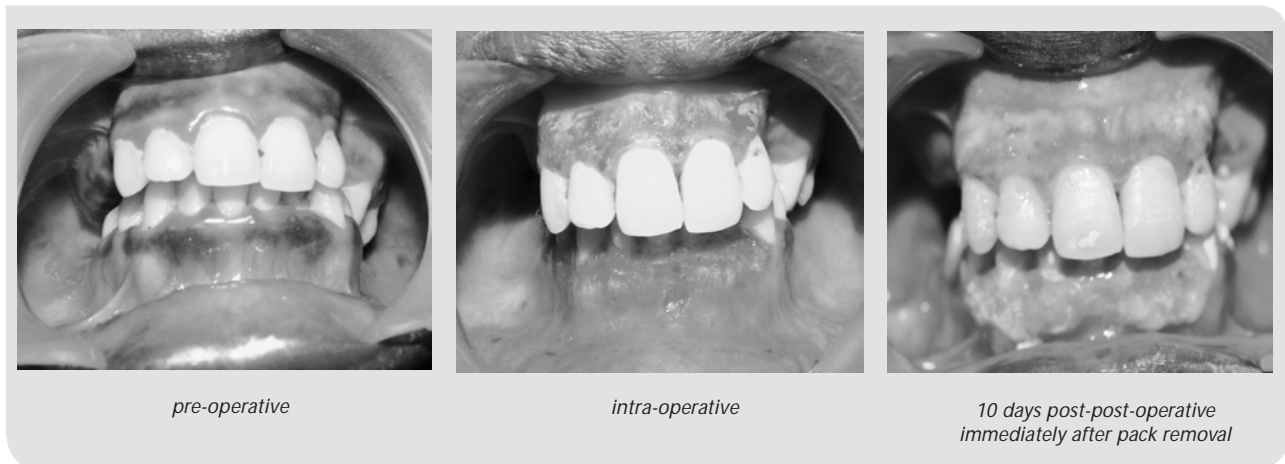Radiological findings indicated no underlying bone loss. Clinically, moderate to severe calculus was found. History of discharge was present. History of extraction was present 5 years and 3 years back, respectively, due to mobility and past periodontal disease activity. Patient was partially edentulous with only anterior teeth remaining in the both arches i.e., 13-23 & 33-43. There was no history of any underlying systemic disorder.

## Treatment plan

A full mouth one stage disinfection (M. Quirynen, 1995) was done in 24 hours by performing subgingival scaling and root planning (SRP) with the help of Gracey curettes 1-2, 3-4, 5-6, 7-8, 11-12, 13-14. Subgingival irrigation was done with chlorhexidine gel (1%), repeated three times in 10 minutes. Tongue cleaning was done with chlorhexidine gel (1%), followed by mouth rising with 0.2% chlorhexidine. Patient was put on supportive periodontal therapy (SPT) and recalled after 6 weeks for re-evaluation. Oral hygiene instructions were reinforced and modified Bass technique was demonstrated before putting the patient on SPT.

Patient reported back after 6 weeks for re-evaluation. On examination, swelling had subsided completely and there

\* Second year PG, \*\* Professor, \*\*\* Prof. & HOD, Dept. of Periodontics, Sree Balaji Dental College & Hospital (SBDC&H), Chennai-100



was no bleeding on probing. The gingiva had completely shrunken and had attained the normal physiological contouring. The consistency was firm and resilient. Patient had maintained amazing oral hygiene, which could be assessed with the visible chlorhexidine stains on the tooth surfaces. A complete supragingival scaling was done. Probing was avoided.

Patient now complained of unesthetic look due to her hyper-pigmented upper and lower labial gingiva. Hence, depigmentation was planned in relation to upper and lower labial gingiva. Patient was put on antibiotic premedication 24 hours before the procedure to prevent any superinfection.

A BP blade no. 15 and BP handle no. 3 were used for the procedure and the pigmented epithelium was scraped off from the underlying connective tissue. A total number of five blades were used to prevent any un-necessary trauma to the gingiva. Due care was taken to preserve the physiological form of the already existing gingiva and interdental papilla. A periodontal dressing (Perio-pak) was placed on the exposed wound for protection and patient comfort on both the upper and the lower labial gingival. Warm saline gargle was advised for initial 3 days at least 4-5 times a day to maintain the isotonicity of the tissues. Patient was recalled after 10 days for pack removal and for assessment of wound healing. Patient was instructed to avoid brushing in the operated area for one month. Chlorhexidine mouthwash (0.2%) was advised for usage for at least 3 weeks to maintain oral prophylaxis.

Multi-vitamin supplements were prescribed for 2 weeks for rapid healing of the wound.

On examination after 10 days, wound healing was uneventual. Patient was put again on supportive maintenance therapy and re-called every month for follow-up. Any rebound of pigmentation of gingiva was also assessed at every appointment. A visual analogue scale (VAS) was used to assess the obtained results periodically.

## Discussion

The importance of optimal plaque control has been illustrated in several studies, reporting the best improvements in patients with the best plaque control (Lindhe et al. 1982, Axelsson et al. 1991, Westfelt et al. 1998, Ximenez-Fyvie et

al. 2000, Checchi et al. 2002).

In patients with severe periodontitis, a one-stage, full-mouth approach will automatically result in an immediate reduction of the microbial load and as such in a delayed de novo plaque formation.

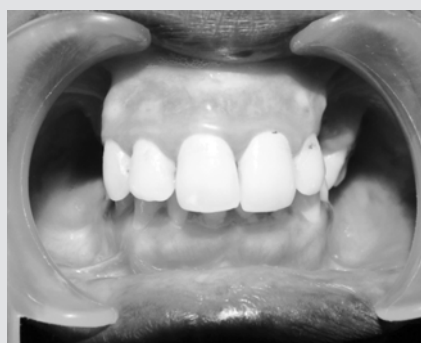The use of the antiseptic will further improve this effect. This beneficial aspect has also been illustrated in several clinical trials examining the impact of repeated supragingival professional cleaning on the subgingival flora (Dahlen et al. 1992, al Yahfoufi et al. 1995, Hellstrom et al. 1996).

The advantage of a one-stage full-mouth disinfection is the reduced probability of an intra-oral transmission of periodontopathogens from one of their niches to the subgingival environment of treated teeth. Indeed, several possible ways have been shown by which such a transmission might occur. Saliva can be considered a major vehicle of transmission (Van Winkelhoff et al., 1988a). Additionally, dental instruments, such as explorers, probes, and syringe tips, as well as oral hygiene material (toothbrushes and dental floss) have the capability of retaining pathogenic micro-organisms (Caufield and Gibbons, 1979; Loesche et al., 1979; Barnett et al., 1982; Christersson et al., 1985; Muller et al., 1989; Preus et al., 1993). The hypothesis that a transmission of micro-organisms is possible has been confirmed in a recent study utilizing titanium abutments as "virgin soil" for the colonization of oral bacteria (Quirynen et al., 1995).

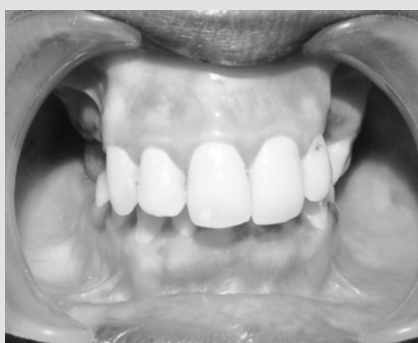The increase in body temperature reported, probably illustrates the important bacteremia during scaling and root planing (Ellen, 1978). Perhaps the increased amount of micro-organisms introduced into the bloodstream and/or the prolonged treatment time (four hours within a single day) over-stimulated the host-defense mechanism.

In conclusion, the one-stage full-mouth disinfection showed significant clinical (pocket reduction) and microbiological (shift toward a more beneficial flora) advantages on a short-term basis.

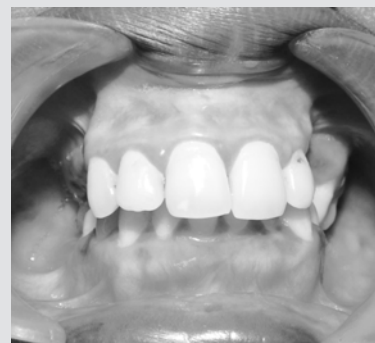Melanin pigmentation is the result of melanin granules produced by melanoblasts, intertwined between epithelial cells at the basal layer of the epithelium. Previous clinical and experimental reports describe the different depigmentation methods. It is known that the healing period



3 month post-operative



6 month postoperative



8 months post-operative.

for scalpel wounds is faster than other techniques; however, scalpel surgery causes unpleasant bleeding during and after the operation and it is necessary to cover the lamina propria with periodontal packs for 7 to 10 days. Electro surgery requires more expertise than scalpel surgery. Prolonged or repeated application of current to tissue induces heat accumulation and undesired tissue destruction. Contact with periosteum or alveolar bone and vital teeth should be avoided.

Cryosurgery is followed by considerable swelling and it is also accompanied by increased soft tissue destruction. Ishida and Silva and Gage & Baust reported that in cryosurgery, all the parts of the freeze-thaw cycle can cause tissue injury and healing is eventful. Depth control is difficult and optimal duration of freezing is not known, but prolonged freezing increases tissue destruction.

The CO<sub>2</sub> laser causes minimal damage to the periosteum and bone under the gingival being treated and it has the unique characteristic of being able to remove a thin layer of epithelium cleanly. Although healing of laser wounds is slower than healing of scalped wounds, laser wound is a sterile inflammatory reaction. Patients frequently report greater postoperative pain after electrosurgery than after laser surgery. However, unlike an electrosurgical wound, a laser wound is not a burn; 10.6 μm photons are experimentally absorbed as a function of amount of water, not as a result of resistance or conduction and CO<sub>2</sub> laser's air cooling function is highly beneficial as well one step laser treatment is sufficient to eliminate the melanotic area. The treated gingivae and mucosae do not need any dressing and reepitheliazation is completed within 2 to 3 weeks.

Surgical removal of portions of pigmented gingiva has been reported by Perlmutter that after surgery, it was necessary to cover the exposed lamina propria with periodontal packs for 7 to 10 days. It took 6 weeks to heal and left a delicate scar, but in our case, there was no scar after healing and healing time was 2-4 weeks. Care should be taken while removing pigmentation in thin gingival tissue, so the alveolar bone should not be exposed. Though cryosurgical or laser therapy modalities achieved satisfactory results, but they required sophisticated equipment that is

not commonly available in hospitals and clinics in developing countries.

Therefore, scalpel surgical technique is highly recommended in consideration of the equipment constrains in developing countries. It is simple, easy to perform, cost effective and above all with minimum discomfort and esthetically acceptable to patient.

## References

1. Liebart ME, Deruelle CF, Santini A, Dillier FL, Corti VM, et al. Smile Line and Periodontium Visibility. *Perio*,1:17-25, 2004.
2. Dummet CO oral pigmentation. In:Dummet CO,editor. First symposium on oral pigmentation. *JPeriodonto*1,31:356-60,1960.
3. Dummett CO, Bolden TE. Postsurgical clinical Repigmentation of the gingiva. *Oral Surg Oral Med Oral Pathol*,16:353-365,1963.
4. Perlmutter S, Tal H. Repigmentation of the gingival following surgical injury. *JPeriodontol*, 57:48-50,1986.
5. Brown, T. Oral pigmentation in Aborigines of Kalumburu, north-west Australia. *Arch Oral Biol.*; 1964;9:555-58.
6. Fry, L. and Almeyda, J.R. The incidence of buccal pigmentation in Caucasoids and Negroids in Britain. *Brit J. Dermatol*, 1968;80:244-48.
7. Axell, T. AndHedin, C. A. Epidemiologic study of excessive oral melanin pigmentation with special reference to the influence of tobacco habits. *Scand J. Dent Res* 1982;90:434-
8. Regezi, J. A. and Sciubba, J. *Oral Pathology, Clinical Pathologic Correlations*. W. B. Saunders Co., 1993, pp 161. USA.
9. Schroeder, H.E. Melanin containing organelles in cells of the human gingival. I. Epithelial melanocytes. *J. Periodont Res*, 1969;4:1-3.
10. ShaferWG, HineMK, LevyBM. *A Textbook of Oral Pathology*. Philadelphia: W.B.Saunders Co.;1984;pp.89-136.
11. Quirynen M, De Soete M, Boschmans G, Pauwels M, Coucke W, Teughels Wvan Steenberghe D. Benefit of "one-stage, full-mouth disinfection" is explained by disinfection and root planing within 24 hours: a randomized controlled trial. *J Clin Periodontol* 2006; 33: 639-647.
12. Full- vs. Partial-mouth Disinfection in the Treatment of Periodontal Infections: Short-term Clinical and Microbiological Observations, M. Quirynen, C.M.L. Bollen, B.N.A. Vandekerckhove, C. Dekeyser, W. Papaioannou, and H. Eysen, *J Dent Res* 74(8): 1459-1467, August, 1995.



# Correlation between Obesity, Diabetes Mellitus and Periodontal Disease in Adults- a clinical and biochemical study

\* Biju Thomas, \*\* Sunaina Shetty Y., \*\*\* Suchetha Kumari

## ABSTRACT

**Aims and objectives:** Obesity has been implicated as a risk factor for several chronic health conditions. Recent studies have reported a relationship between obesity and periodontitis. The purpose of the present study was to assess the relationship between obesity, type 2 diabetes mellitus and periodontal disease.

**Materials and Methods:** A systematic random sample of 40 persons aged between 30 and 70 years with at least twenty teeth were selected for this study and were divided into four groups. Body mass index, waist-hip ratio, body fat, random blood sugar were measured. All subjects underwent periodontal examination. Periodontitis was defined as clinical attachment loss more than 4mm.

**Results and Conclusions:** The result of this study shows that obesity is significantly associated with periodontal disease even in the subjects with normal blood glucose level. Although this relationship needs further investigation, periodontists should counsel obese persons regarding the possible oral complications of obesity, to diminish morbidity for these individuals.

## Introduction

Obesity is the fastest growing health related problem in the world<sup>1</sup>. The prevalence of obesity has increased substantially over the past decades in industrialized countries. Obesity is a systemic disease that predisposes to a various co-morbidities and complications that affect overall health<sup>2</sup>.

Obesity, a common metabolic and nutritional disorder, is a complex multi factorial chronic disease that develops from an interaction of genotype and the environment<sup>3</sup>. Overweight and obese adults are considered to be at high risk of hypertension, type-2 diabetes, high blood cholesterol, coronary heart disease and other life threatening diseases. Recent studies documented the important role of nutritional status in periodontal disease<sup>4,5</sup> and showed that obesity could be a potential risk factor for periodontal disease<sup>6,7</sup>. Through its impact on metabolic and immune parameters, obesity may increase the host's susceptibility to periodontal disease<sup>8,9</sup>. The relationship between obesity and type 2 diabetes is particularly close. Obese persons have a more than 10-fold increased risk of developing type 2 diabetes compared with normal-weight persons<sup>8</sup>. Type-2 diabetes develops due to an interaction between insulin resistance and beta cell failure. Several factors, including lipo-toxicity and glucose toxicity as well as obesity-derived cytokines,

have been implicated in these processes<sup>2</sup>.

Since adiposity can be considered as a systemic disease that predisposes to a variety of co-morbidities and complications that affect overall health, obese persons require awareness across the spectrum of health professionals, including dentists. In fact, the adipose tissue secretes several cytokines and hormones that are involved in inflammatory processes, suggesting that similar pathways are involved in the patho-physiology of obesity, type-2 diabetes and periodontitis<sup>2</sup>. The present study was undertaken to assess the relationship between obesity, type 2 diabetes mellitus and periodontal disease.

## Materials and methods

### Source of Data

Ten subjects who are diabetic, obese with periodontitis; ten subjects who are non diabetic, obese with periodontitis; ten subjects who are diabetic, non-obese with periodontitis and ten subjects who are non diabetic, non-obese with periodontitis were selected from a total of 864 patients. Selection criteria included were as follows:

1. Subjects with a minimum complement of 20 teeth.
2. Patients with chronic periodontitis with more than 4mm of clinical attachment loss.

\* Professor and HOD, \*\* Post Graduate Student, Dept. of Periodontics, AB Shetty Memorial Institute of Dental Sciences, Deralakatte, Mangalore

\*\*\*\* Professor, Dept. of Biochemistry, AB Shetty Memorial Institute of Dental Sciences, Deralakatte, Mangalore

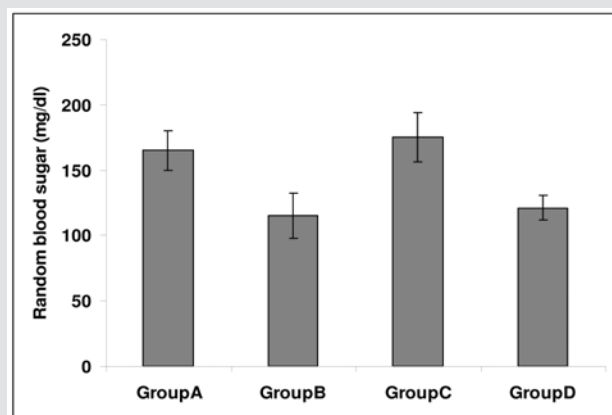


Figure 1. Comparison of Random Blood Sugar (mean ± SD) across the Groups.

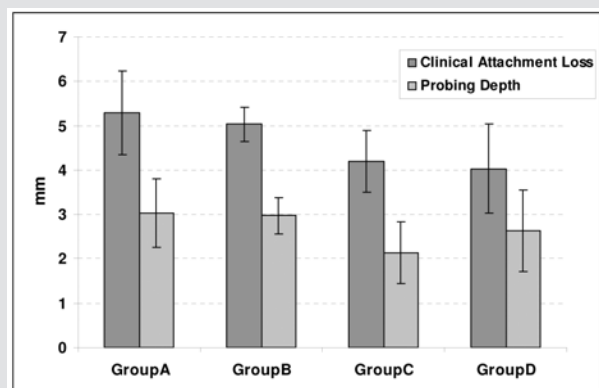


Figure 2. Comparison of Clinical Attachment Loss and Probing Depth (mean ± SD) across the Groups.

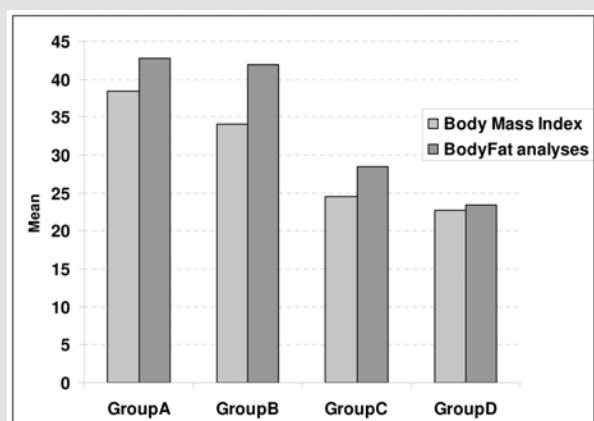


Figure 3. Comparison of Body Mass Index and Body Fat analyses (mean) across the groups.

3. Bleeding on probing in at least 30% of teeth.
  4. Subjects with random blood sugar more than 200mg/dl.
  5. Subjects with BMI more than 30kg/m<sup>2</sup>.
- Subjects diagnosed with malignancy and osteoporosis, pregnant women, lactating women, women in their

menstrual phase and currently on antibiotics, steroids or hormonal therapy were not included for the study.

### Methodology

A total of 864 patients reporting to the department of Periodontics between age 30 and 70 yrs were screened for presence of periodontitis, diabetes 2, and obesity. Each patient was asked to sit comfortably on a dental chair. A detail medical and dental history was recorded. A periodontal examination was performed on two randomly selected quadrants (one maxillary and one mandibular). Clinical attachment loss and periodontal probing depth were also recorded.

5ml of venous blood sample was collected from the subjects and was sent to central research laboratory to assess random blood sugar level.

Anthropometric measurements including weight, height, hip circumferences (HC) and waist (WC) were measured with the subjects wearing light clothing and no shoes. Height was measured using measuring rod and body weight was measured using mechanical flat scale. WC and HC were measured using circumference measuring tape. WC was measured to the nearest centimetre at the narrowest point between the umbilicus and the rib cage. The hip circumference was measured around the buttocks 4cm below the anterior superior iliac spine. Waist hip ratio (WHR) was calculated as the ratio of WC to HC. As a measure of obesity, two indexes were used. Body mass index (the weight in kilograms divided by the square of height in meters) and waist hip ratio were calculated. The body fat of the subjects was measured using a Body Fat Analyzer.

All the patients were informed regarding the nature of the study. Among 864 patients, ten subjects who are diabetic, obese with periodontitis were selected and assigned to Group A. Ten subjects who are non diabetic, obese with periodontitis were assigned to Group B. Ten subjects who are diabetic, non-obese with periodontitis were assigned to Group C and ten subjects who are non diabetic, non-obese with periodontitis were selected as control and assigned to Group D.

Anthropometric measurements, periodontal status, random blood sugar level was recorded and tabulated.

### Statistical analysis

Data was statistically analysed by one way ANOVA was used to compare various parameters between the groups. Statistical Software SPSS17 was used to analyse the data.

### Results

Mean age for the Group A, Group B, Group C and Group D (N=10 each) were found to be 39.3± 7.97, 47.8 ± 11.17, 42.9± 8.42 and 44.0± 6.37 years respectively and this difference was not found to be significant (Table I).

### Comparison of clinical attachment loss and mean probing depth between the groups (Table II; Fig 1)

A significant relation was found between clinical attachment loss (mm) and obesity, diabetes and periodontitis with a p-value of 0.002 and standard deviation of 0.94 across the groups. However the mean probing depth when compared across the group was not statistically significant.

**Comparison of random blood sugar, body mass index, waist hip ratio and body fat analysis across the groups (Table III)**

**Random Blood Sugar (Fig 2)**

The mean random blood sugar in the patients in Group A, Group B, Group C and Group D (N=10 each) were found to be 164.97± 15.16; 115.28 ± 17.03; 175.34± 18.84 and 121.05± 9.55 mg/dl respectively. This difference was found to be statistically significant (p<0.005).

**Body Mass Index (BMI) and Body Fat Analyses (Fig 3)**

The body mass index and body fat analyses were measured for all the groups. The difference was found to be statistically significant (p<0.005) when compared across the group.

**Waist and Hip Ratio**

However, the mean waist hip ratio when compared across the group showed no statistical significance (p=0.691).

**Discussion**

It has been reported that the prevalence of periodontal disease is 76% higher among young obese (body mass index ≥30 kg/m<sup>2</sup>) individuals aged 18–34 years than in normal-weight individuals<sup>10</sup> and that weight is associated with increased risk of periodontitis among those aged 17–21 years<sup>11</sup>. In the present study, a higher body mass index was associated with increased risk of periodontitis.

An increase in body mass index may therefore be a potential risk factor for periodontitis, even among young individuals (i.e. in those with a body mass index of <30kg/m<sup>2</sup>). Body mass index has been widely used to assess general body composition. It increases with age<sup>12-14</sup>, and children aged 7–15 years with normal body mass index may become overweight or obese adults (body mass index >25)<sup>15</sup>. In young subjects with a normal body mass index, prospective morbidity is dependent on body mass index as well as on age<sup>14</sup>, and maintenance of body mass index at the level at which it is present during adolescence is an important factor in preventing future disease.

Obesity is likely an independent risk factor for hypertension, coronary heart disease, osteoarthritis, and, in particular, type 2 diabetes<sup>16</sup>. As BMI increases, so does the risk and prevalence of these co-morbidities<sup>17</sup>. BMI was the most important independent predictor of the risk of diabetes mellitus in the Nurses Health Study<sup>18,26</sup>. The risk of diabetes in women increased 5-fold for those with BMI of 25 kg/m<sup>2</sup>, 28-fold for those of BMI of 30 kg/m<sup>2</sup>, and 93-fold for those of BMI >35 kg/m<sup>2</sup> compared to women with BMI of less than 21<sup>18</sup>. The distribution of fat tissue is also an independent predictor of diabetes mellitus. Abdominal obesity (waist circumference of >40 inches) increases the risk of diabetes 3.5-fold after controlling for BMI<sup>19</sup>. The risk of periodontitis increased 3-fold in Japanese individuals with BMI 25 to 29.9 kg/m<sup>2</sup> and 8.6 for those with BMI ≥30 kg/m<sup>2</sup> compared to those with BMI ≤ 20 kg/m<sup>2</sup> after adjustment for age, gender, oral hygiene status, and smoking history<sup>20</sup>. In a manner similar to the risk for diabetes mellitus, the increased risk for periodontal disease was especially significant in individuals with upper body obesity; i.e. high waist-hip ratios<sup>20</sup>.

Table I. Comparison of mean age between various groups

	N	Mean	Std. Deviation
Group A	10	39.3	7.97
Group B	10	47.8	11.17
Group C	10	42.9	8.42
Group D	10	44.0	6.37
Total	40		

F=1.633, p=0.199 ns

Table II. Comparison of clinical attachment loss and mean probing depth between the groups.

		N	Mean	Standard Deviation	P
Clinical Attachment Loss (mm)	GroupA	10	5.2910	.94524	0.002*
	GroupB	10	5.0280	.38055	
	GroupC	10	4.1970	.70445	
	GroupD	10	4.0260	1.00094	
Mean Probing Depth (mm)	GroupA	10	3.0260	.76368	0.052 NS
	GroupB	10	2.9670	.40078	
	GroupC	10	2.1340	.68669	
	GroupD	10	2.6300	.92262	

\* Significant, NS - Non Significant

Table III. Comparison of random blood sugar, body mass index, waist hip ratio and body fat analysis across the groups.

		N	Mean	Standard Deviation	P
Random Blood Sugar (mg/dl)	GroupA	10	164.97	15.16	<.0005*
	GroupB	10	115.28	17.03	
	GroupC	10	175.34	18.84	
	GroupD	10	121.05	9.55	
Body Mass Index	GroupA	10	38.39	1.80	<0.0005*
	GroupB	10	34.11	2.43	
	GroupC	10	24.52	2.23	
	GroupD	10	22.64	2.60	
Waist and Hip Ratio (inches)	GroupA	10	0.90	0.00	0.691
	GroupB	10	0.90	0.00	
	GroupC	10	0.88	0.07	
	GroupD	10	0.91	0.05	
Body Fat Analyses (%)	GroupA	10	42.70	1.96	<0.0005*
	GroupB	10	41.97	3.95	
	GroupC	10	28.46	4.38	
	GroupD	10	23.48	9.08	

\* Significant

Obesity in general has been known to lower insulin sensitivity. In addition, distribution of body fat influences glucose metabolism through independent and additive mechanisms. Abdominal obesity is especially associated with

an increase in the glucose and insulin response to an oral glucose challenge<sup>16</sup>. Upper body obesity is associated with a decrease in the uptake of insulin by the liver, increased hepatic gluconeogenesis, systemic dyslipidemia, and insulin resistance. Abdominal adipocytes contribute to increased release of free fatty acids (FFA), resulting in elevation of triglycerides<sup>21</sup>. Increased plasma FFAs lead to further increase in hepatic gluconeogenesis and increased peripheral insulin resistance with down regulation of insulin receptors. Links between dyslipidemia and periodontal disease have been proposed by investigators who propose that there is a link between elevated triglycerides and inflammatory heparin responsiveness which results in enhanced periodontal disease<sup>22,23</sup>.

A proposed model linking inflammation to obesity, diabetes, and periodontal infection is presented by Genco et al<sup>8</sup>. Dietary free fatty acids contribute to obesity, as well as to insulin resistance by enhancing apoptosis of b-cells of the pancreas. Adipocytes produce pro-inflammatory cytokines such as TNF- $\alpha$ , which in turn appear to contribute to insulin resistance by inhibiting insulin signaling<sup>24</sup>. Insulin resistance is a pathologic process which is a critical feature of type 2 diabetes mellitus. Diabetes also contributes to a hyper inflammatory state through production of advanced glycation end products (AGE) of proteins which trigger monocyte/macrophage and cytokine production through interaction with receptors for AGE. This higher inflammatory state then sets the stage for increased levels of periodontal disease triggered by oral pathogens. The precise nature of the molecular inter-actions of inflammatory cytokines with obesity, diabetes, and infections such as periodontal disease is not clear. However, it is hoped that this and other models suggest experimental approaches to clarify these mechanisms<sup>8</sup>.

Results from our study suggesting periodontal disease as another co-morbidity associated with obesity is of potential public health relevance. Evidence is rapidly mounting supporting periodontal disease as an independent risk for CHD and as an aggravating factor for diabetes mellitus and cardiovascular and nephropathy complications of diabetics. The presence of periodontal infection in obese individuals may be an important factor precipitating the clinical outcome of type 2 diabetes and its complications, as well as CHD in non-diabetics.

Intervention and preventive approaches may ultimately lead to amelioration of the significant health burden associated with these diseases.

## Conclusion

Obesity is a complex disease, and its relationship to oral status has been realized by the scientific community in recent years. Although this relationship needs further investigation, periodontists should counsel obese persons regarding the possible oral complications of obesity, to diminish morbidity for these individuals.

## References

1. Haenle M, Brockmann S, Kron M, Bertling U, Mason R, Steinbach G. Overweight, physical activity, tobacco and alcohol consumption in a cross-sectional random sample of German adults. *BMC Public Health* 2006; 6: 233.
2. Pischon N, Heng N, Bernimoulin JP, Kleber BM, Willich SN, Pischon T. Obesity, Inflammation, and Periodontal Disease.

- Journal of Dental Research. 2007; 86(5):400-409.
3. Dennison E, Syddall H, Aihie Sayer A, Martin H, Cooper C. Hertfordshire Cohort Study Group. Lipid profile, obesity and bone mineral density: the Hertfordshire Cohort Study. *Quarterly Journal of Medicine*. 2007; 100: 297–303.
4. Boyd D, Madden E. Nutrition, infection, and periodontal disease. *Dental Clinics of North America* 2003; 47: 337–354.
5. Schifferle E. Nutrition and periodontal disease. *Dental Clinics of North America* 2005; 49: 595–610.
6. Saito T, Shimazaki Y, Kiyohara Y, Kato I, Kubo M, Iida M, Yamashita Y. Relationship between obesity, glucose tolerance, & periodontal disease in Japanese women: the Hisayama study. *Journal of Periodontal Research* 2005; 40: 346–353.
7. Chapper A, Munch A, Schermann C, Piacentini C, Fasolo T. Obesity and periodontal disease in diabetic pregnant women. *Pesquisa Odontologica Brasileira* 2005; 19: 83–87.
8. Genco R, Grossi S, Ho A, Nishimura F, Murayama Y. A proposed model linking inflammation to obesity, diabetes, and periodontal infections. *Journal of Periodontology* 2005; 76: 2075–2084.
9. Nishimura F, Murayama Y. Periodontal inflammation and insulin resistance lessons from obesity. *Journal of Dental Research* 2001;80:1690–1694.
10. Al-Zahrani MS, Bissada NF, Borawskit EA. Obesity and periodontal disease in young, middle-aged, and older adults. *J Periodontol* 2003; 74:610–615.
11. Reeves AF, Rees JM, Schiff M, Hujoel P. Total body weight and waist circumference associated with chronic periodontitis among adolescents in the United States. *Arch Pediatr Adolesc Med* 2006; 160:894–899.
12. Hediger ML, Hartnett HJ, Louis GM. Association of endometriosis with body size and figure. *Fertil Steril* 2005; 84:1366– 1374.
13. Hypponen E, Power C, Smith GD. Prenatal growth, BMI, and risk of type 2 diabetes by early midlife. *Diabetes Care* 2003; 26:2512–2517.
14. Tobe K, Ogura T, Tsukamoto C, Inoue H, Arata J, Matsuura K. Effect of change in body mass index on morbidity in non- obese university graduates. *Acta Med Okayama* 2002; 56:149–158.
15. Venn AJ, Thomson RJ, Schmidt MD et al. Overweight and obesity from childhood to adulthood: a follow-up of participants in the 1985 Australian schools Health and Fitness Survey. *Med J Aust* 2007; 186:458–460.
16. Calle EE, Thun MJ, Petrelli JM, Rodriguez C, Heath CW Jr. Body mass index and mortality in a prospective cohort of U.S. adults. *N Engl J Med* 1999; 341: 1097-1105.
17. Must A, Spadano J, Coakley EH, Field AE, Colditz GA, Dietz WH. The disease burden associated with overweight and obesity. *JAMA* 1999; 282:1523-1529.
18. Colditz GA, Willett WC, Rotnitzky A, Manson JE. Weight gain as a risk factor for clinical diabetes mellitus in women. *Ann Intern Med* 1995; 122:481-486.
19. Lean MEJ, Hans TS, Seidell JC. Impairment of health and quality of life in people with large waist circumference. *Lancet* 1998; 351:853-856.
20. Saito T, Shimazaki Y, Sakamoto M. Obesity and periodontitis. *N Engl J Med* 1998; 339:482-483.
21. Frayn KN, Williams CM, Arner P. Are increased plasma non-esterified fatty acid concentrations a risk marker for coronary heart disease and other chronic diseases? *Clin Sci* 1996; 90:243-253.
22. Cutler CW, Shinedling EA, Nunn M, et al. Association between periodontitis and hyperlipidemia: Cause or effect? *J Periodontol* 1999; 70:1429-1434.
23. Cutler CW, Machen RL, Jotwani R, Iacopino AM. Heightened gingival inflammation and attachment loss in type 2 diabetes with hyperlipidemia. *J Periodontol* 1999; 70:1313-1321.
24. Liu LS, Spelleken M, Roehrig K, Hauner H, Eckel J. Tumor necrosis factor- $\alpha$  acutely inhibits insulin signaling in human adipocytes: Implications of the p80 tumor necrosis factor receptor. *Diabetes* 1998; 47: 515-522.



# Comparative evaluation of myeloperoxidase levels in healthy individuals and subjects with chronic periodontitis-a biochemical study

\* Biju Thomas, \*\* Mranali Alva, \*\*\* Amitha Ramesh \*\*\*\* Suchetha Kumari,

## ABSTRACT

**Objective of the Study:** To determine the activity of myeloperoxidase in serum and saliva of subjects with chronic periodontitis.

**Materials and methods:** Myeloperoxidase activity is estimated by Malheston et al method and is measured spectrophotometrically at 510nm using 4-amino antipyrine as hydrogen donor. Results of the study were subjected to statistical analysis using students unpaired t test. Comparison of myeloperoxidase level between chronic periodontitis and control group showed a increase in level of myeloperoxidase in chronic periodontitis patients.

**Conclusion:** The results of this study show that the activities of myeloperoxidase enzyme were significantly increased in the serum and saliva of patients with periodontal disease in relation to healthy individuals. Hence the salivary enzymes like myeloperoxidase can be considered as possible biochemical markers of the functional condition of periodontal tissues.

## Introduction

Chronic Periodontitis may be defined as a mixed infection affecting individual or multiple sites within the oral cavity and leading to the loss of the supporting periodontal tissues. This disease is chronic in nature and can persist in the absence of treatment<sup>3</sup>. The micro-organisms of dental plaque have been shown to be capable of initiating the mechanisms of destruction of the periodontal tissues, while their effective control has been shown to be most appropriate means of arresting the progress of periodontal disease.

Myeloperoxidase(MPO) the most abundant protein in neutrophils is the focus of inflammatory pathologies. It is used as biomarker for human cardiovascular disease. Its ability to catalyze reaction between chloride and hydrogen peroxide to form hypochlorous acid is unique among mammalian enzymes and is considered to be the dominant function of MPO in vivo. Hypochlorous acid is a powerful antimicrobial agent and extremely reactive with biological molecules causing much of damage mediated by neutrophils in inflammatory diseases.

## Objective of the study

To determine the activity of myeloperoxidase in serum and saliva of subjects with chronic periodontitis.

## Materials and methods

### STUDY POPULATION

A total of 24 subjects are included in the study

GROUP 1 – Included 12 subjects diagnosed with chronic generalized periodontitis

GROUP 2-Included 12 subjects as healthy controls

### CRITERIA FOR PATIENT SELECTION

#### INCLUSION CRITERIA

1. Moderate to severe periodontitis affecting more than 30% of sites for the test group.
2. Systemically healthy subjects
3. Subjects who have a pocket probing depth of >4mm

#### EXCLUSION CRITERIA

1. History of any systemic disorders like diabetes, hypertension etc
2. Pregnant women are excluded from the study
3. Subjects currently on antibiotic therapy

### DETERMINATION OF MYELOPEROXIDASE ACTIVITY IN SERUM AND SALIVA

#### PRINCIPLE

Myeloperoxidase, a heme containing peroxidase

\* Professor and HOD, \*\* Post Graduate Student, \*\*\* Professor, Dept. of Periodontics, AB Shetty Memorial Institute of Dental Sciences, Deralakatte, Mangalore \*\*\*\* Professor, Dept. of Biochemistry, AB Shetty Memorial Institute of Dental Sciences, Deralakatte, Mangalore

abundantly found in neutrophils enzymatically produces powerful antioxidant (hypochlorous acid) and show antimicrobial activity in tissues. Myeloperoxidase activity is estimated by the MALHESTON et al method and is measured Spectrophotometrically at 510 using 4-aminoantipyrine as hydrogen donor.

**Results**

**Clinical characteristics of study subjects (value are at mean +/-SD)**

Parameters	normal		periodontitis		P value
	Serum	Saliva	Serum	saliva	
Myeloperoxidase	20.310 ±4.685	11.410 ±0.869	59.25 ±16.3	24.14 ±5.57	<0.0001

Table 1: Status of Myeloperoxidase in Serum of Patient with Periodontitis

group	Myeloperoxidase level
normal	20.310±4.685
periodontitis	59.25±16.3

**Discussion**

Diagnosis of periodontal disease relies primarily on clinical (GI,BOP,PD) and radiographic parameters (alveolar bone loss)<sup>7</sup>. These measures are useful in detecting evidence of past disease or verifying periodontal health, but provide only limited information about patients and sites at risk for future periodontal breakdown. Numerous markers in saliva have been proposed as diagnostic tests for periodontal disease such as intracellular enzymes namely myeloperoxidase and lactate dehydrogenase. Their activity can be detected in saliva and blood. Estimation of MPO activity has also been used as an indicator of influx of inflammatory cells in to tissue. MPO has been widely used as an inflammatory marker of both acute and chronic conditions<sup>9</sup>. In our study, we found that the activity of myeloperoxidase significantly increased. During periodontal disease development, a remarkable accumulation of neutrophils recruited from blood vessels can be observed in compromised periodontal tissue. Moreover accumulation of neutrophils is related not only to host response, to bacterial invasion but also to periodontal tissue destruction itself. In

fact our results showed that, myeloperoxidase activity was significantly higher at sites of chronic periodontitis, when compared to that of naïve<sup>2</sup>. Hence myeloperoxidase activity has been used as a good model to estimate neutrophil content in inflamed tissues<sup>2</sup>.

**Conclusion**

The results of this study show that the activities of myeloperoxidase enzyme were significantly increased in serum and saliva of patients with periodontal disease in relation to healthy individuals. Hence the salivary enzymes like myeloperoxidase can be considered as possible biochemical markers of the functional condition of periodontal tissues.

**References**

1. Klebanoff SJ, Waltersdorph AM, Rosen H. Antimicrobial activity of myeloperoxidase. *Methods Enzymol* 1984;105:399–403.
2. CF Cao, Q T Smith. Crevical fluid myeloperoxidase at healthy, gingivitis and periodontitis sites.
3. Mohammad Hossein Salari and Zainab Kadkhoda: Rate of cultivable subgingival periodontopathogenic bacteria in chronic periodontitis. *J.Oral Sci.*46,157-161,2004.
4. Heinecke JW, Li W, Francis GA, Goldstein JA. Tyrosyl radical generated by myeloperoxidase catalyzes the oxidative cross-linking of proteins. *J Clin Invest*1993;91:2866–72.
5. Venge P. The monitoring of inflammation by specific cellular markers. *Scand J Clin Lab Invest Suppl* 1994;219:47–54.
6. Pi-Fen Wei, Kun-Yen Ho myeloperoxidase and interleukin-1b in gingival crevicular fluid: implications for oxidative stress in human periodontal diseases, *journal of periodontology*, 2004; page287–293
7. Maria Koziol-Montewka et.al; MPO and Cytokines in the Serum of periodontitis Patients in the, *Immunological Investigations Lublin*, Vol 35, is 2 July 2006, pp 167
8. Tatjana Todorovic, Ivan Dozic, Mariovicente Barrero. Salivary enzymes and periodontal disease. *Med oral patoral cir bucal*2006;11:E 115-9
9. I.V. Nikolaev, L.N. Kolobkova, E.O. Landesman, E.V. Stepanova, O.V. Koroleva, 2008, published *Biomeditsinskaya Khimiya Biochemistry (Moscow) Supplement Series B: Biomedical Chemistry*, 2008, Vol. 2, No. 4, pp. 426–431., 2008.
10. M.Faith, A. Sukumaran, A.B Pulimood, and M.Jacob. How reliable an indicator of inflammation is myeloperoxidase activity. *Clinical chimica acta*, vol396, no1-2, pg 23-25,2008
11. Celso Martins Queiroz-Junior, Cinthia Mara da Fonseca Pacheco, Myeloperoxidase Content is a Marker of Systemic Inflammation in a Chronic Condition Mediators of Inflammation Volume 2009, Article ID 760837, pages 71
12. Marcaccini AM, Meschiari CA, Zuardi LR, de Sousa J Gingival crevicular fluid levels of MMP-8, MMP-9, TIMP-2, and MPO, *Clinical Periodontology* 2010; 37: 180–190, 5 October 2009

**SPIK Forthcoming Events**

- \* December 2010 - UG / PG Convention at Trivandrum
- \* April / May 2011 - 5th Annual Conference and Family Get together