

Index Copernicus ID 6818

ISSN 2231- 1823

Journal of the Society of
Periodontists and
Implantologists of Kerala



JSPIK

Volume 11 • Issue 2 • JULY 2019

www.spik.in



OFFICE BEARERS

President

Dr. Harikumar Menon

Secretary

Dr. Jayan Jacob Mathew

Immediate Past President

Dr. Seema Thampi

President Elect

Dr. Sabu Kurian

First Vice President

Dr. Jose Paul

Second Vice President

Dr. Biju Philip

Joint Secretary

Dr. Fermi E.D.

Treasurer

Dr. Tony Kurian

Editor

Dr. Sameera G. Nath

Scientific Programme Convenor

Dr. Mohammed Feroz

Periodontal Health Convenor

Dr. Mahesh Narayanan

Website Convenor

Dr. Plato Palathingal

**EXECUTIVE
COMMITTEE MEMBERS**

Dr. Santosh Sreedhar

Dr. Siby T Chennankara

Dr. C K Ashokan

Dr. Baiju R.M.

Dr. Presanthila Janam

Dr. Anto Joseph

Dr. Majo Ambooken

Dr. Mathew Thomas

Dr. Arun Sadasivan

Dr. Vivek Narayanan

Dr. Binitta Paul K.

Dr. Jithin Balan

ADVISORS

Dr. Thomas Thelly

Dr. B R R Varma

Dr. Rezy Cheru

Dr. Meharunissa Bai

Dr. K Nandakumar

Dr. H Shamsuddin

Dr. Kunjamma Sebastian

Assistant Editor

Dr. Shahana C. Mohammed

EDITORIAL BOARD

Dr. K Nandakumar

Dr. Harish Kumar VV

Dr. Rosamma Joseph

Dr. Presanthila Janam

Dr. Bindhu R Nair

Dr. Biju Thomas

REVIEW PANEL

Dr. Seema Jayakrishnan

Dr. Anuradha Bhaskar

Dr. Sajith Abraham

Dr. Anoop V

Dr. Roshni Ramesh

Contents

President's Message	56
Guest Editorial	57
Secretary's Message	58
Stem cells – A future alley of dentistry: Assessment of the knowledge, scope and applications among dental professionals	59
Anjana Vasudevan T, Subair K, Anil Melath, Mohammed Feroz TP, Ashitha Mohandas, Nanditha Chandran, Krishna Priya B	
Evaluation of palatal rugae pattern and number in patients with evidence of gingivitis and periodontitis	64
Krishna Priya B, Anil Melath, Mohammed Feroz TP, Subair K., Ashitha Mohandas, Nanditha Chandran, Anjana Vasudevan T.	
Neutrophils – A Trivia in Periodontitis Unresolved???	68
Lekshmi A J, Bindu R Nayar	
Free gingival Graft – The Silver bullet in Periodontal Plastic Surgery	77
Binitta Paul K, Jose Paul, Johnson Prakash d'lima, Senny Thomas Parackal, Deepak Thomas, Syed Mohammed Jiffry C.A.	
Barrier membranes: How well they navigate cells?	81
Hemalatha DM, Anil Melath, Mohammed Feroz TP, Subair K, Ashitha M, Nanditha Chandran	
Recurrent Case of Peripheral Ossifying Fibroma: Case Report with One Year Follow-Up	86
Seba Abraham, Arya Premnath, Arunima P.R., Reejamol Mohammed Kassim	
Gingival enlargement – An initial manifestation in a case of a T-lymphoblastic lymphoma leukemia	90
Vangala Preeti, Ramisetti Arpita, Muthineni Ramesh Babu, Sravani CH	
The esthetic smile rehabilitation: An interdisciplinary concept, a case report	94
Anu Chandran, Amitha Ramesh, Rahul Bhandary, Biju Thomas	



President's message

Intelligence is nothing but the ability to adapt to change

-Stephen Hawking

Friends, I am happy to communicate with you again....

In the previous issue, I stressed the need to **group together** and **infuse the concepts** of Periodontology among general dental practitioners. I congratulate Dr Mohammed Feroz and Dr Jayan Jacob for the efforts they took to materialize our goal in that area. Every member of SPIK family should also give due importance to **read and write our science** and document the work we do in clinical, academic and research platforms. Whenever we get an opportunity to publicize our work we can do it in our esteemed journal. I strongly believe a good journal is always a reliable platform for scientific communication within the fraternity regarding the innovations and changes that take place in the field over time. I congratulate Dr Sameera Nath and the editorial team for the consistency they display in order to bring out the issues in time without any compromise in the quality of the content.

The world is changing so is science. The best way to deal with change is to accept change. In this context, my humble appeal to SPIK family is to share your knowledge, findings, experience, ideas and whatever thought you have in the field of Periodontology, with our fellow members so that together we can update and expand our knowledge base to a great extent. To share these and to communicate the changing science, let us use our journal space wisely so that our enthusiasm may motivate our editorial team to bring out the future issues with more colour, content, charm and glory.

"Sharing is caring"

Yours in SPIK

Dr Harikumar Menon
Additional Professor in Periodontics
Government Dental College, Kozhikode
Mob: 984712817
Email: harisindhu@hotmail.com



**Dr Thomas Thelly S, MDS,
DDPHRCs (London)**

Born in 1930, Sir has 55 years of experience in clinical practice, 53 years in academics and 41 years of service in Administration. Graduated from Dr R Ahmed Dental College Calcutta in 1957, completed post-graduation in Periodontics from GDC Bombay in 1965, and a Diplomate in Dental Public Health from Eastman Dental Hospital, London in 1991. Served under DME until 1974 as Professor & Head, GDC Thiruvananthapuram and continued service in other dental colleges in the capacity of Professor, Principal, Dean and Professor Emeritus across the country and overseas until 2012.

Recognition Awards

Indian Dental Association – Kerala State “ Association Appreciation Award”

Best Teaching Dental Faculty Member in the Directorate of Medical Education for the year 2000

Geriatric Periodontology

As the proportion of elderly people and prevalence of oral and systemic diseases is increasing, it has led to a considerable challenge in providing oral health care to the geriatric population. The number of older patients is rising steadily. The number of edentulous patients continues to decrease. Thanks to preventive measures and thanks to the number of available abutments being augmented by implants. However, residual teeth as well as implants and the prostheses they support require more sophisticated care and oral hygiene than the less and less popular complete dentures.

The world’s population is aging, and it has been estimated that by 2050, the number of people 65 years of age and older will reach 1.5 billion. The aging population will be affected by non-communicable chronic diseases, including diabetes mellitus, cardiovascular disease and cognitive impairment. This important demographic shift includes a reduction in tooth loss/edentulism, particularly in older adults. Therefore, in the future, dental providers will be required to care for an expanded number of older adults who have retained teeth and are medically complex.

As the linkage of oral disease and systemic disease has focused on the relationship of periodontitis and non-communicable chronic diseases, a broad review of ‘geriatric periodontology’ is both timely and important. If embraced, this shift will allow the dental profession to be more closely aligned with the larger health-care environment, and can improve both oral health and health outcomes for patients seen in the dental office.

Dr Thomas Thelly S.



Secretary's Message

Dear SPIK members,

Let me start by congratulating our enthusiastic editor Dr. Sameera Nath for bringing out the last issue of JSPIK on time. I request all our life members and associate members to continue contributing to the mouthpiece of our organization.

The new SPIK year has started on a bright note with two new life members and six associate members joining our fold. It's a humble urge to all post-graduate guides to encourage the fresh MDS batch students to take membership in SPIK.

It need not be overemphasized that the growth of our specialty depends a lot on the support and cooperation of general practitioners. Keeping this in view, we have planned our first program as a combined CDE workshop with IDA Malabar, which is scheduled on June 16th at Kozhikode, with the general practitioners as the primary target audience. Our esteemed members, Dr. C K Ashokan and Dr. Arun Sadasivan have kindly consented to be the faculty for the program on behalf of SPIK. I take this opportunity to appreciate our President, Dr. Harikumar Menon for the initiative and our Scientific Convenor, Dr. Mohammed Feroz for coordinating the same. In this context, I request all SPIK members to utilize all available avenues for creating awareness regarding Periodontics among fellow practitioners, medical specialists and general public at large.

In the coming months we are planning for the Oral Hygiene Day Celebrations in August and a one-day Scientific Program in September, the details of which shall be communicated in due course.

Once again requesting the continued support and cooperation of our members in all SPIK activities.

Let Periodontics flourish further

Dr. Jayan Jacob Mathew
Secretary, SPIK

Stem cells – A future alley of dentistry: Assessment of the knowledge, scope and applications among dental professionals

Anjana Vasudevan T¹, Subair K², Anil Melath³, Mohammed Feroz TP⁴, Ashitha Mohandas⁵, Nanditha Chandran⁶, Krishna priya B⁷

ABSTRACT

Introduction: A variant of adult stem cell, which exhibits multipotent characteristics and is capable of differentiating into various forms is holding a most superior position in regards to regenerative approaches in the dental as well as medical scenario. Because of these many identical properties, these are also termed as progenitor cells. The dental stem cells will really seems to be an inevitable or obligatory contribution of the scientific world in the near future. Henceforth the knowledge, scope and applications in this domain among the dental professionals is of paramount importance.

Objective: To evaluate the knowledge, scope and applications of stem cells among the aspiring smile designers is important to widen the horizon of dentistry.

Methodology: The present study is a questionnaire based study and 18 questions were circulated among the interns and post graduates of a dental college in Mahe.

Results: Study revealed that the awareness, scope and application varied based on the educational qualification. Chi- square test showed significant association between the variables.

Conclusion: This study revealed an excellent amount of awareness among the dental professionals and will definitely help to uplift the ideology. Further studies should be conducted in order to emphasize the importance of future scopes of stem cells in dentistry.

Key words: stem cells, multipotent, regenerative, progenitor cells.

Introduction

“Necessities are the mother of inventions”. Likewise, ‘initium novum’ is mandatory for every research. Regeneration refers to the reproduction or reconstruction of an injured part by means of new materials or inventories. Among this stem cells play a pivotal role in the recent past. Stem cells are immature cells which have the unique property of self-renewal and differentiation into multiple cell types.¹ These are unspecialized cells that are capable of becoming specialized cells or tissues or organs, so called as universal cells. Stem cells are seen right from nativity to mortality thus they seems to be immortal.

The pioneer of stem cells is Wilson et al. Personalized medicine which mainly focuses on the growth and regeneration of tissues using stem cells from the patient ensures biocompatibility and patient specific treatment.²

The two variants of stem cells include embryonic stem cells (ESC’s) and adult or somatic stem cells (ASC’s). This categorization is based upon the site of origin and isolation. Stem cells not only play a crucial role in the medical scenario but also in the field of dentistry and so termed as Dental stem cell. Dental stem cell, a type of ASC, exhibits multipotent differentiation capacity and is drawing worldwide attention

^{1,7}Post graduate student, ^{2,4}Professor, ³Professor & Head, ^{5,6}Assistant Professor, Department of Periodontics, Mahe Institute of Dental Sciences and Hospital, Mahe - 673310 Corresponding Author: Dr. Anjana Vasudevan T., Email: annjuvt@gmail.com

because of its various applications.³⁻⁵

The dental stem cells seem to be an inevitable or obligatory contribution of the scientific world for a better future. Since dentists play a critical role in the preservation, extraction and collection of teeth from the patient's own mouth, the dental clinics can be considered as a prospective power bank or stem cell bank. The teeth are highly differentiated chewing organs formed by the development of tooth germ tissue located in the jaw and consists of the enamel, dentin, pulp and periodontal tissue.⁶ And each tooth varies in its structure, appearance, functions, histologic nature of origin and thus differ in the extend of regeneration.

The stem cell ideology is developing in its gradual pace and it is necessary to uplift this for further development. Even though this novel modality is having a heartening future, we the whippersnappers have to take an initiative for its well being. Henceforth the knowledge, scope and applications in this domain among the dental professionals is of paramount importance. Therefore this study was aimed to evaluate the knowledge, scope and applications of stem cells

among the aspiring smile designers in order to widen the horizon of dentistry.

Methodology

This was a questionnaire based study which included open and close ended questionnaires were distributed among the post graduates and interns of a dental institution at Mahe. All the questionnaires were distributed among 120 subjects. The study was completed over a period of two weeks in the month of February 2019. The questionnaire was validated and approved by the institutional ethical committee (Table 1).

A total of 11 questions with sub questions were circulated among the target population. This questionnaire was designed by referring some published research articles related to stem cells.^{3,7-9} The questionnaire was divided into 2 parts which included demographic details(personal and professional data) and 1-6 questions was based upon assessing the awareness and the rest regarding the knowledge of scope and applications.

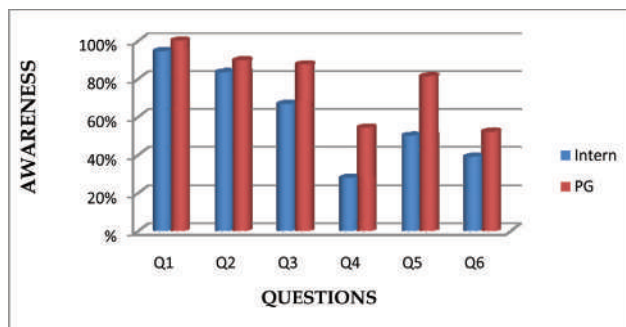


Fig 1: Graphical presentation assessing the awareness level among the post graduates and interns.

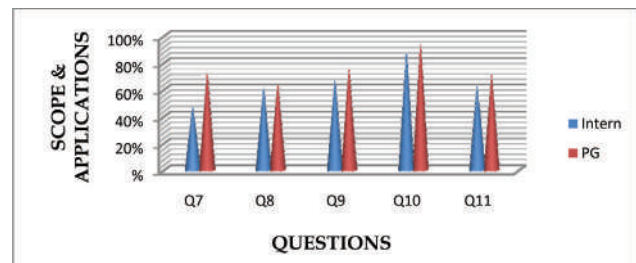


Fig 2: Percentage of knowledge regarding scope and applications among the post graduates and interns.

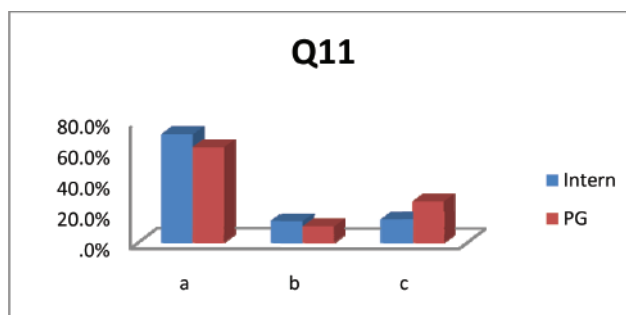


Fig 3: Graphical presentation depicting the percentage of beliefs among the post graduates and interns for regulating the use of stem cell and regenerative dentistry.

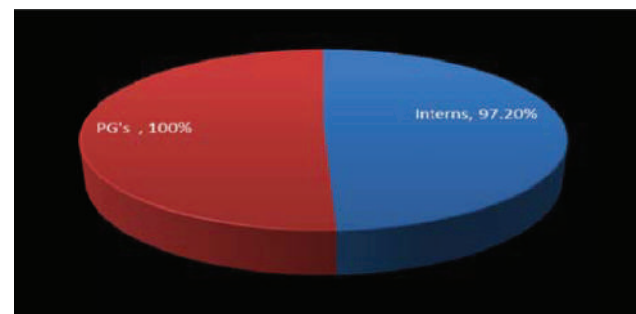


Fig 4: Pie chart representing the overall percentage of awareness among the post graduates and interns.

Statistical analysis

All the answers or categorical data are expressed as frequency and percentages. Chi – square test was used to find the significant association between the variables and corresponding graphical presentations were done. Data was analysed using the SPSS version 22.0. The level of statistical significance was set at P value < 0.05.

Results

Out of 120 target size, 48 were post graduates and 72 were interns.

1. Assessment of the awareness level among the post graduates and interns

First six questions of the second part comprised of awareness level queries. In case of all the six questions, post graduates stood forefront in the percentage of awareness of which the most appreciated result among the six questions was regarding the awareness of the terminology “stem cells” and the results revealed that all the post graduates were aware about the same and they were least aware about the guidelines given by the Indian Council of Medical Research but that too more than that of interns.

2. Assessment of the knowledge of scope and applications of stem cells

Post graduates have attended more conferences/workshops related to this topic and they show keen interest in attending further research programs with a highest percentage of 93.8 when compared to interns with 87.5%. 64.6% of post graduates were aware of the main obstacles we face for making use of stem

cells for different treatments and willingness for the preservation and collection of dental stem cells than that of 61.1% of interns.

70.8% of post graduates and 62.5% of interns believed that dental professional associations should regulate the use of stem cell and regenerative dentistry.

Discussion

Since stem cells are termed as clonogenic cells, they have the unique ability to transform into specialized cells, tissues or organs with their characteristic self-renewal and multipotent nature. The term “stem cell” was coined by Wilson. A histologist from Russia by name Alexander Maksimov postulated the existence of hematopoietic stem cells in the year 1908.¹⁰ Based on the potency they were categorized into pluripotent, totipotent, multipotent, oligopotent, unipotent etc. embryonic stem cells are pluripotent cells that develop from the inner cell mass of a blastocyst during pre-implantation stage while adult stem cells are multipotent in nature so that they develop into more than one type of the cells. Sources of adult stem cells include brain, bone marrow, liver, adipose tissues, pancreas etc.

Dental stem cell is a type of adult mesenchymal cell which has ease of access and is feasible source of stem cells.¹⁰ They are mainly isolated from dental pulp, periodontal ligament, dental follicle stem cells (DFSC), stem cells from apical papilla (SCAP), Induced pluripotent stem cells etc. their diverse applications include regeneration of pulp, periodontal ligament, dentin, craniofacial defects, whole tooth regeneration.

This study aimed at assessing the awareness level and knowledge of the scope and applications among the dental professionals. Study results revealed that 100% of the post graduates were aware about the terminology ‘stem cells’ than that of interns(94.4%). 81.3% of the post graduates were about the applications of stem cells than interns with a percentage of 50%. Sede et al. found 81% of awareness about the use of stem cell in dentistry.¹⁰ In our study in case of the major source of information, post graduates reported with high source of information from books, internet,

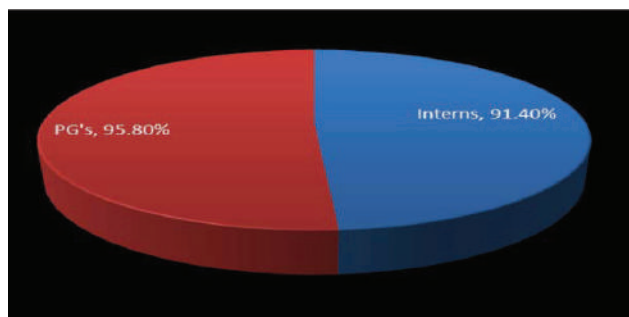


Fig 5: Overall percentage of knowledge among the scope and applications among the post graduates and interns.

Table 1: Questionnaire

GENERAL INFORMATION	
Name:	Age:..... Gender: Male/Female
Qualification: Intern/BDS/Postgraduate student/MDS Specialty:	
Years of experience:	
1.a. Have you heard of the terminology dental stem cells?	
<input type="checkbox"/> Yes <input type="checkbox"/> No	
1.b. Specify your source of information.	
<input type="checkbox"/> Books <input type="checkbox"/> Journals <input type="checkbox"/> Magazines <input type="checkbox"/> Internet <input type="checkbox"/> Mass media <input type="checkbox"/> Conference/Convention/Symposium	
<input type="checkbox"/> Seminar <input type="checkbox"/> Undergraduate training <input type="checkbox"/> PG training <input type="checkbox"/> If others (Specify)	
2.a. Are you aware of the different types of stem cells?	
<input type="checkbox"/> Yes <input type="checkbox"/> No	
2.b. If yes, what are different types of stem cells?	
<input type="checkbox"/> Embryonic stem cells <input type="checkbox"/> Adult stem cells <input type="checkbox"/> All the above <input type="checkbox"/> No idea	
3.a. Are you aware of the different types of dental stem cells?	
<input type="checkbox"/> Yes <input type="checkbox"/> No	
3.b. Dental stem cells can be extracted from which of the following sources?	
<input type="checkbox"/> Dental pulp stem cells <input type="checkbox"/> Stem cells from human exfoliated deciduous teeth	
<input type="checkbox"/> Stem cells from apical papilla <input type="checkbox"/> Dental follicle progenitor cells	
<input type="checkbox"/> Stem cells from periodontal ligament <input type="checkbox"/> All of the above <input type="checkbox"/> None <input type="checkbox"/> No idea	
3.c. Which of the following tooth can be used to obtain dental stem cells?	
<input type="checkbox"/> Deciduous teeth <input type="checkbox"/> Permanent third molars <input type="checkbox"/> Teeth extracted for orthodontic purposes	
<input type="checkbox"/> Supernumerary tooth <input type="checkbox"/> All the above <input type="checkbox"/> None	
4. Are you aware of dental stem cell banks in India?	
<input type="checkbox"/> Yes <input type="checkbox"/> No	
5.a. Are you aware of the various applications of dental stem cells?	
<input type="checkbox"/> Yes <input type="checkbox"/> No	
5.b. If yes, what are the different clinical applications of dental stem cells in relation to oral health care?	
<input type="checkbox"/> Whole tooth regeneration <input type="checkbox"/> Periodontal ligament, cementum, alveolar bone regeneration	
<input type="checkbox"/> Regeneration of pulp/dentin <input type="checkbox"/> Root formation <input type="checkbox"/> All the above <input type="checkbox"/> None <input type="checkbox"/> No idea	
6. Are you aware of the guidelines related to dental stem cells given by the Indian Council of Medical Research?	
<input type="checkbox"/> Yes <input type="checkbox"/> No	
7. In your clinical practice, will you recommend or advise your patients to store/preserve dental stem cells?	
<input type="checkbox"/> Yes <input type="checkbox"/> No	
8.a. Are you willing to collect dental stem cells?	
<input type="checkbox"/> Yes <input type="checkbox"/> No	
8.b. What do you think is the main obstacle to seek the treatment with the aid of dental stem cells?	
<input type="checkbox"/> High cost <input type="checkbox"/> Lack of awareness <input type="checkbox"/> Ethical issues <input type="checkbox"/> Insufficient knowledge about stem cells among the dental practitioners <input type="checkbox"/> Insufficient knowledge about stem cells among people <input type="checkbox"/> Insufficient knowledge about stem cells among dental practitioners as well as people <input type="checkbox"/> All the above <input type="checkbox"/> None	
9. Are you willing to invest for dental stem cell banking?	
<input type="checkbox"/> Yes <input type="checkbox"/> No	
10.a. Have you attended any workshop/conference/seminar or continuing dental education program on application of stem cells?	
<input type="checkbox"/> Yes <input type="checkbox"/> No	
10.b. In future, are you interested to attend any workshop/conference/seminar or continuing dental education program about the applications of stem cells?	
<input type="checkbox"/> Yes <input type="checkbox"/> No	
11. Do you believe that dental professional associations should regulate the use of stem cell and regenerative dentistry?	
<input type="checkbox"/> Yes <input type="checkbox"/> No <input type="checkbox"/> Not sure	

undergraduate training, magazines, seminar etc. This results may be due to the easy accessibility. This could be due to increased spurt of conversation regarding the topic within the public through a variety of forums like increased publication of scientific articles and also because it is one of the most novel topics ruling the world of medicine and dentistry.¹¹

In this study, about 70.8% of the post graduates were aware about the various applications of stem cells than interns with 44.4%. About 70.8% of post graduates consider high cost, lack of awareness, ethical issues, insufficient knowledge about stem cells among the dental practitioners and people, as the major obstacles to seek treatment with the aid of dental stem cells than interns with 38.9%. 93.8% of post graduates were willing to attend conferences/CDE/workshops than 87.5% of interns. Even though there is not much difference in the percentage of interns in their willingness to attend conferences/workshops, this minor differences can surely be surpassed by initiating or implementing these type of programs thereby inculcating the ideology in them.

As per this study, 61.1% of interns were unaware about the guidelines related to dental stem cells given by the Indian Council of Medical Research. From these tabulated results it is understood that there is an increased need to make the dental professionals aware about the procedural safety and mode of conducting research (especially beneficence and non-maleficence) for performing human and animal trials.

Conclusion

The questionnaire study revealed an excellent level of awareness among the dental professionals. Some of the questions showed a statistically significant

association with the academic proforma. On the basis of categorization based upon educational qualification, post graduates showed a better response than interns on the prime motives like awareness, scope and applications of stem cells. Thus it reveals an urge among the aspiring smile designers to widen their horizon of dentistry through the concept of stem cells. Further long term studies should be conducted in order to enlarge the dreams and aspirations of tomorrow's aesthetic smile designers by implementing the applications of stem cells into the curriculum.

References

1. Zhang H, Wang ZZ. Mechanisms that mediate stem cell self-renewal and differentiation. *J. Cell. Biochem.* 2008 Feb 15;103(3):709-718.
2. Jose N. Assessment of Knowledge, Attitude, and Practice regarding Applications of Stem Cells in Dentistry among Dental House Surgeons, Postgraduate Students, and Teaching Faculties in Two Dental Colleges in Ernakulam, Kerala, India. *Int J Oral Care Res* 2018;6(1):65-68.
3. Bhatt R, Bhatt A, Gurjar D, Dave L. Evaluating awareness on dental pulp stem cells and its applications amongst graduating dental students of Ahmedabad and Gandhinagar district: A cross sectional survey. *Adv Hum Biol* 2014;4:54-59.
4. Goomer P, Sidhu AK, Tuli P, Kansal S, Bansal K, Thakre GR. Awareness of stem cells and health implications of SHED found in pediatric dentition among Indian population. *J Int Oral Health* 2014;6:44-47.
5. Rai S, Kaur M, Kaur S. Applications of stem cells in interdisciplinary dentistry and beyond: An overview. *Ann Med Health Sci Res* 2013;3:245-254.
6. Zhai Q, Dong Z, Wang W, Li B, Jin Y. Dental stem cell and dental tissue regeneration. *Front Med.* 2019. Apr, 13(2):152-159.
7. Sede MA, Adu O, Azodo CC. Stem cells in dentistry: Knowledge and attitude of Nigerian dentists. *BMC Oral Health* 2013;13:27.
8. Goyal A. Knowledge, awareness and attitude regarding stem cells among dental practitioners in Udaipur city, Rajasthan. *Int J Adv Res* 2015;3:677-684.
9. Utneja S, Nawal RR, Ansari MI, Talwar S, Verma M. A survey of attitude and opinions of endodontic residents towards regenerative endodontics. *J Conserv Dent* 2013;16:314-318
10. Chitroda PK, Katti G, Attar NM, Shahbaz S, Sreenivasarao G, Patil A. Stem cells in dentistry: A study regarding awareness of stem cells among dental professionals. *Indian J Dent Res* 2017;28:711-716.
11. Huang GT, Gronthos S, Shi S. Mesenchymal stem cells derived from dental tissues vs. those from other sources: Their biology and role in regenerative medicine. *J Dent Res* 2009;88:792-806.

Evaluation of palatal rugae pattern and number in patients with evidence of gingivitis and periodontitis

Krishna Priya B¹, Anil Melath², Mohammed Feroz TP³, Subair K.⁴, Ashitha Mohandas⁵, Nanditha Chandran⁶, Anjana Vasudevan T.⁷

ABSTRACT

Introduction: The Palatal rugae are anatomical structures with, forensic clinical and anthropological significances. The number and patterns of palatal rugae are not uniform in all individuals, and they appear to vary in different populations. Variations of the pattern and number of palatal rugae can be seen with the advancement of diseases like gingivitis, chronic periodontitis and aggressive periodontitis. Smoking is also a main factor which will leads to the alterations in the pattern and number of palatal rugae.

Objectives: To determine and compare the pattern and number of rugae in patients with gingivitis, patients with periodontitis (non Smokers) and patients with periodontitis (chronic smokers).

Methodology: The present study included study maxillary casts of attending patients (46) who were divided in to three groups: (1) Patients with gingivitis, (2) Patients with periodontitis (non smokers), (3) Patients with periodontitis (chronic smokers). Palatal rugae pattern were evaluated for the number and shape according to the Modified Lysell Classification (1955).

Results: The number of rugae was found to be more in Gingivitis patients when compared to patients with periodontitis (non smokers) and patients with periodontitis (non smokers). Variation in the pattern of rugae is also evident.

Conclusion: Palatal rugae can be considered relevant for human identification although it is important to rule out certain risk factors like inflammatory diseases like periodontitis, and effect of smoking on the palatal rugae which results in the variations in the pattern and number of palatal rugae.

Key words: periodontitis, gingivitis, palatal rugae, chronic smokers

Introduction

Human identification has become fundamental in all aspects of human relationships, at both social and legal levels. Identification corresponds to a combination of different procedures to individualize a person or an object.¹ The Palatal rugae are anatomical structures with, forensic clinical and anthropological significances. The number and patterns of palatal rugae are not uniform in all individuals, and they appear to vary in different populations.² Palatal rugae have been considered relevant for human identification due to

its stability, being equivalent to the fingerprint, unique for each individual.³ Transverse palatine folds or palatal rugae are asymmetrical, irregular elevations of the mucosa located in the anterior third of the palate.⁴ Palatal rugoscopy or palatoscopy is the name given to the study of palatal rugae in order to establish a person's identity.⁵ The application of palatal ruga patterns for personal identification was first suggested by Allen in 1889.⁶ Palatal rugoscopy was first classified in 1932 by a Spanish investigator named Trobo Hermosa.⁷ Rugae performs numerous function as physiologically

^{1,7}Post graduate student, ²Professor & Head, ^{3,4}Professor, ^{5,6} Assistant Professors, Department of Periodontics, Mahe Institute of Dental Sciences & Hospital, Mahe - 673310 Corresponding Author: Dr. Krishna Priya B E-mail: krishnapb1993@gmail.com

it is involved in the act of deglutition, improve the relationship between food and taste receptors, and contributes to perception of taste, help in speech, and aids in suckling in children.⁸ The shape, length, width, prominence, number, and orientation of palatine rugae vary considerably among individuals. Rugae patterns are considered to be unique to individuals. However there are many factors which will leads to the alterations in the pattern and number of rugae.³ Hence this study is mainly focused to evaluate the variations in pattern and number of palatal rugae in patients with gingivitis, periodontitis (nonsmokers) and periodontitis (chronic smokers) and also evaluate whether there is any variations in the palatal rugae pattern and number with smoking habit.

Aim of the study

To evaluate and compare the difference in palatal rugae pattern and number in patients with evidence of gingivitis, periodontitis(non smokers) and periodontitis (chronic smokers).

Materials and methods

Study consisting of 42 individuals attending to the Department of Periodontics who were divided in to three groups after clinical examination and each group consist of 14 individuals.

- Group 1-Patients with Gingivitis.
- Group 2-Patients with Periodontitis (non smokers)
- Group 3- Patients with Periodontitis (chronic smokers)

Inclusion criteria

- Age between 20-55 years.
- Systemically healthy individuals.
- Patients who were diagnosed as gingivitis (moderate) and periodontitis(chronic).
- Patients who were chronic smokers (smoke 20 or more cigarettes per day) with periodontitis.

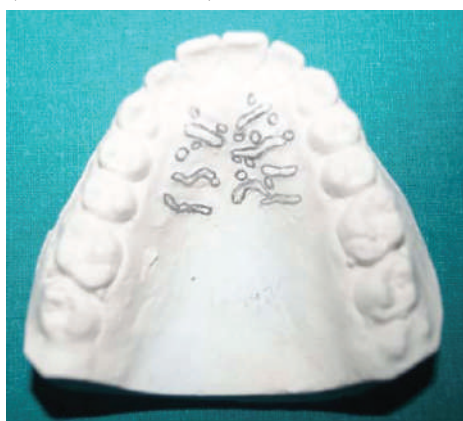

Fig 1: Model showing the pattern and number of palatal rugae in patients with gingivitis

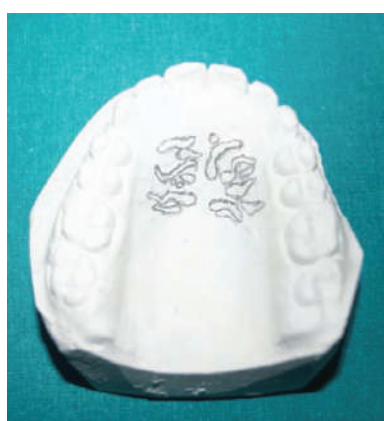

Fig 2: Model showing the pattern and number of palatal rugae in patients with Periodontitis (non smokers)

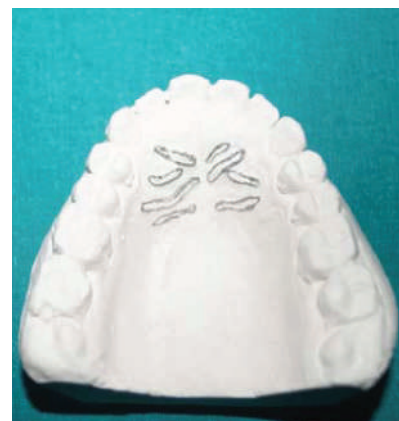

Fig 3: Model showing the pattern and number of palatal rugae in patients with Periodontitis (chronic smokers).

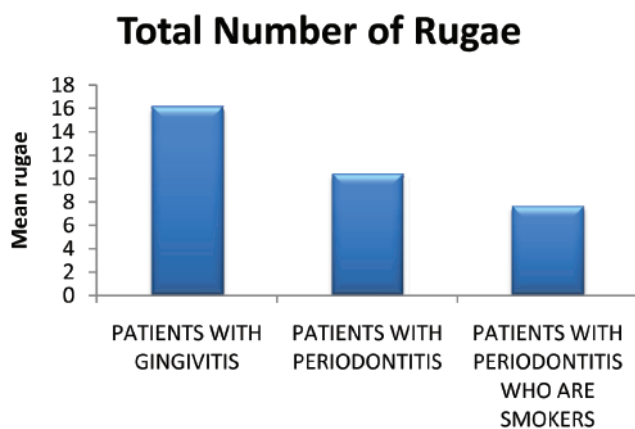


Fig 4: Total number of rugae in each group

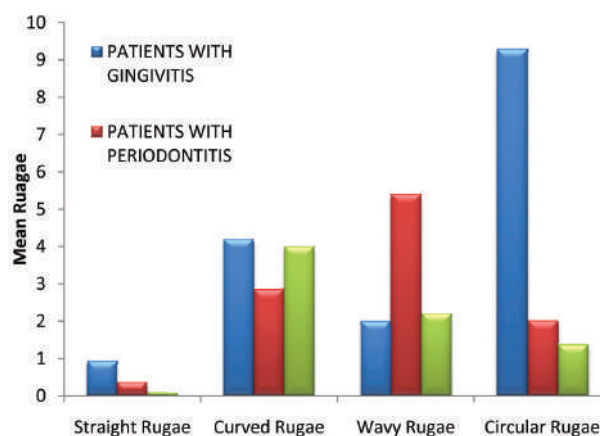


Fig 5: Different patterns of rugae in each group

Exclusion criteria

- The patients with congenital abnormalities of palate.
- Patients with history of surgery and trauma in palate.
- Patients with malocclusion or any missing teeth (excluding third molars).
- Patients underwent Orthodontic treatment.

Materials and methods

Alginate impression of the maxillary arch of the subjects were made in impression tray and poured in

Table 1: Comparison of Total Number of Rugae

Group	Mean±SD	Range	p-value
Patients with gingivitis	16.21±4.677	11-25	<0.001*
Patients with periodontitis (non smokers)	10.43±1.950	7-15	
Patients with periodontitis (chronic smokers)	7.64±2.818	4-12	

*Indicates significant difference in rugae pattern between groups-When total number of rugae compared between the groups, it was observed that there is significant difference in mean total number of rugae ($p < 0.001$). It is observed that total number of rugae in patients with gingivitis (16.21 ± 4.67) is more followed by patients with periodontitis (nonsmokers) (10.43 ± 1.95) and patients with periodontitis (chronic smokers) (7.64 ± 2.82)

dental stone (Fig 1, 2 & 3). The rugae appeared with prominent ridges were delineated using a sharp graphite pencil and were recorded according to the Modified Lysell classification (1995).⁹ The rugae pattern and number of rugae were recorded separately.

Curved - These type have a simple crescent shape which curve gently.

Straight -These type of rugae ran directly from their origin to termination in a straight line. Slight bend at the termination or origin of rugae.

Wavy- The shape is like serpentine. There is slight curve at the origin or termination

Circular-The rugae have a definite continuous ring formation

Statistical analysis

Categorical data will be expressed as frequency and percentages. Continuous variables will be expressed in terms of mean and SD. One way ANOVA will be used to compare between the groups. Appropriate graphs will be used to visualize the data. Data will be analysed using the statistical software –SPSS.22.0. P value less than 0.05 will be considered significant.

Results

The results are demonstrated in Fig 4, 5 and tables 1& 2.

Table 2: Comparison of Rugae Pattern

Group	Straight Rugae	Curved Rugae	Wavy Rugae	Circular Rugae
Patients with gingivitis	0.93±0.730	4.21±1.251	2.00±0.784	9.29±3.245
Patients with periodontitis(non smokers)	0.36±0.745	2.86±0.663	5.43±1.158	2.00±1.240
Patients with periodontitis (chronic smokers)	0.07±0.267	4.00±1.240	2.21±1.122	1.36±1.151
p-value	0.003*	0.004*	<0.001*	<0.001*

*Indicates significant difference in rugae pattern between groups-When comparing the patterns of rugae between the three groups circular pattern is more evident in patients with gingivitis, whereas wavy pattern in patients with periodontitis who are non-smokers and curved pattern in patients with periodontitis who are chronic smokers is observed.

Discussion

The Palatal rugae protrusions are mainly consisting of dense connective tissue. The core fibers in the human palatal rugae contain many factors that helps to maintain the palatal shape and the number. The main component of palatal rugae is hydrophilic glycosaminoglycan which enhances tissue swelling of the palate and helps to maintain palatal rugae pattern. From this study it was evident that there is a significant difference in the number and pattern of palatal rugae between the three groups. When the total number of rugae compared between the three groups, we observe that there is significant difference in mean total number of rugae. It was observed that the total number of rugae in patients with gingivitis is more followed by patients with periodontitis who are non smokers and patients with periodontitis who are chronic smokers.

Similar results were observed in a study done by Rutuja PS et al, who compared pattern and number of palatal rugae between normal healthy individual and periodontitis patients and found out that more number of rugae and circular pattern among healthy and less number of rugae and wavy pattern among periodontitis patients. They concluded that as these were inflammatory conditions they could damage the pattern of rugae in individuals and make identification difficult.²

When comparing the patterns of rugae between the three groups circular pattern is more evident in patients with gingivitis, whereas wavy pattern in patients with periodontitis who are non-smokers and curved pattern in patients with periodontitis who are chronic smokers is observed.⁹

Study done by Jindal et al compare the palatal rugae in gingivitis, chronic periodontitis and aggressive periodontitis found there is difference in rugae shape between the three groups. They concluded that most prevalent palatal rugae shape in aggressive periodontitis was found to be angle followed by Sinuous and in chronic and aggressive periodontitis was sinuous followed by line pattern. They described that the differences in this three group is mainly due to genetic factors, recent shared ancestry and disease progression.¹⁰ Study done by Kapali et al, found that malpositioning of teeth; pathologies involving the palate could cause alteration in pattern of rugae. Extractions also cause change in position of palatal rugae adjacent to the alveolar arch.¹¹

Different researchers pointed out that there are possibility to change the pattern and number of palatal rugae with age as well as some other outside influences (orthodontic treatment, teeth extraction, abnormalities in palate, advancement of periodontal diseases).

From this study it was concluded that smoking has an effect to change the pattern and number of palatal rugae, may be it is due to the effect of nicotine to fibroblast, collagen, connective tissue, glycosaminoglycans of the palate. More studies are required to find the actual mechanism by which the smoking can effect the change in pattern and number of palatal rugae.

Conclusion

The Palatal rugae can be considered relevant for the human identification although it is important to rule out the important factors which will affect the change mainly morphological variations occurring in the palatal rugae. From this study it was evident that there is a significant difference in the number and pattern of palatal rugae between the three groups and also smoking has an impact to change the pattern and number of palatal rugae. But the actual mechanism by which how these factors will leads to the alterations of the palatal rugae pattern and number is unknown. So more studies and research are required to further analysis the main cause for the morphological alterations in the palatal rugae pattern and number.

References

1. Kesri et al: Rugoscopy –Science of palatal rugae- A review. *Int J Dent Med Res* 2014;1(4):103-107.
2. Pillai et al: Quantitative and qualitative analysis of palatal rugae patterns in Gujarati population: A retrospective, cross-sectional study. *J Forensic Dent Sci.* 2016 Sep- Dec;8(3):126-134.
3. A Jain and R Chowdhary: Palatal rugae and their role in forensic odontology; *JICD*, 2013;4:1-8.
4. Sanjaya et al: Significance of palatal rugae-A review. *Int Dent J* 2012;2(2):74-84.
5. Kapali S, Townsend G, Richards L, Parish T: Palatal rugae patterns in Australian aborigines and Caucasians. *Aust Dent J.* 1997;42:129-33.
6. Allen H. The palatal rugae in man. *Dental Cosmos* 31, 1889, 6680.
7. Pueyo VM, Garrido BR, Sanchez JA. *Odontologia legal*. Forense, Masson, Barcelona: 1994, 277-292.
8. Shetty M, Premalatha K. Study of palatal rugae pattern among the student population in manglore. *J Indian Acad Forensic Med.* April-June 2011, 3(2): 112-115.
9. Rutuja P S et al; Rugae pattern determination in health and periodontal disease. *Int. J. of Allied Med. Sci. and Clin. Research* 2018; 6(3): 639-649.
10. Jindal V, Mahajan A, Mahajan N, et al. Rugae pattern determination in periodontitis patients: A descriptive study. *J Int Clin Dent Res Organ* 2016;8: 115-119.
11. Peavy DC J R, Kendrick G S. The effect of tooth movement on palatine rugae. *J Prosthet Dent* 1967;18: 536-542.

Neutrophils – A Trivia in Periodontitis Unresolved???

Lekshmi A J¹, Bindu R Nayar²

ABSTRACT

Myeloid derived phagocytes of human body, the neutrophils forms the foot soldiers of body defence. With a diversity of arsenal in their repertoire, like phagocytosis, degranulation, reactive oxygen species production and neutrophil extracellular traps, they form the primary modulators in inflammation. This article aims to review the defence mechanisms of neutrophils, their role in periodontitis, neutrophil defects and their modulation as a therapeutic approach.

Key words:

Keywords: neutrophils, defence mechanisms, neutrophil extracellular traps, neutrophil defects, immunomodulators

Introduction

Neutrophils are myeloid-derived, professional antimicrobial phagocytes can kill pathogens extracellularly, links innate and adaptive arms of the immune response, and help to endorse the inflammatory resolution and tissue healing.¹ They are the most common leukocytes recruited to the gingival crevice or periodontal pocket and are needed for periodontal tissue homeostasis.

Discovery and Development

Elie Metchnikoff in the year 1882, first discovered neutrophils. Paul Ehrlich first described neutrophils as polymorphonuclear leukocytes when new fixation techniques revealed lobulated nuclei and cytoplasmic granules containing host-defence molecules. The bone marrow is the principal hematopoietic organ of all vertebrates with the exception of

fish. From the bloodstream, primitive hematopoietic stem cells (HSCs) arrive in the bone marrow in the last embryonic stages.² In the developing foetus, neutrophil progenitors are seen as early as the first trimester and increase in quantity nearly fourfold in the second trimester when the bone marrow becomes the major site of haematopoiesis. Circulating neutrophil counts rise abruptly and stabilize in the first 48–72 h of life. In preterm infants, the baseline neutrophil count is lower and there is no rise in neutrophil count in the first few days of life. Neutrophils are continuously generated in the bone marrow from myeloid precursors by a process controlled by granulocyte colony stimulating factor (G-CSF) which is produced in response to interleukin-17 A. Neutrophils mature in the bone marrow in an orderly fashion from myeloblast to promyelocyte to myelocyte to metamyelocyte to band form and lastly the mature neutrophil. Only the latter two of

¹Post Graduate Student, ²Head of the Department. Department of Periodontics, Government Dental College, Trivandrum. Corresponding author: Dr. Lekshmi A.J., Email: lekshmiaj511@gmail.com

these stages, the band form and mature neutrophil are present in peripheral blood. Neutrophils should have a three to four lobed nucleus and a granular cytoplasm.³ It is estimated that neutrophils half-life is days instead of hours.⁴ (Fig 1)

Polymorphonuclear neutrophils circulate in blood vessels ‘in search’ of potential targets, such as chemokines produced by endothelial cells which elaborate signals for pathogen entry or loss of tissue integrity. Host–pathogen interactions are generally initiated via host recognition of conserved molecular structures on microorganisms, known as pathogen-associated molecular patterns. Pathogen-associated molecular patterns are sensed by the host’s pattern recognition receptors, which are expressed on immune cells, such as dendritic cells, macrophages and polymorphonuclear neutrophils. Localized infections activate tissue-resident cells, which include dendritic cells, macrophages, mast cells, endothelial cells and, in the particular case of gingivitis and periodontitis, epithelial cells of the gingival sulcus. During acute inflammation, various immune cells (macrophages and dendritic cells) at the site of injury release granulocyte colony-stimulating factor, a growth factor that stimulates polymorphonuclear neutrophil production, survival and mobilization from the bone marrow.

Neutrophil Recruitment

Free flowing neutrophils are readily mobilized to inflammatory sites through a systematically controlled process known as the leukocyte adhesion cascade

which initiates when endothelial cells get activated by an inflammatory stimuli and causes an upregulation of adhesion receptors such as E- and P-selectins on their surface.⁵ Neutrophils recognize these selectins and begin rolling (Fig 2a).

Next, neutrophils get activated by chemokines, which induce a high affinity state in integrins, another group of adhesion receptors present on the surface of neutrophils. Interaction of both selectins and integrins with their corresponding ligands leads to slow neutrophils rolling followed by a firm adhesion that brings neutrophils to further slowdown and terminate the flow. Finally, neutrophils crawl on the endothelium and transmigrate into infection or inflammation sites. This last process is regulated mainly by $\beta 2$ integrins.⁶ Transmigration is a complex process resulting in the passage of neutrophils through a gap free wall which is dependent on many molecules, such as junctional adhesion molecule-A, integrins, intercellular adhesion molecules, cluster of differentiation 31 (platelet endothelial cell adhesion molecule-1) and cadherins. The majority of neutrophils will choose a paracellular route using the endothelial cell– cell junctions for transmigration; however, about 10% will migrate transcellularly, directly through the centre of an endothelial cell (Fig 2b).

After passing through the endothelial layer, neutrophils have to exit through the vascular basement membrane. Neutrophils can use their proteases, such as matrix metalloproteinases, elastase or proteinase- 3, to permeabilize the basement membrane.⁷ Alternatively,

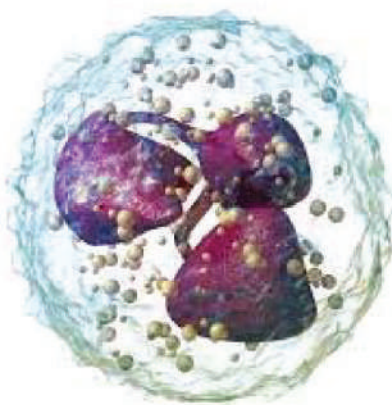


Fig 1: Neutrophil

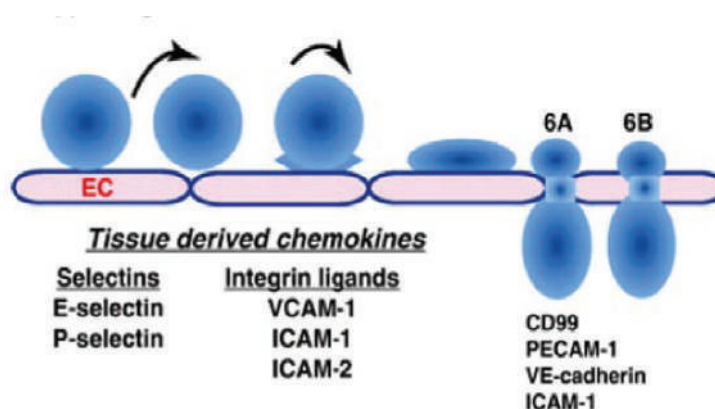


Fig 2a: Events related to the neutrophil recruitment

neutrophils will choose to migrate through membrane regions with limited expression of extracellular matrix components, such as collagen IV, laminin 10 and nidogen 2. Once neutrophils move into tissues, they follow chemoattractant gradients to reach infection or inflammation sites. Recently, it has been discovered that the leukocyte adhesion cascade is also negatively regulated by endogenous inhibitors such as Del-1 (developmental endothelial locus-1), pentraxin 3, and growth differentiation factor 15.⁸

Neutrophil Clearance

Once polymorphonuclear neutrophils have arrived in the inflamed periodontium they may undergo several courses of action which include searching and destroying the intruders; call reinforcements when needed; and commit suicide when the situation is under control. Neutrophils in tissues undergo apoptosis and then are cleared locally by resident phagocytes, such as macrophages and dendritic cells. Dying neutrophils return to the bone marrow for clearance after increasing expression of CXCR4.⁹ The clearance of apoptotic neutrophils is more than just elimination of old cells, since it is important for the control of neutrophil production in the bone marrow. Apoptosis of neutrophils is key to the prevention of collateral damage by neutrophil enzymes and reactive oxygen species that would otherwise be released into the periodontium upon neutrophil necrosis and/or degranulation.

Reverse neutrophil migration

It is a term to describe the general phenomenon

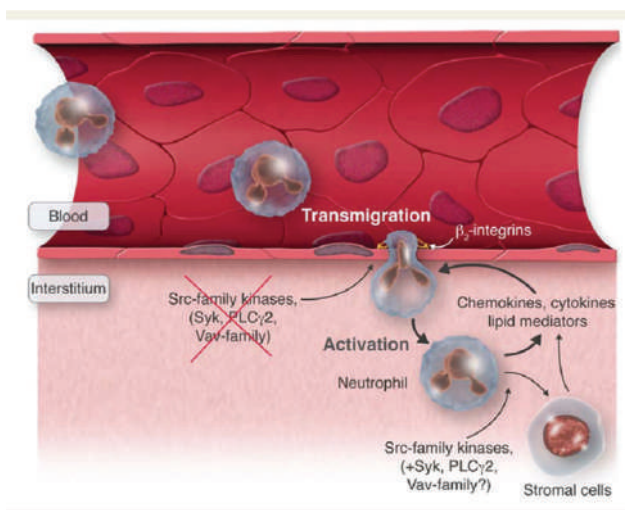


Fig 2b: Events related to the neutrophil recruitment

of leukocytes moving in the opposite direction to that expected. In some circumstances, this will be in the opposite direction taken by the net leukocyte population, and in others it will describe migration away from a stimulus which has previously been described as being chemotactic for leukocytes. First, this could be a way of preserving neutrophils when they are not needed to fight infection. However, it is also possible that the cells re-entering circulation could disseminate inflammation into other organs, eventually leading to damage.

Therapeutic Potential

At present the evidence for a physiological role for neutrophil TM suggests that promoting this response could be of benefit as a means of inducing resolution of inflammation. This finding potentially opens the door to a new class of pro-resolution therapeutics that drive inflammation resolution by accelerating rIM of unwanted activated neutrophils away from inflammatory sites. In contrast, neutrophil rTEM has been strongly implicated in dissemination of systemic inflammation, most notably following ischaemia-reperfusion injury. Blockers of neutrophil rTEM could provide a novel means to suppress distant organ damage after local injury.¹⁰

Neutrophils in Periodontal Health

Neutrophils are actively recruited into the gingival sulcus by an interleukin (IL)-8 gradient continuously secreted by the junctional epithelium, as this tissue is in close contact with the oral biofilm bacterial community. Neutrophils are mostly responsible for ensuring periodontal health by keeping this biofilm at check.

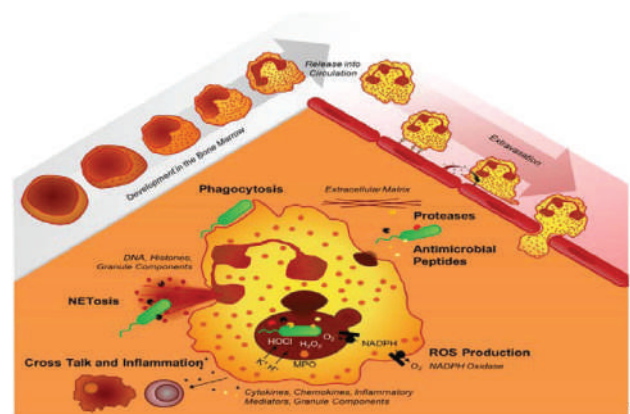


Fig 3: Defense mechanism of neutrophils

They exit the gingiva blood vessels and travel through the gingival junctional epithelium until they reach the crevice where they create a barrier against the growing bacteria biofilm. This neutrophil wall is thought to prevent bacteria from invading the underlying tissues.

Defense Mechanisms

Neutrophils can destroy periodontal pathogens by both oxygen-dependent (the “respiratory or oxidative burst”) and oxygen-independent (lytic and proteolytic enzymes) mechanisms (Fig 4).

Phagocytosis

Phagocytosis is a receptor-mediated process during which a particle is internalized by the cell into a vacuole called the phagosome. Neutrophils recognize pathogens through pattern-recognition receptors (PAMPs), or opsonins (antibody molecules or complement components). Opsonized pathogens are engulfed following which they fuses with the lysosomes in neutrophils to form a phagolysosome.¹¹ Inside the phagosome, the pathogens are digested by the enzymes and residual material is discharged out of the cell.

Degranulation

During the process of maturation or on stimuli activation, neutrophils can express and/or release numerous cytotoxic substances, which is an oxygen independent mechanism. Three categories of granules, including azurophil granules, specific granules and gelatinase granules, are discharged during the degranulation process and are recognized as the basis content of their enzyme. Apart from these classical granules, neutrophils contain highly mobilizable secretory vesicles that serve as a reservoir primarily

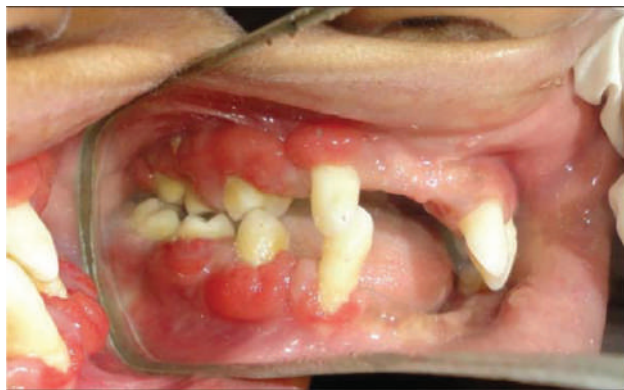

Fig 4: Periodontitis in Chediak Higashi syndrome

for plasma membrane receptors. The most common antimicrobial action is disruption of the integrity of the bacterial cell membrane. Also other antimicrobial mechanisms like destruction of peptidoglycan (lysozyme), iron sequestration (lactoferrin, neutrophil gelatinase-associated lipocalin (NGAL) and degradation of proteolytic bacterial virulence factors (elastase) are also employed.¹¹ In hypoxic periodontal pockets, the nonoxidative mechanisms are critical although neutrophils may be capable of generating ROS in periodontal pockets with oxygen content as low as 1-3%.

Reactive Oxygen Species Production

The oxygen-dependent mechanisms involve a non-mitochondrial generation of reactive oxygen species (ROS). Upon activation of neutrophils the transmembrane and cytosolic subunits of the large NADPH oxidase complex assemble at the phagosomal membrane and transfer electrons to molecular oxygen producing superoxide (O₂⁻) which reacts to H₂O₂, which in turn is the substrate for of MPO to form hypochlorous acid (HOCL). HOCL is the most bactericidal antioxidant in neutrophils which in turn can inactivate membrane proteins and the origin of replication site for DNA synthesis.¹²

Neutrophil Extracellular Traps

The activated neutrophils can also evade the microbes by an extracellular mechanism – Neutrophil Extracellular Traps. Discovered in 2004 by Brinkmann et al, they are complexes of nuclear or mitochondrial DNA together with proteins such as histones, cell-specific enzymes (myeloperoxidase or elastase) and antimicrobial peptides (e.g, cathelicidins).¹³ An initial and important step in NET production by activated neutrophils is the generation of ROS following assembly of (NADPH) oxidase. Following neutrophil activation and peptidyl arginine deiminase-4 activation, the nuclear chromatin decondenses and combines with granule proteins in the cytoplasm.¹⁴ Chromatin-protein complexes are then released in the extracellular space as NETs.

The Defence Repertoire of NETs

The Neutrophil Extracellular Traps constitute a very efficient defence mechanism in the arsenal of neutrophils due its antibacterial, antiviral, antifungal

and even its antitumorigenic effects. NET-associated proteases, such as granule-derived NE, can elicit bactericidal activity and can degrade bacterial virulence factors. Almost all types of pathogens can be trapped even those so large that they cannot be phagocytosed, including gram-positive and gram-negative bacteria, yeasts, viruses and protozoan parasites. Notably, NET-bound calprotectin S100A8/A9 confers antifungal properties against *C. albicans*. NETs may therefore represent an efficient activator of specific immunity.¹⁵ On the other hand, Cifcibasi et al. proposed that this may contribute to the proposed role of T cells and their secreted proinflammatory molecules damaging periodontal tissues.

NETs in Pathology

Apart from their beneficial interferences, their ineffective clearance or excessive formation can cause several pathological effects. Excessive NET production is counter-productive and can contribute to pathological conditions. In such situations, nets provide a source of autoantigens in autoimmune diseases and contribute to tissue damage.¹⁶ NET formation was thus observed during chronic inflammatory disease (atherosclerosis), autoimmune diseases (SLE), in diverse forms of vasculitis, thrombosis, transfusion-related acute lung injury (TRALI) and in cancer.¹⁷

Neutrophil Defects

The importance of neutrophils for maintaining healthy oral tissues is underscored by the fact that severe forms of periodontitis develop in all congenital conditions with deficiencies in neutrophil numbers and function. The defects in neutrophils can be broadly classified into qualitative and quantitative defects.

Quantitative Neutrophil Defects

A. Neutrophilia- Increased count of circulating neutrophils. Quantitative defects can be at the bone marrow like in Kostman syndrome (OMIM-Online Mendelian Inheritance in Man 610738) and Felty's syndrome or at the periphery as in Lazy leukocyte syndrome.

B. Neutropenia- Decreased count of circulating neutrophils-A relative deficiency in neutrophil number can dramatically increase susceptibility to infectious diseases. Defects in the functions of neutrophils or a marked decrease in the number of neutrophils capable of responding to the site of infection may result in varying degrees of susceptibility to infection.

There are three general guidelines used to classify the severity of neutropenia based on the Absolute Neutrophil Count (ANC) measured in cells per micro liter of blood:

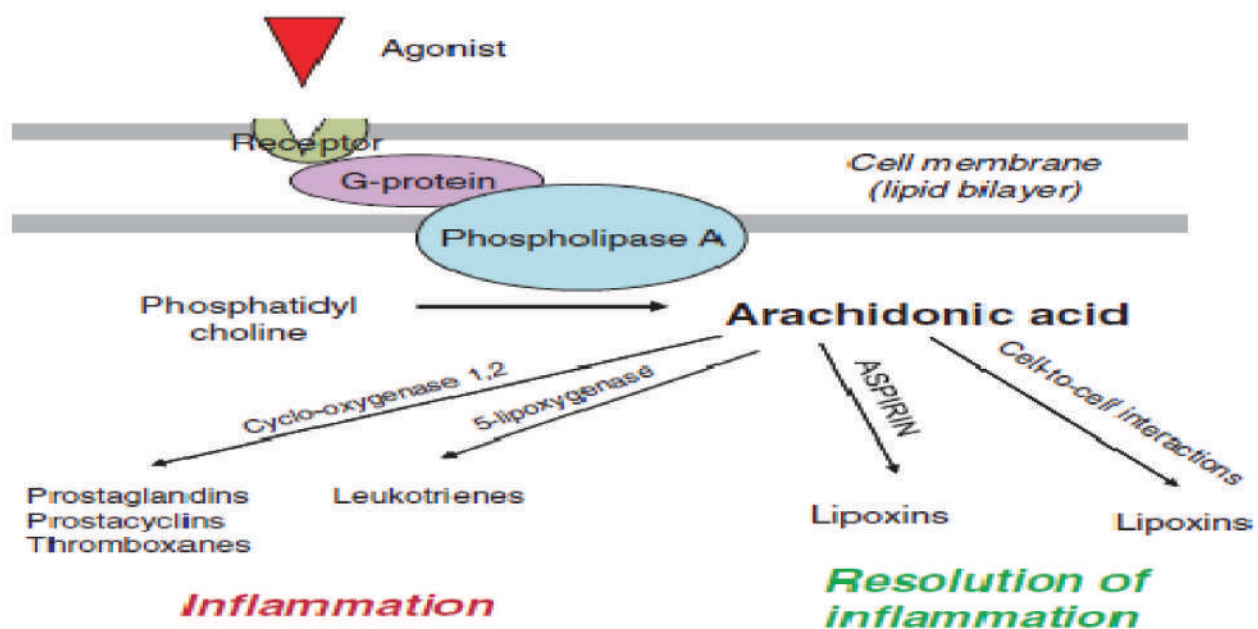


Fig 5: Resolving excessive inflammation in periodontitis

- Mild neutropenia ($1000 \leq \text{ANC} < 1500$) — minimal risk of infection
- Moderate neutropenia ($500 \leq \text{ANC} < 1000$) — moderate risk of infection
- Severe neutropenia ($\text{ANC} < 500$)

Other syndromes that are associated with decreased neutrophil counts and periodontal destruction include Herman sky–Pudlak syndrome and Shwachman–Diamond syndrome. All syndromes present with wide spread and early periodontal tissue destruction. Severe risk of infection.¹⁸

Qualitative Neutrophil Defects

These can be defects in rolling and adhesion like Leukocyte adhesion deficiency syndrome, defects in migration and chemotaxis (Hyperimmunoglobulin E syndrome), lazy leukocyte syndrome, Papillon-Lefevre syndrome, Down's syndrome, Kindler syndrome) and defects in phagocytosis and intracellular killing like Chediak Higashi syndrome¹⁸ (Fig 5).

Neutrophils in periodontal disease

The concept of host susceptibility has led to a paradigm shift in our understanding of the etiology of periodontal disease. Namely, periodontal destruction is not caused by bacterial plaque per se, but rather by the host' inflammatory response in which the neutrophils play a pivotal role.

An alteration in the balance, dysbiosis, of bacteria oral microbiota paves the initial trigger for periodontitis. The accumulation of bacteria biofilm leads to an increase in the inflammatory infiltrate, which is mainly constituted by neutrophils in oral tissues, preventing bacteria from invading deeper tissues. Thus, lack of neutrophils leads to severe periodontitis. Unfortunately, excess of neutrophils seems also to be detrimental by maintaining anti-inflammatory state that leads to tissue destruction. Some oral bacteria have developed town strategies to dismantle neutrophils function in order to increase the inflammation state and to promote their persistence in periodontitis.

Low neutrophil counts have not been demonstrated in either chronic or aggressive forms of periodontitis. However defects in neutrophil chemotaxis

was observed in aggressive periodontitis patients. This could be due to (i) reduced number of receptors on the neutrophil cell membrane, (ii) an inherent or acquired defect in the f-Met-Leu-Phe membrane receptor itself and/or coreceptors for the f-Met-Leu-Phe receptor such as GP110 (glycoprotein 110) or CD38 that facilitate and enhance the chemotatic response or (iii) a combination of both. Impaired phagocytosis and killing in patients with localized or generalized aggressive periodontitis compared to individuals with chronic periodontitis were also reported.¹⁹

The role of neutrophils in the periodontal disease development, have been explained over the years with two prominent mechanisms ie; the impaired neutrophil and the hyperactive neutrophil. However, now a third category could also explain the same, which is chronic recruitment and activation of the normal neutrophil.¹⁷ As such, with current available evidence none of the proposed hypo- or hyper-reactive traits of polymorphonuclear neutrophils is necessarily true for every periodontitis case. It has been postulated that even normal neutrophils which persist in the periodontal region are sufficient to induce tissue damage. The death of neutrophils occurs via necrosis, and this lipopolysaccharide-mediated effect can be one of the major mechanisms by which neutrophils inflict collateral tissue damage.²⁰ Thus neutrophils can act in periodontal disease in double edged sword manner, a blessing and bane at the same time.

NETs in Periodontitis

NET formation by neutrophils helps in the containment of the infection along with decreasing the inflammation by releasing anti-inflammatory lipoxins and lowering pathogen load. Vitkov et al. demonstrated that NETs were abundant in pus exudate harvested from periodontal pockets and associated with the periodontal pocket epithelium of chronic periodontitis patients. Conversely, it is conceivable that periodontal disease may associate with an excessive production of NETs, consistent with the theory that patients exhibits a 'hyperreactive phenotype'.¹⁷ Unifying the two hypotheses (hyper- and hypo-active NET production) is the possibility that the degradation and evasion of NETs by virulent periodontal pathogens may cause neutrophils to respond by up-regulating the release

of NETs, resulting not in the trapping of bacteria but instead the immobilisation and localisation of neutrophils responsible for periodontal tissue destruction.

Bacterial Control of Neutrophil Function

The progression from health to periodontitis is now explained as the transition from a symbiotic microbiota to a polymicrobial dysbiotic microbiota. Risk factors, such as smoking, tissue injury, diet changes, an immunocompromised host, or the colonization of the oral cavity by pathogenic bacteria can modify the oral ecosystem resulting in a dysbiotic polymicrobial community. This Polymicrobial dysbiotic microbiota has an arsenal of self-defence mechanisms, which can be directed to attack against neutrophils or camouflage the biofilm.²¹ The strategies for evading neutrophil killing include: (i) Launching a general survival response such as in group A streptococci (GAS) (Voyich et al. 2003). (ii) Avoiding contact by secretion of chemotaxis inhibitory protein (*S. aureus*; de Haas et al. 2004). (iii) Preventing phagocytosis by secretion of actin polymerisation inhibitors (*Yersinia enterocolitica*) (Grosdent et al. 2002). (iv) Release of exotoxins e.g. leukotoxin from *A. actinomycetemcomitans* (Baehni et al. 1979). (v) Surviving intracellularly e.g. *P. gingivalis* within oral epithelial cells (Lamont et al. 1995). (vi) Inducing cell death such as GAS which produce streptolysin O (Sierig et al. 2003). (vii) Avoiding killing by NETs such as deoxyribonuclease (DNase) expression by *Streptococcus pyogenes* (Buchanan et al. 2006). (viii) the production of bacterial surfactants by *P. aeruginosa* biofilms causes rapid cell death in neutrophils. *T. denticola* limits neutrophil chemotaxis, and inhibits junctional epithelial cells to secrete IL-8. NET formation within *Haemophilus influenzae* biofilms does not harm the biofilm due to their expression of certain lipooligosaccharide glycoforms, which shield pathogen-associated molecular patterns (PAMPs) and thus inhibit recognition and opsonization.²¹

Diabetes Mellitus

Mowat and Baum showed for the first time that the chemotactic activity of neutrophils from diabetic patients is significantly lower than in cells from healthy controls.²² Several aspects have been shown to be impaired during inflammation in diabetes mellitus. These include decreased microvascular responses to

inflammatory mediators, decreased protein leakage and edema formation, reduced mast cell degranulation, decreased leukocyte-endothelial cell interactions, reduced number of leukocytes in inflammatory lesions, low superoxide generation, reduced release of inflammatory cytokines and low content of arachidonic acid in neutrophils. Furthermore, reduction in leukocyte phagocytosis and bactericidal activity showed a significant correlation with increases in blood glucose levels. Possible explanation for the abnormal leukocyte function in diabetes mellitus might be a down-regulation of adhesion molecules that regulate leukocyte recruitment during the course of inflammatory processes.²³

Smoking

Tobacco smoke is known to exert profound effects on neutrophils. Cigarette smoke condensate (CSC) is believed to be a powerful inducer of inflammatory responses. According to a study by Gunstch et al, crevicular neutrophil viability has been shown to be consistently reduced in smokers (75% viable) compared to non-smokers (85% viable), with phagocytotic capacity also diminished in a potentially dose-dependent manner (40% in heavy smokers; 79% in non-smokers).²⁴ Tobacco smoke exposure induces systemic neutrophilia and causes compromised neutrophil maturation and inefficient effector function as there is tobacco-induced induction of neutrophil-derived elastase and metalloproteinase release. This in combination with compromised phagocytotic and bacteriocidal capacities, is produced like a diminished ability to kill *P. gingivalis* and impaired chemotactic responsiveness. Tobacco smoke and components can directly or indirectly alter innate cell death processes. For example, Aoshiba et al. reported that nicotine alone could suppress neutrophil apoptosis in a dose-dependent manner. Neutrophils express functional receptors for nicotine and cotinine, as well as tobacco-derived aryl hydrocarbons. Neutrophils also express receptors for several endogenous immunomodulatory factors that have been shown to be dysregulated in tobacco smokers.

Aging Subjects

As aging occurs, there is increased susceptibility to multiple infectious diseases, as immune senescence occurs. The acute inflammation associated with

gingivitis may even show increased severity in aging subjects. As there are limited number of studies, the functions of neutrophils examined like expression of key receptors, apoptosis, chemotaxis, phagocytosis, etc shows that chemotaxis, phagocytosis and signalling via calcium dependent pathway are impaired in aged people.²⁵ This may in turn cause an elevated susceptibility to periodontal infections.

Modulating Neutrophil responses- Therapeutic approaches?

Considering the alterations of neutrophil functions in aggressive and chronic periodontitis, one of the recently developing and most promising approaches concentrate on modulating the destructive aspects of the neutrophil host response.

Cytokines as targets for immunomodulation therapy

Some cytokines have pro-inflammatory effects, for example interleukin-1, tumor necrosis factor-alpha, interleukin-6, interleukin-8 and interleukin-12, whereas others have anti-inflammatory effects, for example interleukin-1 receptor antagonist, interleukin-4, interleukin-10 and transforming growth factor-beta. During active periodontitis Interleukin-1 and tumor necrosis factor alpha are present at high concentrations in periodontal tissues, where they are catabolically active in stimulating bone resorption and the counts are reduced following mechanical debridement.²⁶ TNF alpha agonists include Adalimumab, Cetrolizumab Entanercept, Golimumab, Infliximab, IL 1 antagonist like Riloncept etc.

Inhibiting Excessive Neutrophil Extravasation

Another novel way of neutrophil modulation is limiting its extravasation by candidates like pentraxin – 3 and Del – 1. Pentraxin-3, is produced by macrophages, dendritic cells, neutrophils etc in response to inflammatory stimuli. In a mouse model of acute lung injury, pentraxin-3 dampened neutrophil recruitment into the lungs, preventing excessive neutrophil-induced tissue injury.²⁷ Thus, pentraxin-3 may have similar potential in periodontitis; another inflammatory disease however, no animal or human studies exist for the same.

Developmental endothelial locus-1 is a 52-kDa

glycoprotein secreted by endothelial cells and has been identified as a negative regulator of neutrophil extravasation. It antagonizes the CD11a/CD18 (lymphocyte function-associated antigen 1) mediated adhesion onto the vascular endothelium. It could be administered to inflamed tissues, to reduce neutrophil recruitment, and to reduce inflammation. Preclinical studies for the use of Del-1 are now underway.²⁶

Immune Modulators for Inhibiting Excessive Neutrophil Degranulation

The only currently approved treatment for periodontitis with evident effects on neutrophil degranulation is the administration of Subantimicrobial Doses of Doxycycline whose working mechanism is the inhibition of neutrophil-derived matrix metalloproteinase-8 (collagenase). And it is especially true in patients with higher susceptibility for periodontitis, such as smokers and those with diabetes and osteoporosis. In addition to improvement of the periodontal condition, systemic effects of subantimicrobial doses of doxycycline have also been shown, such as the reduction of hemoglobin A1c in subjects with diabetes and reduction of C-reactive protein in patients with acute coronary syndrome.²⁸

Diet to Limit deleterious effects of ROS

Several micronutrients with antioxidant capacities like Vitamin C, E, Carotenoids, polyphenols, bilirubin etc have been studied in relation to periodontitis. Over the years, an inverse correlation between their serum concentration such as vitamin C, and the prevalence and severity of periodontitis has been confirmed in different populations. Based upon available evidence, the most appropriate advice to offer patients with periodontitis is to increase consumption of antioxidants through consumption of natural whole food.²⁹

Resolving excessive inflammation in periodontitis

Apart from pro inflammatory and tissue destructive products like prostaglandins, products from arachidonic acid pathway like lipoxins and resolvins have shown anti-inflammatory / tissue protective effects. (Fig 6)

Having been tested in animal models, topical application of lipoxin-4 reduced polymorphonuclear

neutrophil infiltration, dampened the neutrophil-mediated tissue degradation and, by doing so, prevented bone loss. In the same animal model, resolvin E1, caused reduced neutrophil infiltration and bone loss and tissue damage by 95%.³⁰

Conclusion

Oral tissues require a constant surveillance by neutrophils in order to remain healthy. When alterations in the neutrophil homeostasis develop various forms of periodontitis appear. Defects in recruitment and proper function of neutrophils may lead to periodontitis, albeit through different mechanisms. The relationship is equivalent to the proverbial double edged swords. In the emerging field of periodontal medicine, promising new treatment methodologies have been suggested which coalesce patient education and motivation, reduction of the bacterial burden, host-response modulation and risk-factor modification. The precise treatment scheme for individual patients will be defined by the periodontal specialist or general practitioner after careful diagnosis and risk assessment.²⁸ Although doubts persist regarding optimizing treatment efficacy while limiting any potential adverse effects, the evidence clearly suggests strong prospects for the modulation of the host response in aiding disease management, when coupled with traditional mechanical therapy.

References

1. DA Scott; J Krauss .Neutrophils in periodontal inflammation. *Front Oral Biol*, 2012, 15, 56-83.
2. Borregaard N. Neutrophils, from Marrow to Microbes. *Immunity*. 2010;33(5):657-670.
3. Leiding W J. Neutrophil Evolution and their Diseases in Humans. *Frontiers in Immunology*.2017;8:1009.
4. Furze C R, Rankin M S.Neutrophil mobilization and clearance in the bone marrow. *Immunology*. 2008; 125: 281-288.
5. Kruger P, Saffarzadeh M, Weber ANR, Rieber N, Radsak M, von Bernuth H, et al. Neutrophils: Between Host Defence, Immune Modulation, and Tissue Injury. *PLoS Pathog* 2015; 11(3): e1004651
6. Kolaczowska E, Kubes P: Neutrophil recruitment and function in health and inflammation. *Nat. Rev. Immunol*. 2013; 13:159–175.
7. Nussbaum G, Shapira L. How has neutrophil research improved our understanding of periodontal pathogenesis? *J Clin Periodontol* 2011; 38: 49.
8. Eskan MA, Jotwani R, Abe T, Chmelar J, Lim JH, Liang S, Ciero PA, Krauss JL, Li F, Rauner M et al: The leukocyte integrin antagonist Del - 1 inhibits IL-17 mediated inflammatory bone loss. *Nat. Immunol*. 2012; 13:465–473.
9. Williams M, Azcutia V, Newton G, Alcaide P, Luscinskas F. Emerging mechanisms of neutrophil recruitment across endothelium. *Trends in Immunology*. 2011;32(10):461-469.
10. Nourshargh S, Renshaw S, Imhot M. Reverse Migration of Neutrophils: Where, When, How, and Why? *Trends in Immunology*.2016;37:273-286.
11. Curtis MA, Zenobia C, Darveau RP: The relationship of the oral microbiota to periodontal health and disease. *Cell Host Microbe* 2011 10:302–306.
12. Pham CT: Neutrophil serine proteases: specific regulators of inflammation. *Nat. Rev. Immunol*. 2006 6:541–550.
13. Urban C F, Lourido S, Zychlinsky A. How do microbes evade neutrophil killing. *Cell Microbiol* 2006 8:1687- 1696.
14. Brinkmann V, Reichard U, Goosmann C, Fauler B. Uhlemann Y et al Neutrophil Extracellular Traps Kill Bacteria. *Science*. 2004. 303: 1532 – 1535.
15. Urban C, Ermert D, Schmid M, Abu-Abed U, Goosmann C, Nacken W et al. Neutrophil Extracellular Traps Contain Calprotectin, a Cytosolic Protein Complex Involved in Host Defense against *Candida albicans*. *PLoS Pathogens*. 2009; 5(10):e1000639.
16. Vitkov L, Hartl D, Minnich B, Hannig M. Janus-Faced Neutrophil Extracellular Traps in Periodontitis. *Front Immunol*. 2017; 8:1404.
17. Ryder MI: Comparison of neutrophil functions in aggressive and chronic periodontitis. *Periodontol*2000 2010; 53:124–137.
18. Manjari Lalwani, Suchetha A., Darshan B. Mundinamane, Sapna N., Divya Bhat and Chitra Jayachandran Neutrophil associated syndromes and periodontitis] *Journal of Chemical and Pharmaceutical Research*, 2016, 8(2):421-427.
19. Hajishengallis E, Hajishengallis G. Neutrophil homeostasis and periodontal health in children and adults. *J Dent Res*. 2014;93(3):231-237.
20. Crawford JM, Wilton JM, Richardson P. Neutrophils die in the gingival crevice, periodontal pocket, and oral cavity by necrosis and not apoptosis. *J Periodontol* 2000; 71: 1121–1129.
21. Cortés-Vieyra R, Rosales C, Uribe-Querol E. Neutrophil Functions in Periodontal Homeostasis. *Journal of Immunology Research*. 2016:1-9.
22. Mowat A, Baum J. Chemotaxis of polymorphonuclear leukocytes from patients with diabetes mellitus. *N Engl J Med* 1971; 284: 621-627.
23. Alba-Loureiro TC, Hirabara SM, Mendonca JR, Curi R, Pithon-Curi TC. Diabetes causes marked changes in function and metabolism of rat neutrophils. *J Endocrinol* 2006; 188: 295-303.
24. Guntch A, Erler M, Preshaw PM, Sigusch BW, Klinger G, et al. Effect of smoking on crevicular polymorphonuclear neutrophil function in periodontally healthy subjects. *J Periodont Res* 2006; 41: 184-188.
25. Hajishengallis G. Too old to fight? Aging and its toll on innate immunity. *Mol Oral Microbiol*. 2010; 25(1):25–37.
26. Nicu A .E, Loos . G .B Polymorphonuclear neutrophils in periodontitis and their possible modulation as a therapeutic approach *Periodontology* 2000. 2016;71:140–163.
27. Deban L, Russo RC, Sironi M, Moalli F, Scanziani M, Zambelli V, Cuccovillo I, Bastone A, Gobbi M, Valentino S, Doni A, Garlanda C, Danese S, Salvatori G, Sassano M, Evangelista V, Rossi B, Zenaro E, Constantin G, Laudanna C, Bottazzi B, Mantovani A. Regulation of leukocyte recruitment by the long pentraxin PTX3. *Nat Immunol* 2010; 11: 328– 334.
28. Preshaw PM, Hefthi AF, Jepsen S, Etienne D, Walker C, Bradshaw MH. Subantimicrobial dose doxycycline as adjunctive treatment for periodontitis. A review. *J Clin Periodontol* 2004; 31: 697–707.
29. Van der Velden U, Kuzmanova D, Chapple ILC. Micronutritional approaches to periodontal therapy. *J Clin Periodontol* 2011; 38: 142–158.
30. Hasturk H, Kantarci A, Ohira T, Arita M, Ebrahimi N, Chiang N, Petais NA, Levy BD, Serhan CN, Van Dyke TE. RvE1 protects from local inflammation and osteoclast-mediated bone destruction in periodontitis. *FASEB J* 2006; 20: 401–403.

Free gingival Graft – The Silver bullet in Periodontal Plastic Surgery

Binitta Paul K¹, Jose Paul², Johnson Prakash d'lima³, Senny Thomas Parackal³, Deepak Thomas⁴, Syed Mohammed Jiffry C.A⁵

ABSTRACT

Periodontal plastic surgery is a broad term that includes different sophisticated techniques which provide the solution for multitude of aesthetic and functional problems. Free gingival graft even though it is an ancient classic technique, it still remains as predictable solution for various mucogingival problems. This case report discusses the excellent results achieved from a simple technique and the factors as well as modifications that are relevant for the successful outcome.

Key Words: free gingival graft, periodontal plastic surgery, attached gingiva

Introduction

Periodontal plastic surgery has gained wide attention in the current clinical scenario due to increased patient awareness and the demand for perfect aesthetics. It addresses a multitude of areas which were not addressed in the past including periodontal–prosthetic corrections, crown lengthening, socket preservation, ridge augmentation, esthetic surgical corrections, coverage of the denuded root surface, reconstruction of papillae, esthetic surgical correction around implants, surgical exposure of unerupted teeth for orthodontics and many more.

Periodontal plastic surgery is defined as the surgical procedures performed to correct or eliminate anatomic, developmental or traumatic deformities of gingiva or alveolar mucosa.^{1,2} The five problems for which periodontal plastic surgery primarily caters is inadequate or lack of attached gingiva, gingival recession, shallow vestibule, aberrant frenum and various esthetic deformities of the gingiva. Surprisingly the age old technique of Free gingival auto graft which was

pioneered by Bjorn in 1963 still plays a pivotal role in solving multitude of these problems using the simple yet classy technique.

Case Report

A patient reported to Department of periodontics with the chief complaint of sensitivity of lower front tooth. On examination patient had Millers Class II gingival recession of 4mm along with inadequate attached gingiva in relation to 31. Clinically stretching of lower lips moved the marginal gingiva in relation to 31 indicating inadequate attached gingiva and patient had inadequate vestibular depth for proper oral hygiene maintenance. After completion of phase I therapy, Free gingival auto graft was planned to cater all the mucogingival problems of the patient.

In this case, the Classic technique of Free gingival graft was adopted. Root surface was thoroughly planed. After proper anaesthesia, recipient site was prepared making a horizontal incision in the interdental papillae. Vertical incision was placed at the proximal line

¹Senior Lecturer, ²Professor and HOD, ³Professor, ⁴Reader, ⁵Lecturer, Department of Periodontics, Annoor Dental College. Corresponding Author: Dr. Binitta Paul K E-mail: binitta.paul.anand@gmail.com

angles of the adjacent teeth and the retracted tissue was excised. Aberrant frenum was also excised along with the tissue. An aluminium foil was placed to act as a template in harvesting the graft from palatal site.

The palatal region near the premolar molar region is selected. After adequate anesthesia is achieved, outline of graft is marked using a No. 15 blade. An ideal graft of 1.5 mm is harvested. It was immediately

transferred to the recipient site, adapted and sutured using Ethicon 5.0 Vicryl suture material. It was ensured that the graft was completely immobile. The recipient site was protected using CoE Pak. Complete hemostasis was achieved in the donor site. Post-operative instructions were given and the patient was reviewed after a week. Excellent results were obtained in further follow up.

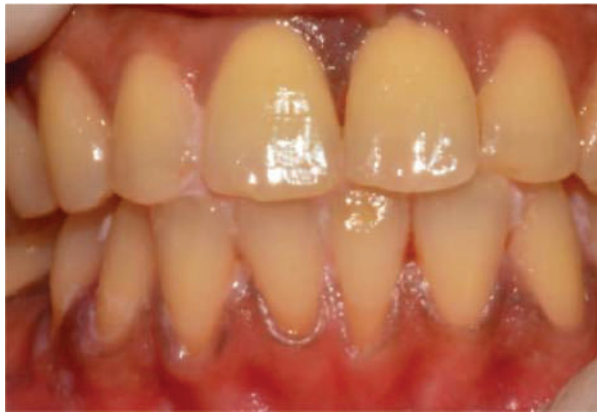

Fig 1: Pre operative

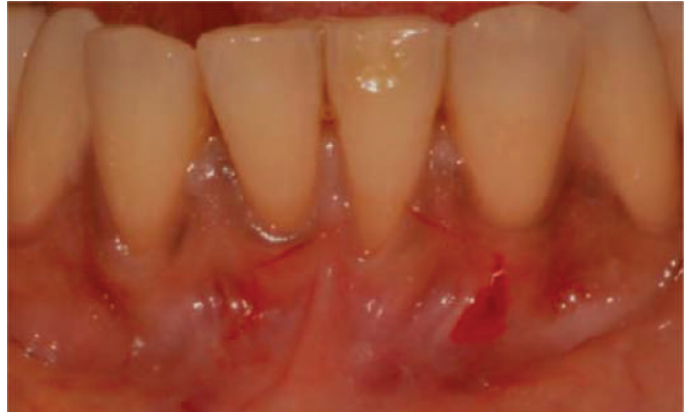

Fig 2a: Incisions given

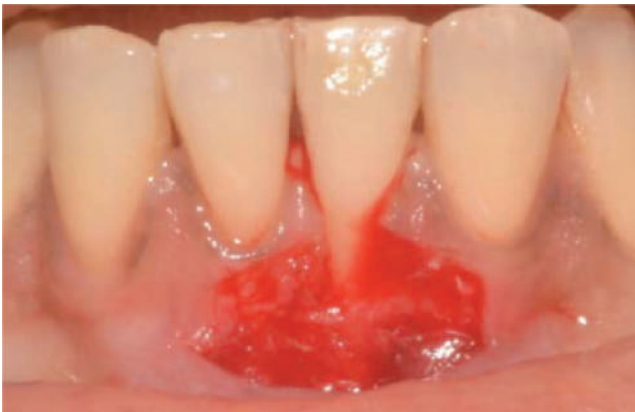

Fig 2b: Recipient site prepared

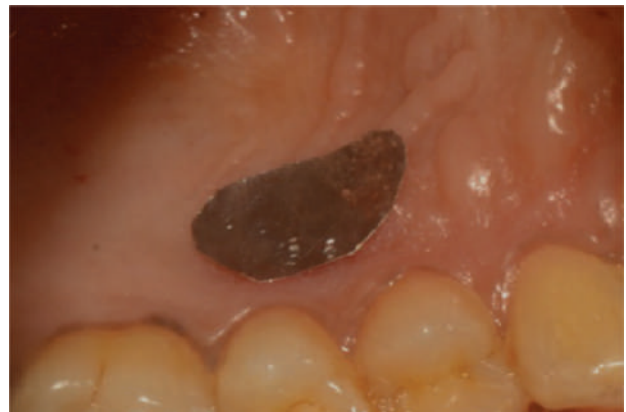

Fig 2c: Tin foil template adapted in donor site

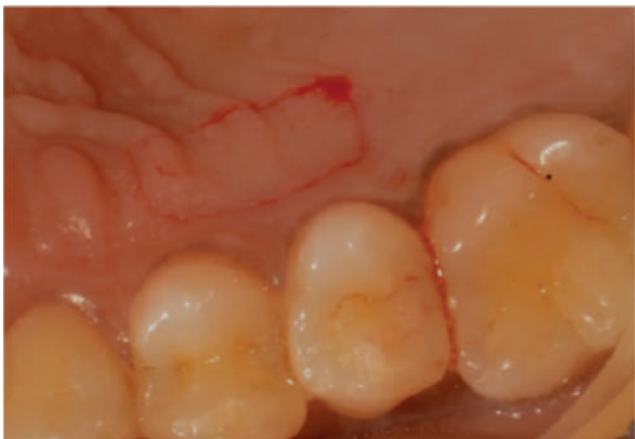

Fig 2d: Incision placed

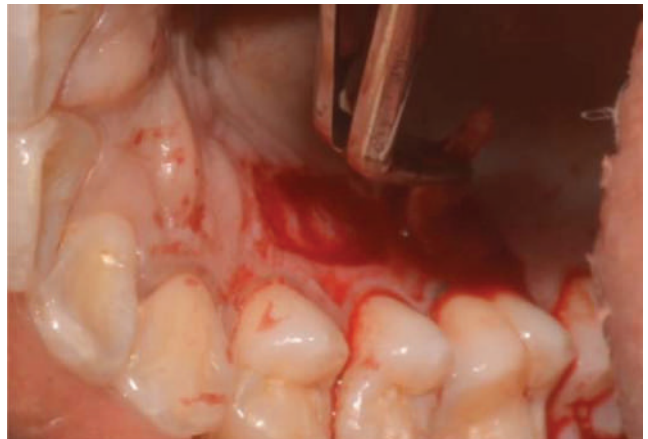

Fig 2e: Graft harvested

Discussion

Full coverage of recession defect with excellent color match with the adjacent gingiva was obtained with minimum probing depth. Complete resolution of sensitivity was achieved along with adequate width of attached gingiva. Patient was able to maintain plaque control as she could brush without sensitivity.

FGG continues to be the most predictable method to increase the dimension of the keratinized mucosa. The need of adequate attached gingiva still remains a controversy. Lang and Loe suggested that 2 mm of attached gingiva is essential for optimal periodontal health, Miyasato et al demonstrated that with proper oral hygiene and absence of bacterial plaque, clinically healthy gingiva can exist in areas with minimal or no attached gingiva. According to Camargo et al it is commonly accepted that areas with less than 2mm of attached gingiva are at a higher risk for recession. FGG can also be used in treatment of gingival recession combined with lack of vestibular depth and for

teeth requiring restoration with sub gingival margins.⁶ The presence of progressive gingival recession and inflammation even after a few months of effective plaque control is a clear indication for the use of free gingival graft in root coverage procedure.

High esthetic demand and need for an intraoral donor site are stated to be a drawback of this technique. Increased post-operative bleeding from the donor area may be a disadvantage and later it heals by secondary intention. Unpredictable color match between the grafted tissue and the adjacent gingival tissues which may persist years after the surgery may occur. Rugae in the donor site may compromise the aesthetic results.⁶ In some cases an exostosis can occur beneath the periosteum after this procedure which is thought to be caused by stimulation of surgical wound by surgical trauma.

Factors to be considered with extreme relevance are maintenance of adequate blood supply to the area and selection of case for root coverage according to

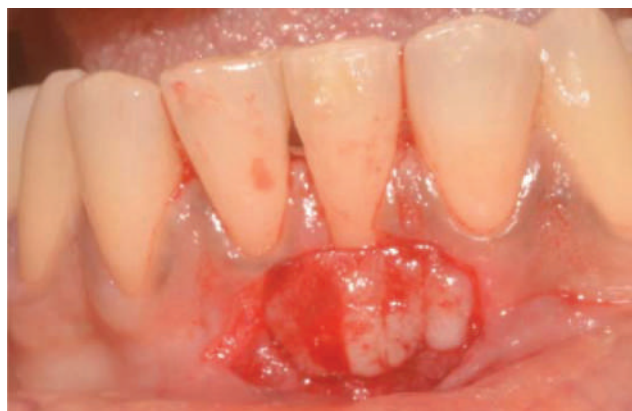

Fig 2f: Graft adapted

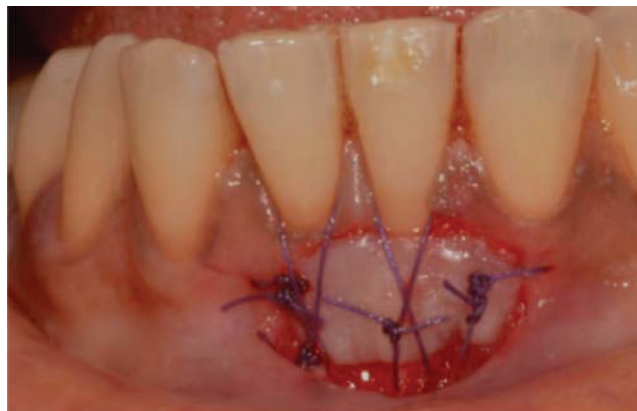

Fig 2g: Suture placed

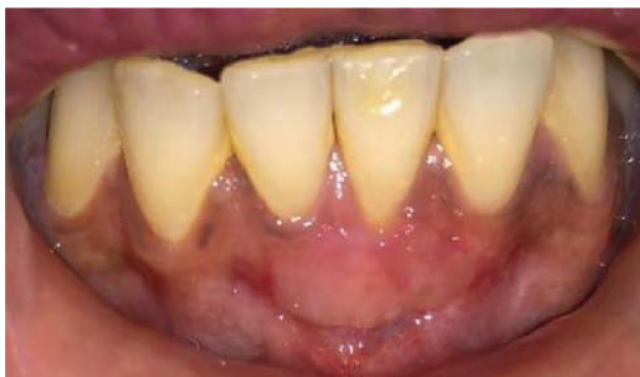

Fig 3: 2 weeks post operative healing

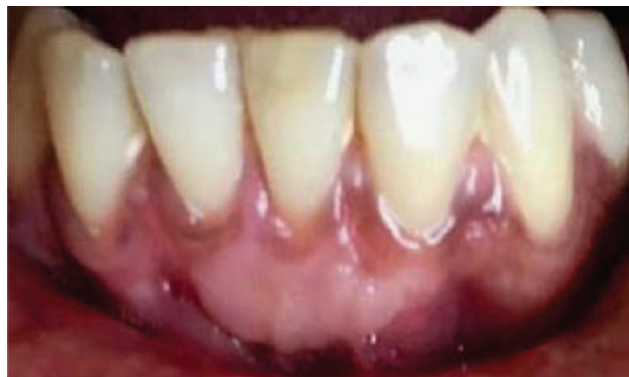

Fig 4: 2 months post operative

Millers criteria. Wide interdental papillae can provide abundant blood supply to the area.⁶ The butt joint type of incision as well as vertical incisions that start close to the line angles of the adjacent teeth help in avoiding dead space caused by beveling as well as including wide surgical papillae.⁶ The size of graft must be adequate to contact the periphery of recipient site. The ideal thickness of graft is between 1.0 to 1.5 mm. But according to Camargo⁶ et al the thickness of graft may be increased for root coverage purposes. The stabilization and immobilization of graft as well as the protection from trauma during early healing period is crucial in graft survival.^{6,10} However the patients who smoke has a higher correlation with graft failure.^{6,10}

Alternative techniques mentioned in literature were the Accordion technique, strip technique and the combination of Epithelium and connective tissue strip technique. Esthetic result of the free gingival graft can range from very poor to excellent. Recently modified techniques like partly epithelized FGG (PE-FGG), gingival unit graft and epithelized sub epithelial connective tissue graft were introduced to overcome the limitations of FGG.

Even though other materials like lyophilized duramater, sclera, acellular dermal matrix (ADM), Gintuit (living cell construct) and others are used, FGG can never be an obsolete technique. The alternative grafting materials offer unique advantages like the elimination of donor site, unlimited supply, reduced surgical time but need studies with long term follow up if we need to completely eliminate this age proven technique.

Conclusion

This technique resulted in predictable coverage of the denuded root surface. In the present case adequate color matching was obtained with complete root coverage, gain in attached gingiva, complete removal of aberrant frenum and gain in vestibular depth. FGG is still a single solution for a multitude of problems.

References

1. American Academy of Periodontology: Proceedings of the World Workshop in Clinical Periodontics. In Annals of Periodontology, Chicago, 1989, The Academy.
2. American Academy of Periodontology: Proceedings of the World Workshop in Clinical Periodontics. In Annals of Periodontology, Chicago, 1996, The Academy.
3. Bjorn H: Free transplantation of gingiva propria, Sveriges Tandlak T 22:684,1963.
4. Lang NP, Loe H. The relationship between the width of keratinized gingiva and gingival health. J Periodontol 1992;43:623-627.
5. Miyasato M, Crigger M, Egelberg J. Gingival condition in areas of minimal and appreciable width of keratinized gingival. J ClinPeriodontol 1977; 4:200-209.
6. Camargo PM, Melnick PR, Kenney EB. The use of free gingival grafts for aesthetic purposes. Periodontol 2000 2001;27:72-96.
7. Remya V, Kishore Kumar K, Sudharsan S, Arun KV. Free gingival graft in the treatment of class III gingival recession. Indian J Denat Res 2008;19:247-252.
8. Pack AR, Gaudie WM, Jennigs AM. Bony exostosis as a sequela to free gingival grafting: two case reports. J Periodontol 1991; 62:269-271.
9. Otero-Cagide FJ, Singer DL, Hoover JN. Exostosis associated with autogenous gingival grafts: A report of 9 cases. J Periodontol 1996;67:611-616.
10. Miller PD Jr. Root coverage with the free gingival graft. Factors associated with incomplete coverage. J Periodontol 1987;58:674-681.
11. Mormann W, Schaer F, Firestone AC: The relationship between the success of free gingival grafts and and transplant thickness, J Periodontol52:74,1981.
12. Pennel PM, Tabor JC, King KO, et al:Free masticatory mucosa graft, J Periodontol 40:162, 1969.
13. Silva CO, RibeiroEdelP, SallumAW, Tatakis DN. Free gingival grafts: Graft shrinkage and donor- site healing in smokers and non-smokers. J Periodontol 2010;81:692-701.
14. Rateitschak KH, Rateitschak EM, Wolff HF, et al: Color atlas of periodontology, New York, 1985, Thieme.
15. Han TJ, Takei HH, Carranza FA Jr: The strip gingival autograft technique, Int J PeriodontRestor Dent 13:181,1993.
16. Cortellini p, Tonetti M, Prato GP. The partly epithelized free gingival graft (pe-fgg) at lower incisors. A pilot study with implications for alignment of the mucogingival junction. J Clin periodontal 2012;39:674-680.
17. Allen AL. Use of the gingival unit transfer in soft tissue grafting:Report of three cases. Int J Periodontics Restorative Dent 2004;24:165-175.
18. Stimmelmayr M, Allen EP, Gernet W, Edelhoff D, Beurer F, Schlee M, et al. Treatment of gingival recession in the anterior mandible using the tunnel technique and a combination epithelized –subepithelial connective tissue graft- a case series. Int J Periodontics Restorative Dent 2011; 31: 165-173.

Barrier membranes: How well they navigate cells?

Hemalatha DM¹, Anil Melath², Mohammed Feroz TP³, Subair K⁴, Ashitha M⁵, Nanditha Chandran⁶

Introduction

Oral health and well-being is considered as an essential necessity for overall wellness. Gingivitis and periodontitis are most primary cause of oral health deterioration. Improper and inadequate oral hygiene enhances plaque and calculus accumulation thereby leading to gingival and periodontal diseases. Periodontitis commences with periodontal pocket formation. Treatment of periodontitis eventually focuses on periodontal pocket reduction or elimination procedures.¹

Treatment of periodontal pockets had a dramatic change in 1980's when it was proved that, certain specific tissue handling procedures resulted in attachment gain. Periodontal diseases and periodontitis are plaque associated usually and surgical procedures of periodontology are often selected based on their potential to aid in sub-gingival plaque removal. Surgical periodontology is the third phase of treatment planning.²

Apart from granulation tissue removal these access therapy procedures increased chances of attachment gain. These procedures are performed as respective surgeries or regenerative surgeries. Intra-bony defects undergo regenerative treatment, for which a regenerative material is condensed into the defect after flap elevation and complete debridement. Even after placement of graft material, there is always obscure chances to get new attachment.

According to Melcher's concept, the type of cells that populate the root surface during healing will define the type of healing tissue.³ Periodontal ligament cells, fibroblast cells from connective tissue, osteoblast cells from bone and epithelium cells are four types of cells which can populate healing root surface (Fig 1). Epithelial cells have increased proliferative rate and this rapid proliferation and progression along the

root surface results in long junctional epithelium. To overcome this epithelial attachment with periodontal ligament attachment, the concept of Guided tissue regeneration was formulated. To refrain epithelial cells from migrating apically, barrier membranes were used.

Anatomical considerations for guided tissue regeneration¹³:

1. Presence of root trunk concavity
2. Root morphology
3. Residual osseous morphology
4. Width of the intra-bony defect
5. Number of residual walls
6. Defect angle
7. Thickness of tissue for membrane coverage

Requisites

1. Biocompatible and should have high immune compatibility.
2. Act as a barrier and should exclude the unwanted cells from entering the site of interest.
3. Have good tissue integration and should provide stability to overlying flap.
4. Create and should maintain space.
5. Easy handling quality and easy to trim and adapt.
6. Clot stabilisation property.

Classification of membranes

First generation membranes: These were earliest developed membranes in 1960s and '70s, to have combined effect of high physical properties and less tissue reactions. These were not resorbable. First procedural attempt was done with cellulose acetate bacterial filter (Millipore) by Nyman et al in the year 1982. Later

¹Postgraduate student, ²Professor & Head, ^{3,4}Professor, ^{5,6}Senior Lecturer, Department of Periodontology, Mahe Institute of Dental Sciences and Hospital, Chalakkara, Mahe-653 310.

Corresponding Author: Dr. Hemalatha DM, Email: drhemalatha.uk@gmail.com

e-PTFE (Goretex) were used. Titanium reinforced ePTFE, Titanium mesh, high density ePTFE also come under this category.¹⁵

Disadvantage: Second surgical procedure for membrane retrieval.

Second generation membranes: Membranes with resorbable capacity are second generation membranes.¹⁵ They can be classified into natural and synthetic membranes.

Natural: Collagen membranes, Chitosan membranes.

Synthetic: Polyesters like poly (lactic acid) (PLA), poly (galactic acid) (PGA), and poly (caprolactone) and their copolymers.

Disadvantages:

1. Early membrane degradation
2. Premature loss of material
3. Epithelial down growth
4. Flap dehiscence
5. Inadequate physical strength

Third generation membranes: Membranes which can be used as barrier membranes and delivery devices¹⁵. Specific agents like growth factors, adhesion factor, antibiotics can be delivered through membranes eg:. Inion GTR membranes.

Modifications of membranes:

1. Antibiotic coating: Early stages of periodontal healing following GTR procedures have shown to have given untoward outcomes due to periodontal pathogens. Systemic antibiotics can be given for patients but patient compliance, antibiotic drug resistance, systemic adverse reactions etc lead to local drug administration¹¹. Antibiotic coating aimed at this radical eradication of periodontal pathogens. It has also proven to have the additive effect of increased repopulation of progenitor cells, delayed degradation of collagen etc. Bilayered PGA membrane with doxycycline and dexamethasone fibres; collagen membrane treated with doxycycline; tetracycline coated ePTFE membranes. The antibiotic coating of membrane has increased effect even in guided bone regeneration.⁸

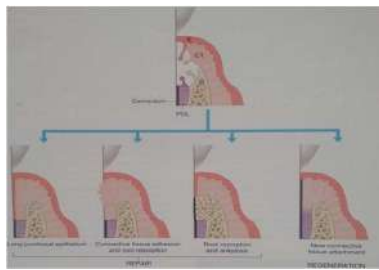


Fig. 1 Melcher's concept of periodontal regeneration.



Fig. 2: Titanium reinforced ePTFE



Fig.3: Polygalactic membrane

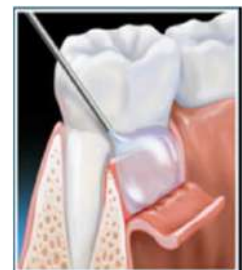

Fig. 4: Atrisorb



Fig. 5: Platelet Rich Fibrin (PRF)

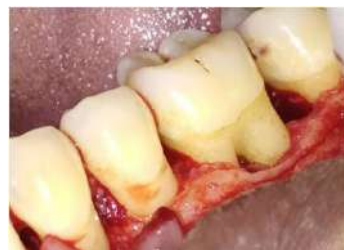

Fig.6: Elevation of full thickness flap and debridement.

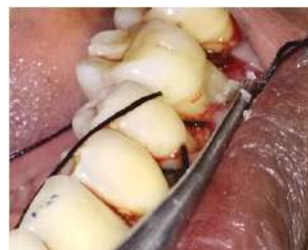

Fig. 7 : Compaction of graft material in defect

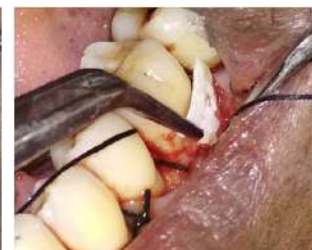

Fig. 8 : Placement of membrane

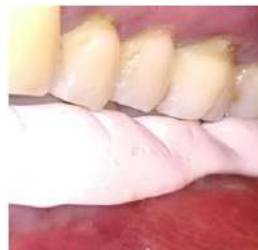

Fig. 9 : Adaptation and suturing of flap

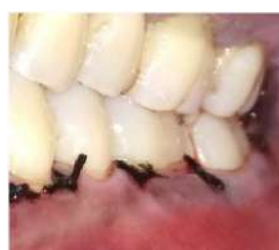

Fig.10: Periodontal Pack Placement

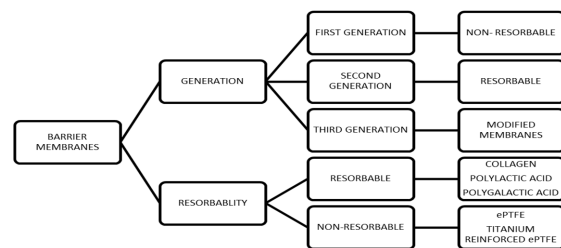


Chart 1: Classification of membranes based on generation and resorbability

2. Ion modification:

Metal and half metal molecules of silver, titanium, and silicon have been used to coat membranes for increased antibacterial activity, improved biocompatibility, prevention of epithelial migration etc. SiO₂, TiO₂ treated membranes have more cell adhesion promotion, osteoclastic and osteosynthetic activity. Plasma oxygen conditioning of membranes have also proven to have more cell adhesion property. Plasma oxygen coating with incorporation of SiO₂ increased bone regeneration capacity of the membranes.

3. Other modifications:

Membranes coated with other materials and different type of surface treatment for physical modification come under this category.² These methods are:

Surface treatment:

- a. Alginate coating
- b. Hyaluronic acid treatment
- c. Polyvinyl alcohol treatment
- d. Crystalline polypropylene treatment

Physical modification procedures:

- a. Electron beam irradiation
- b. Electro-spinning

Alginate coating:

Alginate is an anionic natural polymer, with hydrophilic properties, high biocompatibility and similar structure to extracellular matrix of living cells. Coating of chitosan membrane with alginate and glucuronic monomers have increased surface roughness. Surface treatment with alginate also increased resistance of membrane to fibroblast cell adhesion thus providing more time for osteoblast cells to proliferate. These membranes can be used in guided bone regeneration procedures also¹⁰.

Hyaluronic acid coating:

Hyaluronic acid is a natural glycosaminoglycan, widely used in medical field for its properties to enhance cell migration and promotion. It also has anti-bacterial property. Membranes are soaked in 1% hyaluronic acid for 30 minutes before procedure².

Polyvinyl alcohol coating:

Chitosan membranes are notorious for their

hydrophobicity and stiffness. To enhance their hydrophilic capacity treatment with polyvinyl alcohol has been done. Polyvinyl alcohol is nontoxic, highly wettable and has superior mechanical properties. This technique improves membrane adaptability and cell adhesion².

Crystalline polypropylene coating:

Increasing Porosity, contact angle and surface roughness increases the functional capacity of barrier membrane. Incorporation of polypropylene complements to these abilities of membrane².

Electron beam irradiation:

Linear accelerated electrons on interaction with the surface of membrane produce an increased surface roughness. Irradiation increases cell adhesion, proliferation, viability of cell attachment and accelerated material degradation after irradiation. 100 kGy or 300 kGy of irradiation is used. But increased beneficial effects seen with lesser dose of irradiation ie 100kGy².

Electro-spinning:

Electro-spinning or E-Spinning method is used to obtain a randomly oriented and highly aligned fibres in copolymers of membranes. Cell viability increases drastically by this method of membrane modification. Electrospun fibres of membranes were strongest of all fibres. This process produces scaffolds similar to extra cellular matrix¹¹.

Types of membranes:

Barrier membrane are of two types:

1. Non-resorbable membrane.
2. Resorbable membrane.

1. Non-resorbable membranes:

Expanded polytetrafluoroethylene (ePTFE) and cellulose filters are the non-resorbable membranes use in periodontal therapy. Basic structure of the molecule has four carbon – carbon bond, attached with fluorine atoms in a structure of a polymer. This compound is inert and does not cause adverse tissue reactions. After attaining adequate soft tissue healing, for about 3 to 6 weeks, membrane is removed by a second surgical procedure. This added surgical procedure for membrane retrieval is the prime disadvantage of these types of membranes. Exfoliation of graft membrane also

adds to disadvantage of non-resorbable membranes.

ePTFE membranes consists of polytetrafluoroethylene fibrils and nodes of varying sizes and this material is inert and has high tissue compatibility. Membrane has porous microstructure which allows the ingrowth of connective tissue and enhances wound clot stabilisation and inhibits epithelial migration (Fig.2). These membranes have an open microstructure collar in their coronal border enhancing clot stabilisation and stops epithelial apical migration. eg: Cytoplast membrane.

Titanium reinforced ePTFE membranes are a variant of ePTFE, which were designed to increase and maintain the tent forming capacity of membrane. These types of membranes are used in surgical augmentation procedures treating defects. Advantage of these types of membranes were they retain their functional characteristics for adequate healing to occur within the defect. Second surgical re-entry of the material is its primary disadvantage.

2. Resorbable membranes:

Surgical re-entry for membrane retrieval of non resorbable membrane lead to resorbable membrane usage. Copolymers of polylactic acid, polyglycoside and acetyl tributylcitrate and collagen membrane come under resorbable category of membranes. Material exposure, flap dehiscence, bacterial infiltration and membrane collapse are the disadvantages of resorbable membranes. Membranes have been widely studied in literature, along with flap surgery alone and in combination with grafts.

Collagen membranes:

Collagen is the main structural protein in various connective tissue. About one quarter of total protein content of body is collagen. Collagen has capacity to be cross linked and used in various forms such as films, gels, sheets etc¹⁴ eg: Healiguide membrane. Following are the properties of collagen which influences its use in surgery.

They are:

- (1) Prevents the dehydration of wounds
- (2) Promotes the development of granulation tissue

(3) Provides mechanical protection against physical and bacterial insult.

(4) Prevents tissue sloughing

(5) Has decreased immune response.

Researchers have reported that collagen powders exhibit excellent adhesion to the wound and provides the formation of a highly vascularized granulation bed. Hydrolyzed collagen in the form of films has been used as a tissue adhesive for suture replacement because of its chemical resemblance to connective tissue and its tissue fluid-binding properties.

Collagen has the ability of enhancing clot formation and stabilization, angiogenesis and epithelial cell rejuvenation thus acting as a natural hemostatic agent.¹⁴ Collagen also serves as a biologic scaffold for endothelial cells and progenitor cells from the periodontal ligament. Collagen-based membranes have been widely used in periodontal and implant therapy as barriers to prevent the migration of the epithelial cells and encourage wound repopulation by cells with regenerative potential. Type I collagen has been studied as a possible membrane barrier for use in guided tissue regeneration (GTR) procedures.

Formation of the fibrin clot is a critical event for new attachment formation. The use of a membrane stabilizes the wound and the membrane protects the root surface-adhering fibrin clot from tensile forces which act on the wound margins. It has been observed that collagen is chemotactic for fibroblasts. It also attracts fibroblasts to the area, and aid in the formation of new attachment and regeneration during GTR procedures. Collagen membranes are acted upon by collagenase enzymes and undergo resorption.¹⁴

Poly lactic acid membranes:

Composed of Polylactic acid treated with citric acid. Citric acid treatment increases its malleability and handling properties. Guidor was the first FDA approved polylactic acid membrane. Its configuration is designed in a way such that tooth and tissue surface has smaller circular perforations and space holders for new attachment and the outer surface has rectangular perforations to allow for gingival tissue in growth⁶. There is an interspace between the outer and inner layers of membranes. Membrane resorption completes approximately within 12 months.

Poly lactic acid and polygalactac acid membranes:

Composed of an occlusive film with fibre matrix bonded and randomly oriented on both surfaces of membrane (Fig.3). Polyglycoside membranes undergo non-enzymatic cleavage into polylactide and polyglycoside which inturn converts into lactic acid and pyruvic acid and enters the Krebs's cycle and is degraded within cells.¹⁰

Synthetic liquid polymer (Atrisorb):

It is a polymer combination lactic acid, poly (DL Lactide) and N-methyl-2-pyrrolidone which has a consistency of a solution and sets to a firm consistency on contact with water (Fig. 4). The membrane can be trimmed easily outside the oral cavity and adapted to the defect and sets to a firmer consistency and adheres to tooth structures.¹

Platelet Rich fibrin (PRF):

Platelet Rich Fibrin or PRF is second generation platelet concentrate developed by Choukroun et al. Advantage of using PRF is that the alpha granules of platelets are reservoirs of growth factors and aid in hard and soft tissue healing. PRF is autogenous and hence highly biocompatible and has decreased antigenicity (Fig. 5). PRF is a valid alternate for other commercial membranes.¹²

GTR applications is used in periodontal surgery to treat:

1. Furcation defects
2. Gingival recession
3. Infra bony defects

Guided tissue regeneration for gingival recession treatment:

Root coverage procedures pose a higher level of difficulty for regeneration as it targets the soft tissue coverage of exposed root surfaces and increasing gingival dimension. Healing of gingival root interface has found to be through long junctional epithelium, limited bone regeneration and variable levels of new attachments.¹³ Usage of GTR techniques with collagen and sub-epithelial connective tissue and coronally positioned flaps with titanium reinforced meshes have been studied. But statistically significant results have not been obtained predicting the better results of periodontal plastic surgical procedures.

Procedure for placement of membrane:

1. Elevation of full thickness flap and debridement. (Fig.6)
2. Compaction of graft material in defect(Fig. 7)
3. Placement of membrane (Fig. 8)
4. Adaptation and suturing of flap (Fig. 9)
5. Periodontal pack placement (Fig. 10)

Conclusion:

Regenerative periodontal therapy along with grafts and membranes have been shown to produce beneficial outcome. Modification of membranes with additive agents and surface treatments to enhance their mechanical properties show promising results for usage of barrier membranes with better scaffolding effect and space maintaining capacities.

References:

1. Jacob SA, Amudha D (2017) Guided Tissue Regeneration: A review, J Dent Health Oral Disord Ther 6(3): 00197.
2. Florjanski W et al, Modifications of polymeric membranes used in guided tissue and bone regeneration, Polymers 2019, 11, 782.
3. Melcher AH, On the repair potential of periodontal tissues, J Periodontol 1976;47(5): 256-60.
4. Gotlow J, Guided tissue regeneration using bioresorbable and non-resorbable devices; initial healingand long-term results. J Periodontol. 1993;64(11 Suppl): 1157-1165.
5. Nyman S, Gotlow J, Karring T, Lindhe J. The regeneration potential of periodontal ligament. An experimental study in monkey. J ClinPeriodontol 1982;9(3):257-265.
6. Wang HL, MacNeil RL, Guided Tissue Regeneration. Absorbable barriers. Dent ClinNorh Am.1998;42(3):505-522.
7. Aaboe M, Pinholt EM, Hjorting-Hansen E. Healing of experimentally createddefects: a review. Br J OralMaxillofac Surg. 1995; 33(5): 312-318.
8. Machtei EE, Dunford RG, Norderyd OM, Zambon JJ, GencoRJ. Guided tissue regeneration and anti-infective therapy in treatment of class II furcation defects. J Periodontol. 1993; 64(10):968-973.
9. Raja S, ByakodG, Pudukalkatti P. Growth factors in periodontal regeneration. Int J Dent Hyg.2009; 7(2):82-89.
10. Milella E, Barra G, Ramires PA, Leo G, Aversa P, Romito A. Poly (L-lactide)cid/ alginate composite membranes for guided tissue regeneration. J Biomed Mater Res. 2001;57(2):248-257.
11. Bottino MC, Thomas V, Janowski GM. A novel spatially designed and functionally graded electrospunmembraneforperiodontal regeneration. ActaBiomater. 2011; 7(1): 216-224.
12. Grassing V, Douglas T, Wamke PH, Acil Y, Wiltfang J, Becker ST. Platelet-rich fibrin membrane as scaffolds for periosteal tissue engineering. Clin Oral Implants Res.2010;21(5): 543-549.
13. Sallum et al, Experimental and clinical studies on regenerative potential therapy, Periodontol 2000,2019; 79: 22-55.
14. Silvipriya et al, Collagen: Animal sources and biomedical applications, J App PharmaSci 5(03); 2015; 123-127.
15. Sam G et al, Evolution of barrier membranes in periodontal regeneration –“ Are the third generation membranes really here?”, J Clin and Diag res, 2014, 8(12): 14-17.

Recurrent Case of Peripheral Ossifying Fibroma: Case Report with One Year Follow-Up

Seba Abraham¹, Arya Premnath², Arunima P.R.³, Reejamol Mohammed Kassim⁴

ABSTRACT

Localized gingival enlargements are often observed within the oral cavity and the appearance is alarming for the patient. These isolated enlargements occur as a result of host-environment interaction/response to stimuli. It is a great challenge for the dentist to differentiate isolated enlargements because they present similar clinical appearance in certain stages of development. Clinical differentiation is puzzling and a thorough microscopic examination is mandatory for a proper diagnosis. Peripheral ossifying fibroma (POF) is one of the slow growing localized gingival enlargements of the oral cavity with a female predilection. Incomplete removal of fragments during surgical excision increase the recurrence rate of this overgrowth. This case report present a recurrent case of peripheral ossifying fibroma which was previously surgically excised and recurred after a period of 2 weeks.

Key words: Peripheral ossifying fibroma, enlargement, calcification

Introduction

Localized gingival enlargements are one of the most frequently observed lesions in the oral cavity. Most of these lesions are reactive rather than neoplastic and is considered to be initiated by local irritants. These enlargements can adversely affect structural, functional and aesthetic harmony. The clinical appearance of these reactive lesions mimic each other. Hence differentiation of these enlargements is often puzzling to the dental clinician.

Peripheral ossifying fibroma (POF) is one of the slow growing localized gingival enlargements of the oral cavity and accounts for 9.6% of all gingival overgrowths.¹ With a female predilection, these overgrowth is more prevalent in anterior maxilla. Histopathological evidence of fibrocellular connective tissue with calcification and ossification is the characteristic feature of POF.² Incomplete removal of fragments during surgical excision increase the recurrence rate of this overgrowth. Recurrence of 16-20% have been put

forth.³ Various treatment modalities practiced include conventional surgical technique, electro surgery and/or lasers.

This case report highlight a recurrent case of POF in a female patient and its surgical management with 1 year follow up.

Case report

A 28 year old female patient reported to the Department of Periodontics with a growth on gingiva in relation to lower right front tooth region. The growth appeared six months back and gradually increased in size until the time of interview. Patient revealed a history of surgical excision twice, during an interval of one year. Although the growth was excised it was not send for biopsy. The patient had a contributing medical history of hyperthyroidism and was under medication since three years.

Clinical exploration revealed an overgrowth on the labial and lingual aspect of 42, 43 regions

¹Professor & Head, ² Postgraduate, ³ Professor, ⁴ Reader, Dept. of Peridontics, PMS College of Dental Science and Research, Vattappara, Thiruvananthapuram. Corresponding Author: Dr. Arya Premnath, Email: aryapremnath@gmail.com

of size 1x0.8cm and 0.7x0.8cm respectively (Fig 1). The growth was pedunculated, reddish pink, with well-defined borders and the texture was smooth. On palpation, the growth was moderately tender and moderately firm. It was non-pulsating and blanched on application of pressure. Radiographic examination revealed widening of periodontal ligament space with no underlying bony involvement (Fig 2). The clinical differential diagnoses for the growth were pyogenic granuloma, traumatic fibroma, peripheral giant cell granuloma, and peripheral ossifying fibroma. Based on the clinical and radiographic findings a provisional diagnosis of POF was made.

After obtaining medical clearance and routine blood investigation thorough scaling, root planning and polishing was done to eliminate the irritational factors. The patient was enrolled in a strict oral hygiene maintenance and was instructed to use 0.2% chlorhexidine mouthwash twice daily for two weeks. Patient was reevaluated after four weeks and no significant changes were recorded in its clinical appearance. Hence excisional biopsy was planned to determine the exact nature of the lesion. Both buccal and lingual enlargements were tied at the base and was excised using scalpel under LA (Fig 3). The growths were removed in a single piece and was send for histopathological examination.

Patient reported one month after surgical excision with an overgrowth in relation to same region (Fig 4). The growth started to re-appear two weeks after exci-

sion and gradually increased in size. Considering high rate of recurrence, excision and open flap debridement was planned. Flap was reflected in relation to 42-43. Granulation tissue was completely removed and thorough root planning was done in order to prevent recurrence (Fig 5). Review was done after two weeks and one year and no further recurrence was reported (Fig 6).

Histopathological findings

Histopathological examination revealed soft tissue section showing proliferating stratified squamous epithelium and associated connective tissue. The underlying connective tissue was cellular consisting of plump fibroblasts, vascular spaces, budding capillaries and diffuse mixed inflammatory cell infiltrate. Area of ulceration with fibrin and focal neutrophilic infiltration was seen. Basophilic cementum like calcifications, ossifications in small bony trabeculae and few multinucleated giant cells was also noted within the connective tissue (Fig 7). Histopathological examination was suggestive of POF.

Discussion

Ossifying fibroma (OF) are of two types, central ossifying fibroma and peripheral ossifying fibroma.⁴ POF is the third most common localized reactive lesion and the term POF was coined by Eversol and Robin in 1972.⁵ Higher incidence of POF is seen among females, due to hormonal changes.⁶ It may occur at any age with peak incidence b/w second

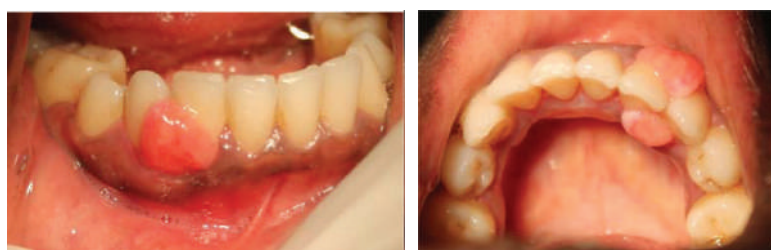

Fig 1: Clinical intraoral image of the growth between 42 and 43

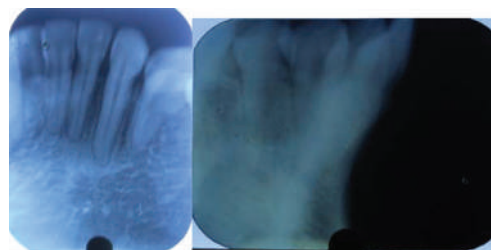


Fig 2a: IOPA showing periodontal ligament widening; 2b: IOPA showing no underlying bony involvement

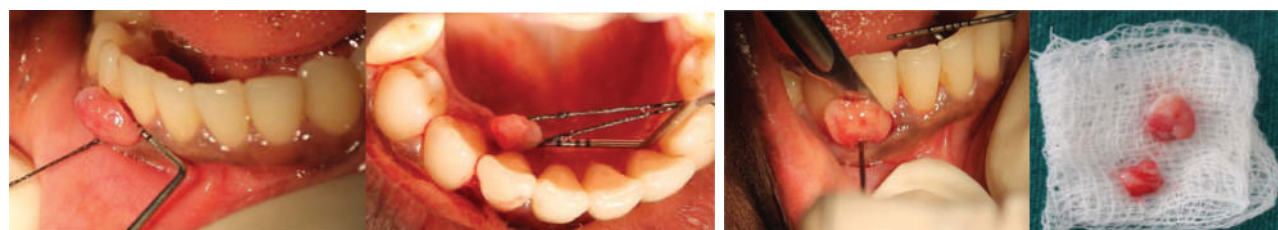


Fig 3: Surgical excision

and third decade. 760% of POF is reported to be in maxilla with 50% in anterior region, most commonly in the interdental papilla.⁸⁻¹¹ Although the present case is reported in female in the third decades of life, the lesion was associated with lower anteriors which is not in accordance with the literature findings. Regarding the etiology of POF two theories have been proposed. First theory states that POF starts as pyogenic granuloma and later during development it get calcified. According to the second theory, POF originate as inflammatory hyperplasia of PDL cells. Considering the proximity of PDL to gingiva and presence of oxytalan fibers within the mineralized matrix the second theory is more accepted.^{12,13}

Clinically POF present as a solitary, slow growing, nodular mass usually located in gingival papilla between adjacent teeth. It may be either pedunculated or sessile. These findings are consistent with the presented case. Eventhough majority of cases does not show underlying bone involvement, roentgenogram might present with well-defined borders and radiopaque zones.^{14,15} While early lesions shows more of radiolucent areas, mature lesions are commonly identified with radiopaque zones.^{14,16} Cases of superficial erosion of bone have also been reported occasionally.¹⁰ POF does not blanch on.¹⁷ However in the present case POF showed

blanching which may be due to its transition from PG.¹⁸ Although most cases of POF are reported to be less than 1.5cm, POF of larger sizes are also reported.¹⁹ In the present case the dimensions of the lesions were well within 1.5cm. Larger lesion may exert pressure on the adjacent teeth and may result in pathologic migration of the associated teeth.

Differential diagnosis of POF include traumatic fibroma (fibrous hyperplasia), peripheral giant cell granuloma (PGCG), pyogenic granuloma (PG) and peripheral odontogenic fibroma. Since clinically POF resemble other localized enlargements of gingiva a confirmatory diagnosis of POF is based on histopathologic examination.²⁰ Calcification, the most peculiar histopathological feature, differentiate POF from other fibrous proliferation.²¹ Table 1 shows difference between POF and other localized gingival enlargements. Early POF can be easily misdiagnosed as PG.²¹ Histopathologic examination of POF reveal presence of connective tissue with high cellularity and calcifications²² and is considered as the characteristic feature of POF. While dystrophic calcifications are usually seen in early, ulcerated lesions, older, mature, non-ulcerated lesions show well-formed bone and cementum-like material. The histopathologic findings as observed in this case shows presence of connective

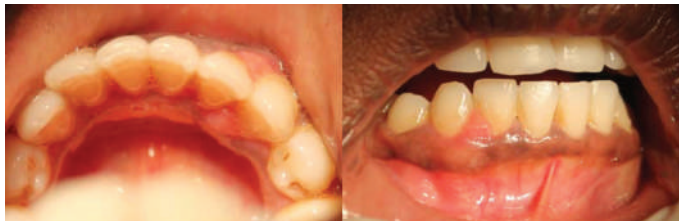

Fig 4: Intra-oral photograph showing recurrent growth 2 weeks after surgical excision

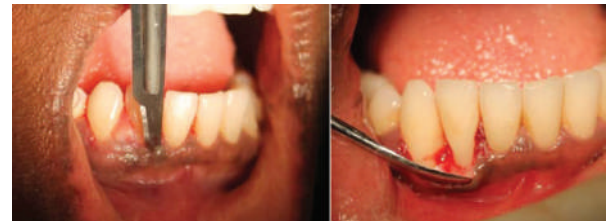

Fig 5: Flap reflection and debridement

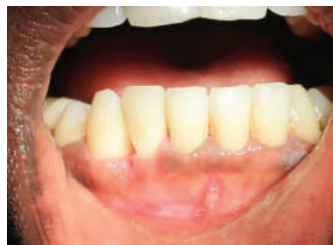

Fig 6a: Post-operative photograph after 2 weeks

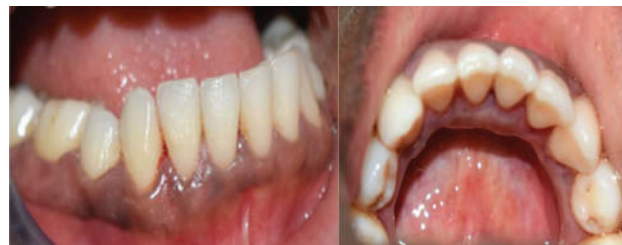

Fig 6 b: Post-operative photograph after 1 year

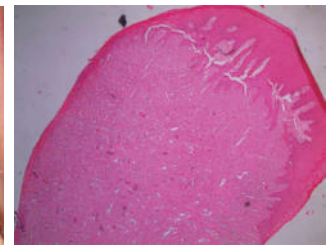


Fig 7: Photomicrograph of histopathological examination of the lesion showing cementum like calcifications and bony trabeculae within fibrocellular connective tissue stroma covered by stratified squamous epithelium.

tissue, cementum like calcification and ossifications. However in the present case giant cells were also seen which is unusual to find in POF. This observation supports the hypothesis that POF may be the more mature and late stage of the proliferative lesion.²³

Conventional surgical excision, electrocautery and laser assisted excision can be considered for the treatment of POF. Considering the high rate of recurrence of POF, these lesions must be thoroughly debrided and long term post-operative monitoring is required.²⁶ Removal down to the periosteum is the standardized treatment to prevent recurrence.²⁷ In the present case the overgrowth was previously surgically excised but showed recurrence, which may be due to incomplete removal of the growth. Hence total excision and open flap surgery was done to prevent recurrence.

Conclusion

Peripheral ossifying fibroma (POF) with high rate of recurrence is a non-neoplastic, slow growing enlargement of the gingiva. It is stimulated by local irritation and minor trauma. POF can be misdiagnosed with other localized lesions of the oral cavity. Hence careful radiographic and microscopic examination is necessary to differentiate it from other lesions. Treatment options include complete surgical excision down to the periosteum, and proper re-evaluation. Any remnants of lesion if present may result in recurrence.

Reference

1. J. D. Walters, J. K. Will, R. D. Hatfield, D. A. Cacchillo, and D. A. Raabe, "Excision and repair of the peripheral ossifying fibroma: a report of 3 cases," *Journal of Periodontology*, vol. 72, no. 7, pp. 939–944, 2001.
2. Neville BW, Damm DD, Allen CM, Bouquot JE. *Oral and Maxillofacial Pathology*. 2nd ed. Philadelphia: Saunders; 2002. Soft tissue tumors; pp. 451–452.
3. D. C. Shetty, A. B. Urs, P. Ahuja, A. Sahu, A. Manchanda, and Y. Sirohi. Mineralized components and their interpretation in the histogenesis of peripheral ossifying fibroma. *Indian Journal of Dental Research*, 2011; 22(1): 56–61.
4. Pal S, Hegde S, Ajil V. The varying clinical presentations of peripheral ossifying fibroma: A report of three cases. *Rev OdontoCienc* 2012; 27: 251–255.
5. Eversole LR, Rovin S. Reactive lesions of the gingiva. *J Oral Pathol* 1972; 1: 30–38.
6. Cundiff EJ. *Peripheral Ossifying Fibroma: A Review of 365 Cases*, MSD Thesis. USA: Indiana University; 1972.
7. Bodner L, Dayan D. Growth potential of peripheral ossifying fibroma. *J Clin Periodontol* 1987; 14: 551–554.
8. Neville BW, Damm DD, Allen CM, Bouquot JE. *Oral and Maxillofacial Pathology*. Philadelphia: W.B. Saunders; 1995.
9. Reactive lesions of the gingiva. A clinicopathological study of 741 cases. Kfir Y, Buchner A, Hansen LSJ *Periodontol*. 1980 Nov; 51(11): 655–661.
10. Managing a peripheral ossifying fibroma. Kendrick F, Waggoner WFASDC *J Dent Child*. 1996 Mar-Apr; 63(2): 135–138.
11. Peripheral ossifying fibroma associated with a neonatal tooth: case report. Kohli K, Christian A, Howell RP *Pediatr Dent*. 1998 Nov-Dec; 20(7): 428–429.
12. L. R. Eversole and S. Rovin. Reactive lesions of the gingiva. *Journal of oral pathology*, 1972; 1(1): 30–38.
13. C. S. Miller, R. G. Henry, and D. D. Damm. Proliferative mass found in the gingiva. *The Journal of the American Dental Association*, 1990; 121(4): 559–560.
14. Sacks HG, Amrani S, Anderson K (2012) BGigantiform peripheral ossifying fibroma: report of a case. *J Oral Maxillofac Surg* 70(11): 2610–2613.
15. Perez-Alvarez D, G.-SM, Bernini A, Gay-Escoda C. Fibroma osificante periférico: presentación de tres casos y revisión de la literatura. *Avances en Odontostomatología* 2011; 27: 183–188.
16. Sudhakar S, P.K.B., Prabhat MPV, Peripheral ossifying fibroma. *Online J Health Allied Scs*, 2009. 8(3): 17.
17. Sujatha G, Sivakumar G, Muruganandhan J, Selvakumar J, and Ramasamy M. Peripheral ossifying fibroma-report of a case. *Indian Journal of Multidisciplinary Dentistry* 2012; 2(1): 415–418.
18. Prasad S, Reddy SB, Patil SR, Kalburgi NB, Puranik RS. Peripheral ossifying fibroma and pyogenic granuloma. Are they interrelated? *NY State Dent J* 2008; 74(2): 50–52.
19. Cuisa ZE, Brannon RB. Peripheral ossifying fibroma: A clinical evaluation of 134 pediatric cases. *Pediatr Dent* 2001; 23: 245–248.
20. Farquhar T, Maclellan J, Dymont H, Anderson RD. Peripheral ossifying fibroma; a case report. *J Can Dent Assoc*. 2008 Nov; 74(9): 809–812.
21. Gaikwad, P; Sharma, M; Arun, S. & Anuj, G. Peripheral ossifying fibroma-A case report. *Medico-Legal Update*, 12(1): 4–5, 2012.
22. Buchner A, Hansen LS. The histomorphologic spectrum of peripheral ossifying fibroma. *Oral Surg Oral Med Oral Pathol* 1987; 63: 452–461.
23. Dereci O, Akgun S, Celasun B, Ozturk A, Gunhan O. Histological evaluation of the possible transformation of peripheral giant cell granuloma and peripheral ossifying fibroma: a preliminary study. *Indian J Pathol Microbiol*. 2017; 60(1): 15–20.
24. Kerr AR, Phelan JA. Benign lesions of the oral cavity. In: Greenberg MS, Glick M, Ship JA, editors. *Burket's oral medicine*. 11th ed. Hamilton: BC Decker Inc.; 2008. p. 133–134.
25. Zarei MR, Chamani G, Amanpoor S. Reactive hyperplasia of the oral cavity in Kerman province, Iran: A review of 172 cases. *Br J Oral Maxillofac Surg*. 2007; 45: 288–292.
26. S. N. Bhaskar and J. R. Jacoway, "Peripheral fibroma and peripheral fibroma with calcification: report of 376 cases," *The Journal of the American Dental Association*, 1996; 73(6): 1312–1320.
27. Neville BW, Damm DD, Allen CM, Chi AC. *Oral and maxillofacial pathology* 4th ed. Philadelphia: Elsevier; 2016; pp. 678, 483.

Gingival enlargement – An initial manifestation in a case of a T-lymphoblastic lymphoma leukemia

Vangala Preeti¹, Ramiseti Arpita², Muthineni Ramesh Babu³, Sravani CH⁴

ABSTRACT

Lymphoblastic lymphoma leukemia (LBL) is an uncommon malignancy accounting for <2% of non-Hodgkin's lymphoma (NHL). Characteristic clinical presentation of Lymphoblastic lymphoma-leukemia (LBL) includes mediastinal masses (50-75%), pleural and pericardial effusion, and lymphadenopathy in the neck, axilla or supraclavicular regions. We present a rare case report of LBL in a twenty year-old boy with initial oral manifestation, presenting with unusual huge enlargement of the gingiva of maxilla, mandible and soft palate which led to secondary respiratory and feeding difficulties. Histomorphometric, flowcytometric and immunohistochemistry evaluation of bone marrow aspiration showed that it was a T cell lymphoblastic lymphoma and considered as a case of lymphoma-leukemia. After appropriate treatment, the symptoms of the patient relieved significantly and he is in complete remission of gingival hypertrophy.

Key words: gingival enlargement, non-hodgkin's lymphoma, T cell lymphoblastic lymphoma

Introduction

Lymphoma is the most common blood cancer. The two main forms of lymphoma are Hodgkin lymphoma (HL) and non-Hodgkin lymphoma (NHL). Lymphoma occurs when cells of the immune system called lymphocytes, a type of white blood cell, grow and multiply uncontrollably. Cancerous lymphocytes can travel to many parts of the body, including the lymph nodes, spleen, bone marrow, blood, or other organs, and form a mass called a tumor. The body has two main types of lymphocytes that can develop into lymphomas: B-lymphocytes (B-cells) and T-lymphocytes (T-cells). T-cell lymphomas account for approximately 15 percent of all NHLs in the United States.¹ T-cell acute lymphoblastic leukemia (T-ALL) and T-cell lymphoblastic lymphoma (T-LBL) are neoplasias of immature T-cell precursors considered as a unique biological entity in the 2008 World Health Organization Classification of Hematologic Neoplasias.²

In adults T-LL is an infrequent type of non-Hodgkin's lymphoma (NHL), representing about 2% of cases and having a bimodal incidence, with higher frequencies in patients less than 20 years and in those aged more than 50 years. Clinical and biologic features of T-LBL such as male predominance, high incidence of mediastinal tumor, and other lymphomatous manifestations are similar to those of T-ALL and different from B-LBL. T-ALL and T-LBL are separated by an arbitrary margin of 25% bone marrow involvement; patients with higher degree of bone marrow infiltration are generally classified as T-ALL.^{3,4,5} A mediastinal involvement, which is a typical characteristic of T-LBL, was evident in 89% of the patients, and was often (40%) associated with pleural and/or pericardial effusion. Peripheral blood and bone marrow involvement are seen in at least one-third of patients with either T cell or B cell precursor LBL and sometimes during the clinical courses among 80% of those who die from the disease.⁶ Other well established sites of

¹Associate Professor, ²Professor & Head, ³Professor, Department of Periodontics, Mamata Dental College, Khammam, ⁴Private Practitioner, Khammam, Telangana State, India. Corresponding Author: Dr. Ramiseti Arpita, Email: arpita_paul@hotmail.com

involvement include kidney, lung, ovary, testes, liver, spleen and eye.⁷

Although involvement of jaw, maxilla and mandible is a well know finding in B cell type of non-Hodgkin lymphoma and LBLL, only 4 documented cases were noticed in T cell type LBLL.⁸⁻¹⁰

Case report

A 19 year old boy presented with painless huge enlargement of the gums of maxilla and mandible with gradual increase in size over two months, with history of difficulty in swallowing and respiration. On examination the person was moderately built and well-nourished with diffuse gingival enlargement of the both jaws (Fig. 1). OPG findings were normal (Fig 2). His hematological examination reports were with the normal limits. Incisional biopsy of the gingiva showed diffuse infiltration of lymphoid cells which were monotonous and arranged in lobules (Fig 3). They were punctuated by few histiocytes. Several other tests were advised for the patient.

Pulmonary function tests were advised as the patient gave a history of dyspnoea and the results

showed severe respiratory obstruction. Linear core biopsy of mediastinal mass showed dense infiltration by monomorphous round cells with scanty cytoplasm and round to oval dark nuclei. Ultrasonography of abdomen showed solitary nodule in left lobe of thyroid and pleural effusion on left side. Imageology studies of chest shown large lobulated enhancing homogenous mass on anterior mediastinum (Fig 4) encircling and displacing major vessels on mediastinum encircling the cardia with pericardial and left pleural effusion. Fine needle aspiration cytology (FNAC) of left anterior mediastinal lymph node showed medium sized lymphocytes with notched nuclei and moderate cytoplasm suggesting neoplastic lesion. CT scan of the chest showed large heterogenously enhancing soft tissue density mass involving anterior mediastinum. Moderate left pleural effusion & passive atelectasis of lower lobe and areas of nodular pleural thickening(Fig 5).

With the clinical findings strengthened by the investigations done, a final diagnosis of T-Lymphoblastic lymphoma was made. Intra orally, the case was diagnosed to have Neoplastic Gingival Enlargement associated with T-Lymphoblastic lymphoma. Accord-

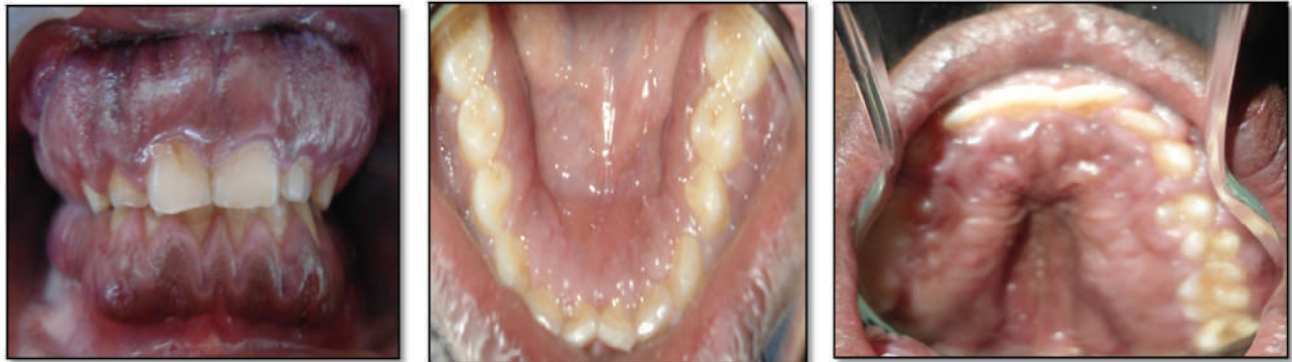

Fig 1a,b,c: Diffuse gingival enlargement of the maxilla and mandible

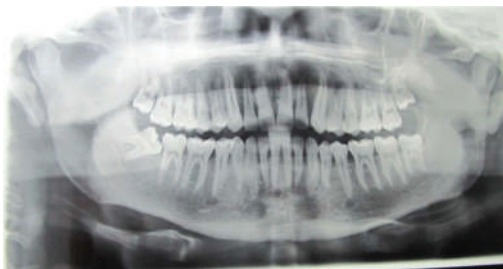

Fig 2: OPG

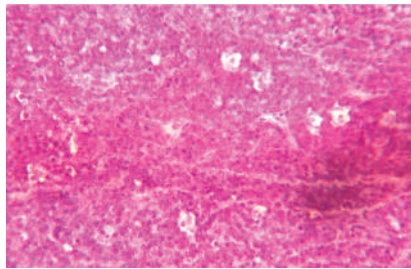


Fig 3: Incisional biopsy of the gingiva with monotonous diffuse infiltration of lymphoid cells arranged in lobules

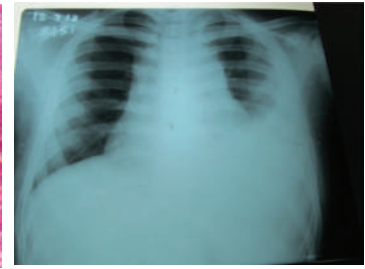


Fig 4: Imageology of chest shown large lobulated enhancing homogenous mass on anterior mediastinum

ingly, treatment of patient was begun by chemotherapy and the chief complaint of the patient was regressed after 1 month (Fig 6a-c). Now he is in complete remission of gingival enlargement and he is undergoing chemotherapy. The patient has been kept on a periodic recall to assess the periodontal status in the follow up period of the patient's recovery.

Discussion

We report a rare case of T-Lymphoblastic Lymphoma with predominant involvement of the gingiva of maxilla, mandible on labial, buccal, palatal and lingual surfaces. To the best of our knowledge, this is only the fifth such case to be reported in the world literature.

T-LBL is a high-grade neoplasm arising from precursor T lymphocytes affecting adolescents and young adults, with small to medium sized blasts with irregular nuclear contour, coarse chromatin and inconspicuous

nucleoli, presents with a mediastinal mass in 50% of cases; other well established sites of involvement include the lymph nodes, skin, bone, nasopharynx, gonads, liver and spleen.¹¹ Karimi and Eshghi from Iran reported a case of T cell lymphoblastic leukemia/lymphoma in a six-year-old child with huge enlargement of the maxilla and mandible.¹⁰ Wolvius et al reported a case of T-cell ALL in an 18-month-old child with initial oral presentation.⁷ Yin et al., in a study of 34 cases of primary non-Hodgkin lymphomas of the oral cavity, found 27 cases of B-cell lymphoma, 3 cases of T-cell lymphoma and 4 cases of NK/T-cell lymphoma.¹² Results emerging from the investigations of homing receptors and adhesion molecules on T lymphocytes will help us understand the re circulating pathways of malignant T-cells to lymphoid organs and extra nodal sites.¹³ In a study of 40 cases of primary non-Hodgkin lymphomas of the oral cavity by van der Waal et al. all cases were of the B cell type.¹⁴ According to a large

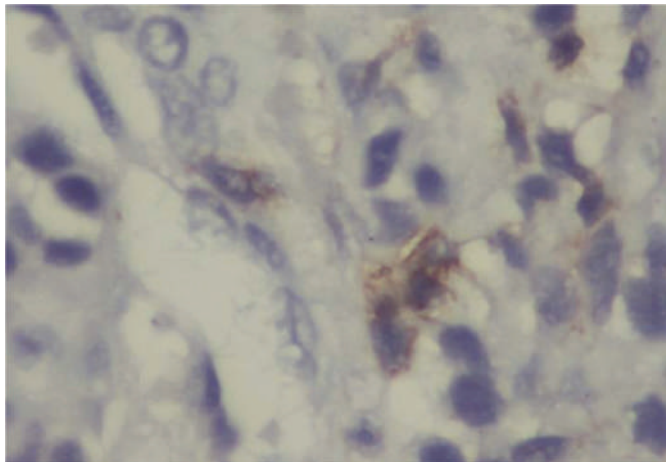


Fig 5:FNAC of left anterior mediastinal lymph node showed medium sized lymphocytes with notched nuclei and moderate cytoplasm suggesting neoplastic lesion

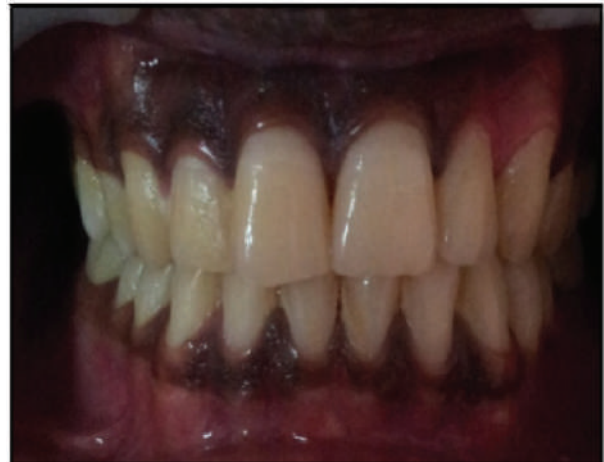

Fig 6a

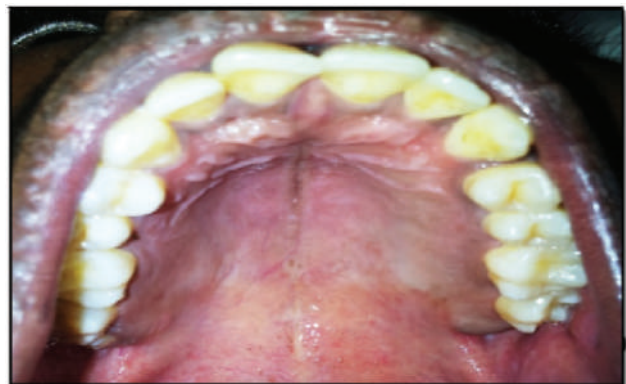
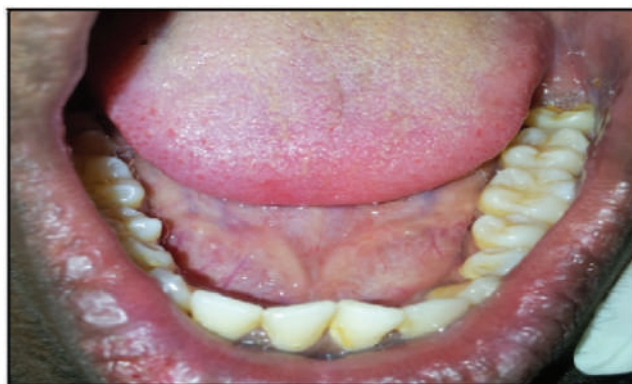
Fig 6 a, b & c: Complete remission of gingival enlargement after medical treatment of T-Lymphoblastic lymphoma with chemotherapy

study by Epstein et al., lymphomas form the most frequent non epithelial malignancies in the oral cavity and maxillofacial region, the majority of them arising from B lymphocytes.¹⁵ Oliver et al., reported the case of a two-year-old child with Down's syndrome with jaw involvement showing Burkitt-like cytomorphological features, but immunophenotypically they were of the T-cell type.⁹ Premalata et al., reported a case of precursor T-ALL involving huge enlargement of gum, palate and upper jaw.¹⁶ In the present case a diagnosis of T-Lymphoblastic lymphoma was made based on the findings from gingival and linear core biopsy of mediastinal mass. Imageology studies showed pleural effusion and anterior mediastinal mass. These findings were further confirmed by Ultrasonography, fine needle aspiration cytology and CT scan of chest.

Conclusion

Oral lesions (gingiva) are one of the earlier manifestations of leukemias and may serve as diagnostic indicator of the disease. Though rare, T-LBL should be included in the differential diagnosis of lymphomas and leukemias infiltrating the oral cavity and gums, as these neoplasms show excellent response to the current chemotherapeutic regimens. Periodontal management in cases of gingival enlargement should be preceded by a thorough history and comprehensive investigation and should be done in conjunction with the medical management of the underlying etiology.

References

1. <http://www.lymphoma.org/site/pp.asp?c=bkLTkaOQLmK8E&b=6300161>
2. Borowitz MJ, Chan JK. T lymphoblastic leukemia/lymphoma. En: Swerdlow SH, Campo E, Harris NL, Jaffe ES, Pileri S, Stein M, Thiele J, Vardiman JW, eds. WHO classification of the tumors of the hematopoietic and lymphoid tissues. Lyon IARC; 2008; 176-178.
3. Weiss LM, Bindl JM, Picozzi VJ et al. Lymphoblastic lymphoma, an immunological phenotypes of 26 cases with comparison to T cell acute lymphoblastic leukemia. *Blood* 1986; 67: 474.
4. Nathwani BN, Kim H, Rappaport H. Malignant lymphoma, lymphoblastic. *Cancer* 1986; 38: 964.
5. Rosenberg SA, Berard CW, Brown BW et al. National cancer Institute sponsored study of classification of Non-Hodgkins lymphoma: summary and description of a working formulation for clinical usage. *Cancer* 1982; 49: 2112.
6. Medeiros LJ. Intermediate and high grade lymphoma in the working formulation. In: Jaffe ES, ed. *Surgical pathology of lymph nodes and related organs, major problem in pathology series*. Vol. 16, 2nd Ed. Philadelphia, WB Saunders Co., 1994; 283.
7. Wolvius EB, Van der Valk P, Baart JA et al. T cell lymphoblastic lymphoma of the lower jaw in a young child: a case report. *Oral Surg Oral Med Oral Path Oral Radiol Endod* 1996;82:434-436.
8. Scully C, Eveson JW, Witherow H, Young AH, Ton RS, Gilbey ED. Oral presentation of lymphoma. *Eur J Cancer B Oral Oncol* 1993; 29: 225-229.
9. Oliver JD, Grogan TM, Pany CM, Spier C, Richter LC, Rangel CS. Burkitts-like lymphoma of T cell type. *Mod Pathol* 1998; 1: 15-22.
10. M. Karimi and P. Eshghi.. Unusual Lymphoblastic Leukemia/ Lymphoma in Eastern Iran. *Indian J Pediatr* 2006; 73 (7): 619-622.
11. Magrath IT. Malignant non Hodgkin's lymphomas in children. In: Pizzo PA, Poplack DP, editors. *Principles and Practices of Pediatric Oncology*. 4th ed. Philadelphia: Lippincott, 2002:661-705.
12. Yin HF, Jamlukhanova V, Okada N, Takaqi M. Primary natural killer/T cell lymphomas of the oral cavity are aggressive neoplasms. *Virchows Arch* 1999;435:400-406.
13. Pals ST, de Gorter DJ, Spaargaren M. Lymphoma dissemination: the other face of lymphocyte homing. *Blood* 2007;110:3102-11.
14. van der Waal RI, Huijgens PC, van der Valk P, van der Waal I. Characteristics of 40 primary extranodal non-Hodgkin lymphomas of the oral cavity in perspective of the new WHO classification and the International Prognostic Index. *Int J Oral Maxillofac Surg* 2005;34:391-395.
15. Epstein JB, Epstein JD, Le ND, Gorsky M. Characteristics of oral and paraoral malignant lymphoma: a population-based study of 361 cases. *Oral Surg Oral Med Oral Pathol Oral Radiol Endod* 2001;92:519-525.
16. Chennagiri Srinivasamurthy Premalata, Davanam Satyanarayana Madhumathi1, Visweswraiah Lakshmidivi, Rudramurthy Pradeep, Lingappa Appaji, Geetashree Mukherjee. Gum hypertrophy - an unusual presenting feature in a case of precursor T-cell acute lymphoblastic leukemia. (*Turk J Hematol* 2008; 25: 201-204.

The esthetic smile rehabilitation: An interdisciplinary concept, a case report

Anu Chandran¹, Amitha Ramesh², Rahul Bhandary³, BijuThomas⁴

ABSTRACT

Character of smile influences to a great extent the attractiveness and the personality of the individual. Beautiful and attractive smile involves a multidisciplinary approach that includes change of both morphological aspect of teeth and architecture of gum tissues. In today's world the demand for esthetics has increased dramatically, so an organized and systemic approach is required to resolve esthetic problems predictably. This article highlights on the case report of smile designing in a patient with anterior spacing, by an interdisciplinary concept to recreate the natural aspect of teeth in combination with the harmonic architecture of soft tissue in order to achieve a pleasing composition in the smile.

Keywords: crown lengthening, esthetics, interdisciplinary, gingivectomy

Introduction

Smile design refers to the scientific and artistic principles that inclusively can create a graceful smile. It requires an integration of esthetic concepts that harmonize facial esthetics with the dental facial composition (lips) and the dental composition (The teeth and gingival scaffold). The lips form the frame of a smile and define the esthetic zone. The lip position during smiling determines the amount of gingival display.¹ A multidisciplinary approach is vital to achieve the planned result.

First and foremost, presence of healthy gingiva is an essential criteria for esthetic success. Proper gingival architecture is a crucial complementary element. As an analogy, the gingiva is similar to a frame enclosing beautiful painting. The frame complements the painting's beauty but can detract from it, if unsightly.

Esthetic crown lengthening not only improve normal tooth height and tooth proportions, it is also helpful in creating symmetry, positive radicular architecture, and proper zenith points of the gingival margins to produce a more pleasing emergence profile.³

One significant feature of gingival morphology is the gingival line, which is defined as a line joining the tangents of the gingival zeniths of the central incisor and canine. The gingival zenith is the most apical aspect of the free gingival margin. Another most important features of a pleasing smile is the smile line, which is an imaginary line drawn along the incisal edges of the maxillary anterior teeth. Ideally the line coincides or follows the curvature of the lower lip while smiling.³

Thus an ideal esthetic treatment plan should be minimally invasive, preserving as much of natural structures as possible, realign the ideal form and function of the teeth and tissues, enhancing the esthetics without compromising the patients oral health.^{3,4}

Conservative treatments that are the solution to aesthetic problems involving morphologic modifications and provide the result that the patient expects should be the first therapeutic option. Ceramic laminate veneers, also known as "contact lens," are capable of providing an extremely faithful reproduction of the natural teeth with great color stability and periodontal biocompatibility.⁵

¹Post Graduate Student, ^{2,3}Professor, ⁴Professor & Head, Department of Periodontics, A.B. Shetty Memorial Institute of Dental Sciences, Delrakatta, Karnataka. Corresponding author: Dr. Anu Chandran, E-mail: dr.anuchandran@gmail.com

Case report

A 17 years old systemically healthy male patient was reported to the department of periodontics, AB Shetty Memorial Institute of Dental Sciences; Mangalore with the chief complaint of spacing in the maxillary anterior region (Fig 1a &b). He was very motivated and keen to improve his smile. The patient had no other medical contraindication or allergies. Patient had undergone orthodontic treatment for one year for the same but complete closure of spacing was not achieved. Thorough oral prophylaxis and oral hygiene instruction was reinforced to ensure proper maintenance following the therapy. After obtaining the patient consent, it was decided to treat the spacing of maxillary anterior region by aesthetic crown lengthening followed by fixed prosthesis. Planning is a crucial step in successful aesthetic rehabilitation treatment.

Planning each clinical case using a photographic protocol provides better predictability in the final outcome. Photos, wax-up/mock-up help to establish correct values and to ensure the symmetry and proportion to the new smile.

Pre operative photographs and diagnostic wax up (Fig 3) was done prior to surgical intervention to estimate the amount of gingival reduction needed. The diagnostic wax mock-up allows for individualized planning and predictable outcome in cases where a certain shape and position are expected. There is often a need for prior corrections of the contours and the gingival anatomy due to the goals of achieving facial aesthetics and ensuring harmony between the gum tissue and the dental anatomy.

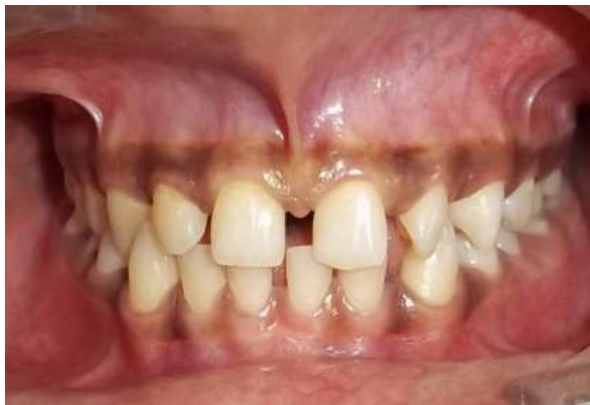

Fig 1a

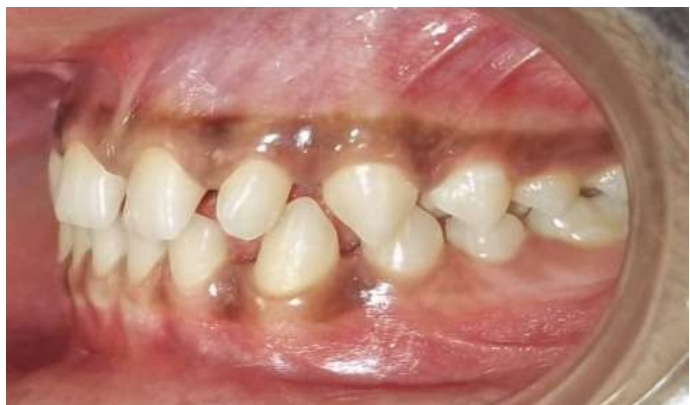

Fig 1b

Fig 1: Pre operative photographs: Frontal view (Fig 1a) and Sagittal view (Fig 1b) showing class I malocclusion with generalized spacing of teeth.

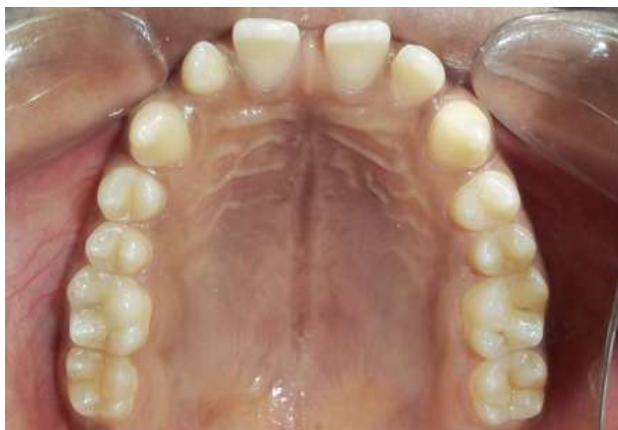

Fig 2a

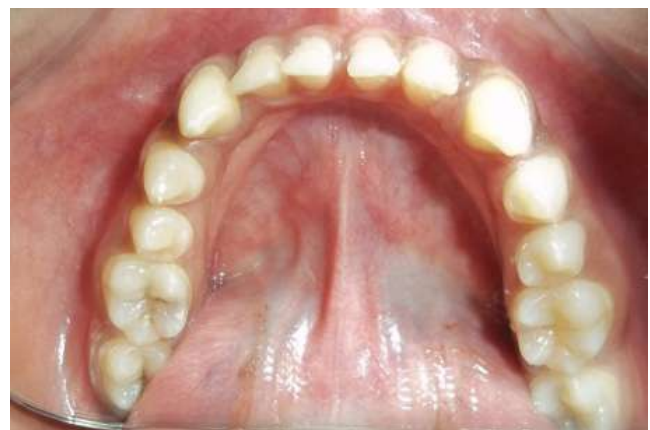

Fig 2b

Fig (2a,b): Occlusal view showing spaces between maxillary and mandibular central incisors, and between lateral incisors and canines.

Surgical procedure

Upon periodontal examination, adequate keratinized gingiva was present and bone sounding was done in order to maintain the biological width, type I aesthetic crown lengthening surgery was indicated according to the classification by Lee EA (2004),⁶ where osseous reduction was not required. When therapy involves crown lengthening, assessment of both the biologic width and periodontal biotypes/phenotypes is essential. This case was of thin tissue phenotype. Anatomical restorative contours, with no impingement on the biologic width, are critical for tissue health and will therefore contribute to the long-term aesthetics of the gingiva. If the gingival recontouring and subsequent placement of the restorative margin encroaches on the biological width, the result will be a chronic marginal gingivitis. In the case of the restorative margin, there must be a minimum of 3.0 mm of space between the margin and the crestal bone. There must be a minimum of 2.0 mm of attached gingival tissue overlying the bone or else pressure sensitivity may occur.⁷

The surgical area was anesthetized with 2% lignocaine HCl containing 1:80,000 adrenaline solutions. After bone sounding bleeding points was established

and esthetic crown lengthening was done using electrocautery from canine to canine in the maxillary arch. The main advantage of the electrocautery (Fig 4) is coagulative effect that provides bloodless area and clear view of the operative field.

Establishing the correct gingival levels for each individual tooth is the key in the creation of harmonious smile. External bevel gingivectomy (Fig 5) was performed to achieve 1mm reduction in 11, 12&21. Reduction of 2mm was done irt 13 &23, as symmetry is a significant esthetic attribute and also applies to the gingival line; it necessitates the presence of identical tissue levels between contralateral teeth. The gingival margins of the maxillary central incisors and the canines should be symmetric and more apical to the lateral incisors.²

Certain factors to be considered in aesthetic crown lengthening are

- The cervical gingival height (position or level) of the centrals should be symmetrical. It can also match that of the canines. The gingival margin of the lateral incisor is 0.5–2.0 mm below that of the central incisors.⁴ Balance and symmetry are



Fig 3: Diagnostic mock up

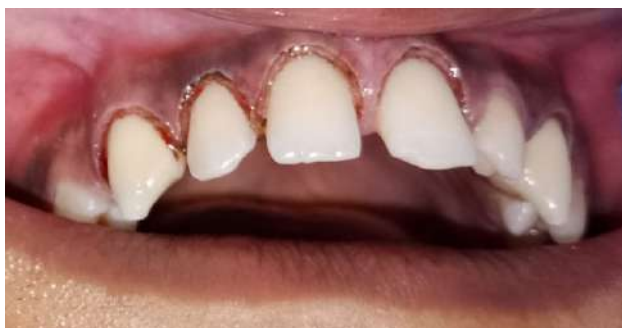

Fig 5: Esthetic crown lengthening in maxillary anterior region



Fig 4: Electrocautery

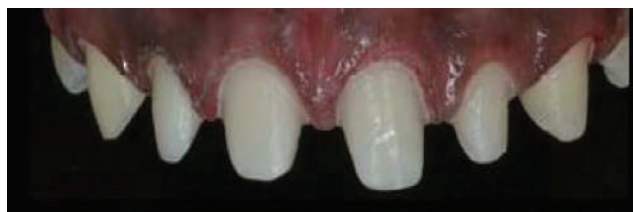

Fig 6a

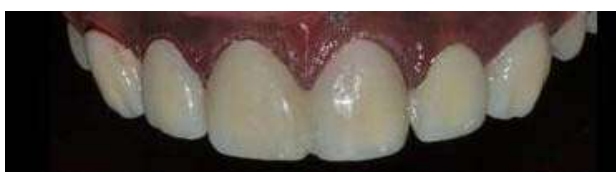

Fig 6b: Final cementation of ceramic veneers

essential parts of what marks an attractive smile.

- Central dominance dictates that the centrals must be the dominant teeth in the smile and they must display pleasing proportions. They are the key to the smile and hence the proportions of the centrals must be esthetically and mathematically correct. The width to length ratio of the centrals should be approximately 4:5 (0.8–1.0). Maxillary canine is of importance, in creating a pleasing smile as they are the junction between the anterior and posterior dental segments and hence, only the mesial half of the canine is visible from the frontal view when the patient smiles.
- The gingival zenith is a component of the gingival line and refers to the most apical point of the gingival tissue on the buccal aspect of the clinical crown. It extends an average of 1 mm distal to the axial inclination of the maxillary incisors and 0.5 mm on lateral incisors. The zenith of the maxillary canines usually coincides with the vertical axis of the tooth. In the vertical dimension, the zenith of the lateral incisors is found approximately 1 mm coronal to the adjacent central incisors and canines.² The position of the zenith will help create the desired axial inclination of the tooth by changing the line angle position of the long axis of the tooth

Thus achieving gingival harmony can be achieved by pleasing combination of all the different elements mentioned.

Fixed prosthesis

The next step was crown preparation, which was completed using a conventional high speed hand piece. The preparation phase should be minimally invasive, providing just enough space for the ceramic restorations. The mock-up was used as a guide for the minimally invasive prosthetic preparation (Fig 6a, b). Temporary prosthesis was given and the patient was scheduled to return in 2 weeks for final prosthesis.

Six ceramic veneers (lithium disilicate (IPS e.max Press, Ivoclar Vivadent). were planned (from canine to canine) in the maxillary anterior region. Shade selection was done using A1 Vita shade guide.

To prevent crack inside the veneers,

- The ceramic veneer thickness should be at least three times that of the luting composite material (ceramic/ composite ratio of thickness > 3) at the facial location.
- It is also important to obtain a good internal fit of the restoration (approximately 100 μ m).⁸

At final insertion appointment, the tissues appeared healthy. The cementation of the ceramic laminates is the last step in the work; it should be done with extreme caution. It is important to remember that, unlike conventional crowns, which use dual-type resin cements, ceramic laminates should use a purely light-cured luting agent to prevent the color shifts that can occur due to chemical changes in the curing process.

Laminate veneers were as an excellent option for effective, conservative, and aesthetic treatment. As a result, the aesthetics and function expected by the patients were achieved. The patient was extremely satisfied with the result. Psychological improvements were also seen, as there was an increase in the patient's self-confidence. The functional and esthetic improvement can be appreciated by comparing the before and after treatment photographs.

Discussion

The significant feature of smile design is the health, symmetry, and architecture of the gingival tissues. The gingiva acts as the frame for the teeth and is of cardinal importance that the gingival tissues should be in complete state of health prior to the initiation of any treatment.⁴ Gingival harmony is an important criteria in the esthetics of the smile. The majority of patients exhibit some amount gingiva in a smile. Excessive gingival display can lead to patient dissatisfaction. Kokich et al. demonstrated that gingival display of more than 4 mm in a smile is considered unesthetic by lay people.²

Careful attention to the biological and iatrogenic factors which greatly influence the health and appearance of the gingival tissues is necessary to maintain the integrity of the tissue⁷. Hence it is apparent that gingival esthetics is rather complex and depends on a multitude of elements. Aesthetic rehabilitation with ceramic laminates is being used as a way to preserve tooth structure. The use of ceramic veneers resulted in

a highly predictable and professionally gratifying restoration. It is considered one of the most conservative treatments for oral rehabilitation, as it requires minimal or no tooth preparation. The smile designing done has to be as conservative as possible by less reduction of tooth structure and greater esthetics and durability.

Conclusion

Esthetic crown lengthening provides adequate retention form for tooth preparation and for esthetically pleasing, healthy restoration. But for a long term success rate of restoration and prosthesis it is very crucial to maintain the biological width. This case history signifies the importance of periodontist and restorative dentist. Thus the interdisciplinary approach is the promising way to achieve high prognostic value of treatment.

Reference

1. Charruel S, Perez C, Foti B, Camps J, Monnet C, Corti V. Gingival contour assessment: clinical parameters useful for esthetic diagnosis and treatment. *Journal of Periodontology*. 2008 May;79(5):795-801.
2. Simon Z, Rosenblatt A. Challenges in achieving gingival harmony. *Journal of the California Dental Association*. 2010 Aug;38(8):583-590.
3. Davis NC. Smile design. *Dental Clinics of North America*. 2007 Apr 1;51(2):299-318.
4. Bhuvaneswaran M. Principles of smile design. *Journal of conservative dentistry*: 2010 Oct;13(4):225.
5. Morita RK, Hayashida MF, Pupo YM, Berger G, Reggiani RD, Betiol EA. Minimally Invasive Laminate Veneers: Clinical Aspects in Treatment Planning and Cementation Procedures. *Case reports in dentistry*. 2016;2016.
6. Lee EA. Aesthetic crown lengthening: classification, biologic rationale, and treatment planning considerations. *PractProcedAesthet Dent* 2004;16(10):769-78.
7. Goodlin R. COSMETIC DENTISTRY-Gingival Aesthetics--A Critical Factor in Smile Design. *Oral Health*. 2003;93(4):10-28.
8. Veneziani M. Ceramic laminate veneers: clinical procedures with a multidisciplinary approach. *The international journal of esthetic dentistry*. 2017 Dec 1;12(4):426-448.